

PATIENT PRESENTING CLINICAL SIGNS

Gracie Walter Presented for evaluation of rupture CCL. Survey radiographs included abdomen and chest. Investigation of spleen and abdomen wanted.

SPECIES

Canine Abnormal PE/Chem/CBC/UA Results: ABNORMAL Laboratory Findings Cardiac disease noted. Brief ultrasound abnormal caudal spleen noted Current Medications Gabapentin 100mg, carprofen 75mg, miconazole, furosemide 40mg, vetmedin 5mg.

BREED

Labrador X

SEX

Spayed Female

AGE

5 yrs

WEIGHT

72 lbs

INTERPRETED BY

R. McKenzie Daniel,
DVM, DABVP (Canine
and Feline)

IMAGING PERFORMED BY

Sara Hansen

HOSPITAL NAME

Forest Valley
Veterinary Clinic

REFERRING VET

Dr. Walltz

INVOICE

10332

DATE

7/17/2023

ULTRASONOGRAPHIC EXAMINATION OF THE ABDOMEN

Urinary System

The urinary bladder, trigone, cystourethral junction, and visible pelvic urethra to a depth of 4 cm exhibited normal thickness and tone. Anechoic urine was present in the lumen with no uroliths or sediment. The ureteral papillae were normal. The ureters were not visible which is normal. No evidence of inflammatory or neoplastic changes was noted.

The area of the aortic trifurcation was free of pathology.

Normal size and margination were present in the kidneys. A normal 1:3 cortex / medulla ratio and normal corticomedullary definition were maintained. The echogenicity of the cortex was similar to or slightly less than normal liver parenchyma while the medulla echogenicity was hypoechoic to the cortex with no evidence of pelvic dilation. The left kidney measured 6.3 cm in length. The right kidney measured 6.9 cm in length.

Adrenal Glands

The left adrenal gland was uniform in size and contour with a uniformly hypoechoic parenchyma. The left adrenal gland measured 2.3 cm in length x 0.54 cm in width at the caudal pole. The area of the right adrenal gland was free of pathology.

Spleen

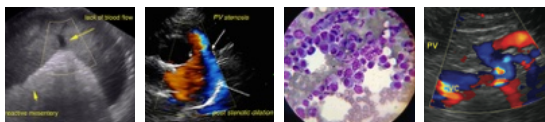
The spleen exhibited a finely textured and homogenous parenchyma which was hyperechoic to the liver and renal cortical parenchyma. The capsule was smooth and regular without apparent expansion. The splenic vasculature at the hilus was normal in volume with no evidence of congestion or thrombosis. Acute to chronic inflammatory, neoplastic, or benign parenchyma changes were not noted.

Liver/ Gallbladder

The liver was subjectively normal in size, structure, and contour. The liver parenchyma was uniform and hypoechoic to the spleen with a mild coarse echotexture. The hepatic and portal vasculature were normal in appearance without signs of congestion. The gallbladder was non-distended in size with thin walls and primarily anechoic luminal content. The cystic and common bile ducts were normal.

Gastrointestinal

The stomach presented intact wall layering with a normal wall layer ratio. The lumen of the stomach was empty with no signs of ileus, obstruction, or foreign material.



PATIENT

Gracie Walter

The small intestine presented intact wall layering with 1:3 muscularis/mucosa ratio. The lumen of the small intestine was empty with no signs of ileus, obstruction, or foreign material.

Normal visible colon wall layers were present with apparent formed feces in lumen.

SPECIES

Canine

Pancreas

The parenchyma of the left limb, body, and right limb of the pancreas presented isoechoic to the adjacent omental fat. A normal curvilinear capsule contour of the pancreas was present. The visible pancreatic duct was normal. No signs of active inflammation or neoplastic disease were evident.

BREED

Labrador X

Free Abdomen

SEX

Spayed Female

No overt lymphadenopathy or peritoneal effusion was present.

AGE

5 yrs

ULTRASONOGRAPHIC FINDINGS

Primary Findings

- Sonographically unremarkable abdomen.

WEIGHT

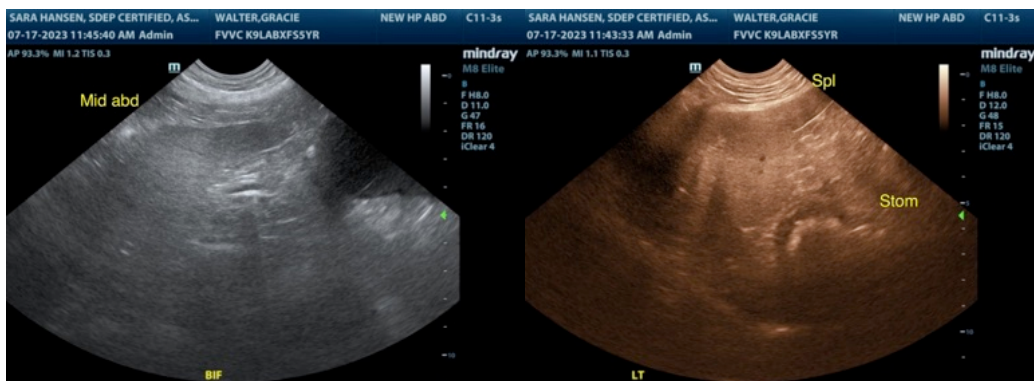
72 lbs

INTERPRETATION OF THE FINDINGS & FURTHER RECOMMENDATIONS

No sonographic evidence of visceral pathology.

INTERPRETED BY

R. McKenzie Daniel,
DVM, DABVP (Canine
and Feline)



IMAGING PERFORMED BY

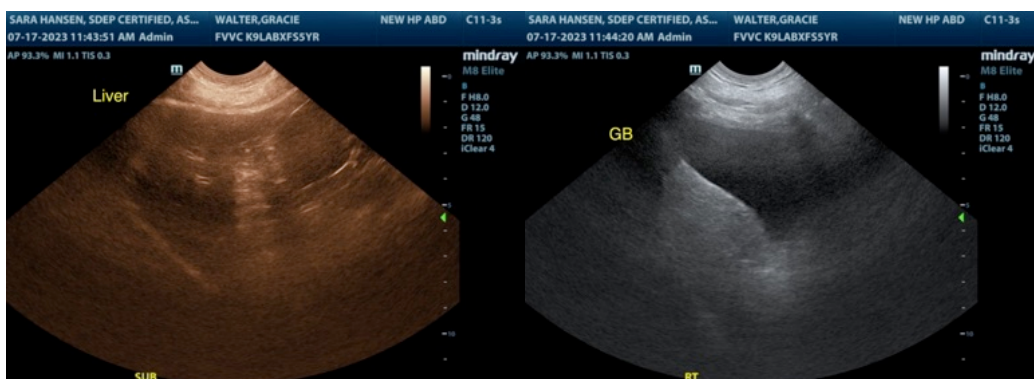
Sara Hansen

HOSPITAL NAME

Forest Valley
Veterinary Clinic

REFERRING VET

Dr. Walltz

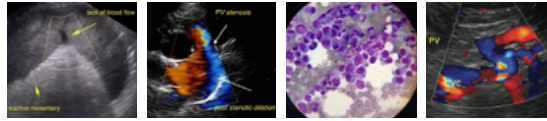


INVOICE

10332

DATE

7/17/2023



PATIENT

Gracie Walter

SPECIES

Canine

BREED

Labrador X

SEX

Spayed Female

AGE

5 yrs

WEIGHT

72 lbs

INTERPRETED BY

R. McKenzie Daniel,
DVM, DABVP (Canine
and Feline)

IMAGING PERFORMED BY

Sara Hansen

HOSPITAL NAME

Forest Valley
Veterinary Clinic

REFERRING VET

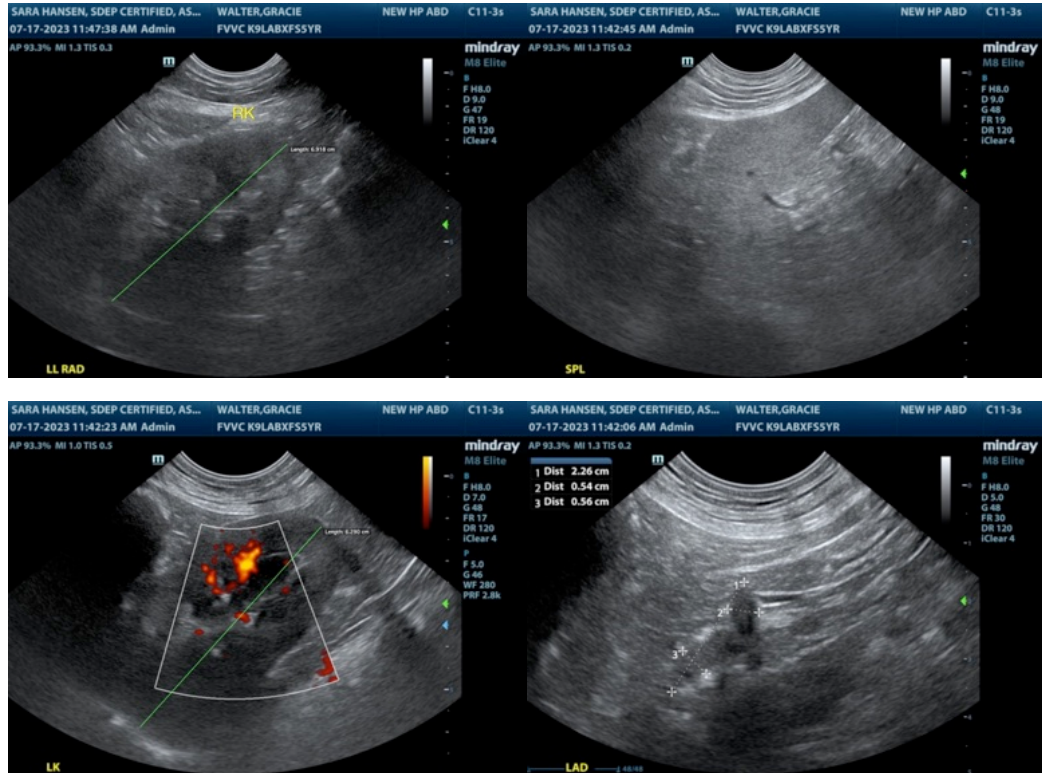
Dr. Walltz

INVOICE

10332

DATE

7/17/2023



The information and recommendations provided are based on the images presented by the referring veterinarian/sonographer. No evaluation can be communicated regarding pathology that was not visible in the image/video clips provided.

Thank you for this referral. If the clinical or image interpretation does not parallel your findings or if I can be of any further assistance, please contact me.

R. McKenzie Daniel, DVM, DABVP (Canine / Feline Practice)

info@SonoPath.com