



PATIENT	PRESENTING CLINICAL SIGNS
Patch Pico	Possible mid to cranial abdominal mass on palpation, weight loss, mild anemia. Current meds: Galliprant, Gabapentin
SPECIES	Abnormal PE/Chem/CBC/UA Results: HCT 36/2%, Hgb 11.8, MC 55, MCH 18, retics 105- mild non-regen anemia
Canine	
BREED	ULTRASONOGRAPHIC EXAMINATION OF THE ABDOMEN
Mix	Urinary System
SEX	The urinary bladder, trigone, cystourethral junction, and visible pelvic urethra to a depth of 3.0 cm exhibited normal thickness and tone. Anechoic urine was present in the lumen with no uroliths or sediment. The ureteral papillae were normal. The ureters were not visible which is normal. No evidence of inflammatory or neoplastic changes was noted.
MN	
AGE	No overt pathology was noted in the area of the residual prostate.
12 years	The area of the aortic trifurcation was free of pathology.
WEIGHT	Normal size and margination were present in the kidneys. A normal 1:3 cortex / medulla ratio was maintained. The medulla and cortices were uniform in texture with some increased echogenicity and mild loss of corticomedullary symmetry and definition expected for the age of the patient. Small lateral cortical infarction was present in the left kidney. No evidence of pelvic dilation was present. The left kidney measured 8.3 cm in length. The right kidney measured 8.5 cm in length.
96 lbs.	
INTERPRETED BY	Adrenal Glands
R. McKenzie Daniel, DVM, DABVP (Canine and Feline)	The bilateral adrenal glands were normal in size. Mild parenchyma heterogeneity and mild capsule asymmetry was present without suspicion for overt neoplasia. The left adrenal gland measured 3.8 cm length x 0.99 cm width at the caudal pole. The right adrenal gland measured 2.6 cm length x 0.62 cm width at the caudal pole.
IMAGING PERFORMED BY	Spleen
Jessica Miller	A mass involving the spleen with secondary asymmetrical capsule expansion and disruption was present and measured approximately 18 cm in diameter. The parenchyma of the mass was heterogeneous to mixed echogenic with areas of cavitation. The portion of the spleen not involved with the mass exhibited finely textured and homogenous parenchyma and normal symmetrical capsule contour. The splenic vasculature at the hilus was normal in volume with no evidence of congestion or thrombosis. Regional omental inflammation was present around the mass.
HOSPITAL NAME	Liver/ Gallbladder
Millburn VH	The liver was subjectively normal in size, structure, and contour. The liver parenchyma was mildly nonuniform and hypoechoic to the spleen with a moderate coarse echotexture and subjective mild to benign parenchymal remodeling. The hepatic and portal vasculature were normal in appearance without signs of congestion. The gallbladder was non-distended in size with thin walls and primarily anechoic luminal content. The cystic and common bile ducts were normal.
REFERRING VET	
Dr. Turowsky	
INVOICE	
14287	
DATE	
7/13/22	



PATIENT

Gastrointestinal

Patch Pico

The stomach presented intact wall layering with a normal wall layer ratio. The lumen of the stomach was empty with no signs of ileus, obstruction, or foreign material.

SPECIES

Canine

The small intestine presented intact wall layering with 1:3 muscularis/mucosa ratio. The lumen of the small intestine was empty with no signs of ileus, obstruction, or foreign material.

BREED

Mix

Normal visible colon wall layers were present with apparent formed feces in lumen.

SEX

MN

Pancreas

The parenchyma of the left limb, body, and right limb of the pancreas presented isoechoic to the adjacent omental fat. A normal curvilinear capsule contour of the pancreas was present. The visible pancreatic duct was normal. No signs of active inflammation or neoplastic disease were evident.

AGE

12 years

Free Abdomen

A small pocket of scant free fluid was noted in the caudal abdomen adjacent to the urinary bladder. Subtle evidence of perisplenic reactive mesentery was noted. No obvious evidence of omental adhesions to the splenic mass, although cannot be definitively excluded. No overt lymphadenopathy was present.

WEIGHT

96 lbs.

Rapid view of the heart revealed no evidence of pericardial masses or effusion in the visible window.

INTERPRETED BY

R. McKenzie Daniel,
DVM, DABVP
(Canine and Feline)

ULTRASONOGRAPHIC FINDINGS

- Large mixed echogenic to cavitated splenic mass
- Mild hepatic parenchymal remodeling - subjectively benign
- Mild chronic renal changes with minor lateral left kidney cortical infarction
- Small pocket of scant peritoneal free fluid

IMAGING PERFORMED BY

Jessica Miller

INTERPRETATION OF THE FINDINGS & FURTHER RECOMMENDATIONS

HOSPITAL NAME

Millburn VH

Although histopathology is required for definitive diagnosis, the splenic mass is most suggestive of neoplasia such as sarcoma or other. Benign pathologies are possible, yet considered less likely. No overt evidence of perisplenic, lymphatic, or major organ metastasis was noted. The possibility of non-visualized metastasis / micrometastasis in these cases cannot be definitively excluded.

REFERRING VET

Dr. Turowsky

Three view chest radiographs are suggested. If no evidence of thoracic pathology / metastasis, laparotomy with expectation towards splenectomy, gross inspection of the perisplenic omentum, and liver would be warranted. A guarded prognosis, pending splenic histopathology, is warranted.

INVOICE

14287

DATE

7/13/22



PATIENT

Patch Pico

SPECIES

Canine

BREED

Mix

SEX

MN

AGE

12 years

WEIGHT

96 lbs.

INTERPRETED BY

R. McKenzie Daniel,
DVM, DABVP
(Canine and Feline)

IMAGING PERFORMED BY

Jessica Miller

HOSPITAL NAME

Millburn VH

REFERRING VET

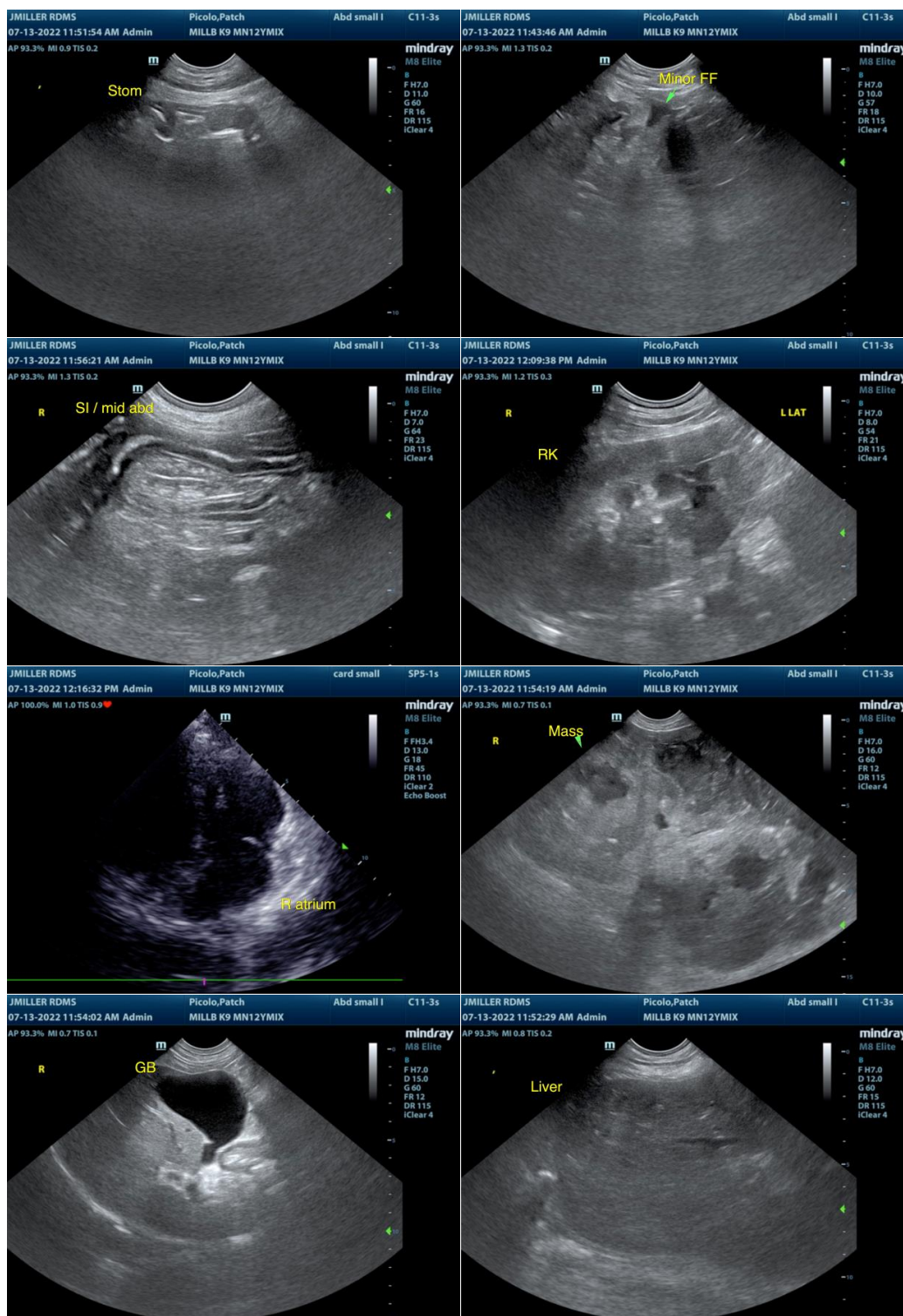
Dr. Turowsky

INVOICE

14287

DATE

7/13/22





PATIENT

Patch Pico

SPECIES

Canine

BREED

Mix

SEX

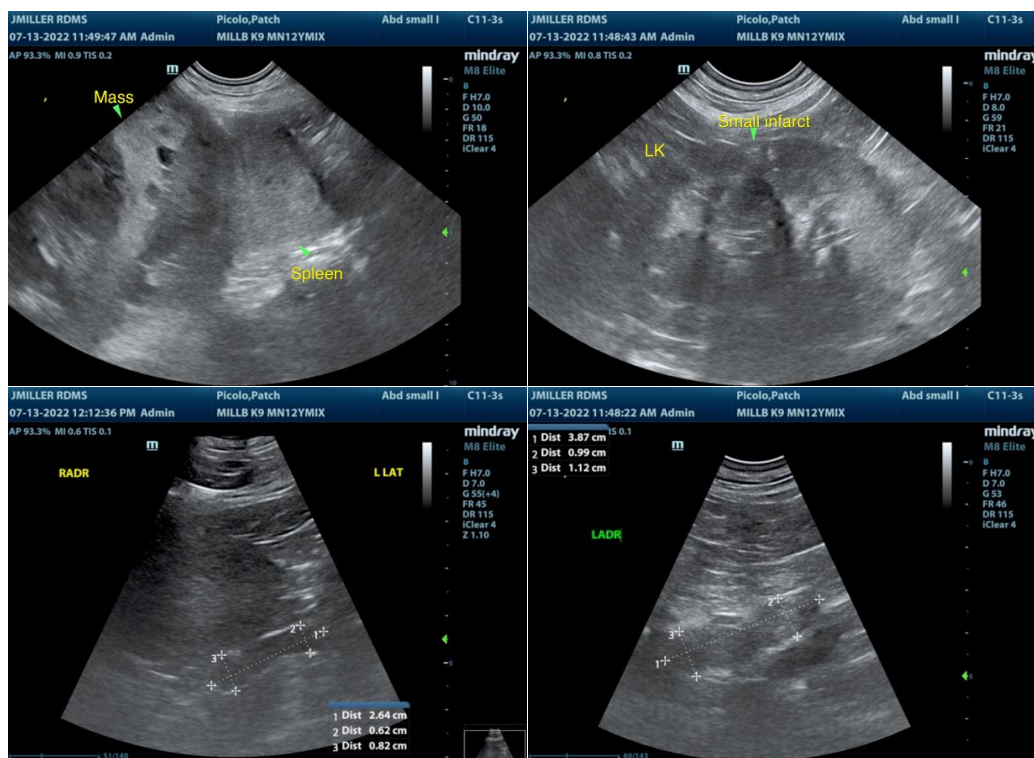
MN

AGE

12 years

WEIGHT

96 lbs.



INTERPRETED BY

R. McKenzie Daniel,
DVM, DABVP
(Canine and Feline)

IMAGING PERFORMED BY

Jessica Miller

HOSPITAL NAME

Millburn VH

REFERRING VET

Dr. Turowsky

INVOICE

14287

DATE

7/13/22

The information and recommendations provided are based on the images presented by the referring veterinarian/sonographer. No evaluation can be communicated regarding pathology that was not visible in the image/video clips provided.

Thank you for this referral. If the clinical or image interpretation does not parallel your findings or if I can be of any further assistance please contact me.

R. McKenzie Daniel, DVM, DABVP (Canine / Feline Practice)
info@SonoPath.com