



PATIENT PRESENTING CLINICAL SIGNS

Zena Lusty Presented last friday with a hx of anorexia, lethargy for past 5 days. PE: quiet, a little dull, mild dehydration, painful abdomen meds: gabapentin 600mg TID, tramadol 150mg BID-owners were not able to get any meds into her, was given Torb a few hours before scan

SPECIES Abnormal PE/Chem/CBC/UA Results: elevated snap CPL, amylase and lipase, mild lymphopenia, monocytosis

Canine

BREED ULTRASONOGRAPHIC EXAMINATION OF THE ABDOMEN

Shep X **Urinary System**

SEX The urinary bladder, trigone, cystourethral junction, and visible pelvic urethra to a depth of 3.0 cm exhibited normal thickness and tone. Anechoic urine was present in the lumen with no uroliths or sediment. The ureteral papillae were normal. The ureters were not visible which is normal. No evidence of inflammatory or neoplastic changes was noted.

FS

AGE The area of the aortic trifurcation was free of pathology.

10 years Normal size and margination were present in the kidneys. A normal 1:3 cortex / medulla ratio was maintained. The medulla and cortices were uniform in texture with some increased echogenicity and mild loss of corticomedullary symmetry and definition expected for the age of the patient. No evidence of pelvic dilation was present. The left kidney measured 6.5 cm in length. The right kidney measured 6.6 cm in length.

WEIGHT

31.2 kg

Adrenal Glands

INTERPRETED BY

R. McKenzie Daniel,
DVM, DABVP

The left adrenal gland was uniform in size and contour with a uniformly hypoechoic parenchyma. The left adrenal gland measured 2.3 cm length x 0.65 cm width at the caudal pole. The right adrenal gland was indistinctly visualized owing to patient size and conformation yet without overt pathology subjectively measuring 2.3 cm length x 0.60 cm width at the caudal pole.

IMAGING PERFORMED BY

Kelly Reschny

Spleen

HOSPITAL NAME

Preston AC

The spleen exhibited a finely textured and homogenous parenchyma which was hyperechoic to the liver and renal cortical parenchyma. The capsule was smooth and regular without apparent expansion. The splenic vasculature at the hilus was normal in volume with no evidence of congestion or thrombosis. Acute to chronic inflammatory, neoplastic, or benign parenchyma changes were not noted.

REFERRING VET

Dr. Coghlan

Liver/ Gallbladder

INVOICE

14276

The liver was subjectively normal in size, structure, and contour. The liver parenchyma was uniform and hypoechoic to the spleen with a mild coarse echotexture. The hepatic and portal vasculature were normal in appearance without signs of congestion. The gallbladder was non-distended in size containing primarily anechoic content with a mild amount of congealed mildly hyperechoic luminal debris present in the cranial lumen. The gallbladder walls were overtly normal without obvious inflammatory criteria. No evidence of peripheral gallbladder inflammation was noted. The cystic and common bile ducts were normal.

DATE

7/12/22



PATIENT

Gastrointestinal

Zena Lusty

The stomach presented intact wall layering with a normal wall layer ratio. The lumen of the stomach was empty with no signs of retained ingesta, fluid, or foreign material. The stomach contained mild luminal gas. The ventral gastric body wall width measured 0.54 cm.

SPECIES

Canine

The small intestine presented intact wall layering with 1:3 muscularis/mucosa ratio. The lumen of the small intestine was empty with no signs of ileus, obstruction, or foreign material. The small Intestinal wall width measured 0.45 cm.

BREED

Shep X

Normal visible colon wall layers were present with apparent formed feces in lumen.

Pancreas

SEX

FS

The parenchyma of the left limb, body, and right limb of the pancreas presented isoechoic to the adjacent omental fat. A normal curvilinear capsule contour of the pancreas was present. The visible pancreatic duct was normal. No signs of active inflammation or neoplastic disease were evident. No evidence of sonographically active pancreatitis or neoplastic criteria was noted.

AGE

10 years

Free Abdomen

No omental masses, lymphadenopathy or evidence of peritoneal free fluid was present.

WEIGHT

31.2 kg

ULTRASONOGRAPHIC FINDINGS

- Sonographically unremarkable gastrointestinal tract
- Mild congealed gallbladder debris (non-mucocele) - suspect incidental possibly owing to fasting

INTERPRETED BY

R. McKenzie Daniel,
DVM, DABVP

INTERPRETATION OF THE FINDINGS & FURTHER RECOMMENDATIONS

No overt evidence of abdominal visceral pathology as an obvious cause of the patient's anorexia and lethargy. Potential for low-grade gastroenteritis or pancreatitis, both of which may present as sonographically normal, could be possible.

IMAGING PERFORMED BY

Kelly Reschny

Likewise, the possibility of an extra-abdominal cause of anorexia and lethargy, i.e., muscular / skeletal disease, could be considered.

HOSPITAL NAME

Preston AC

Although considered unlikely, resting cortisol level to rule out occult Addison's Disease could be considered. Continued as-needed gastrointestinal support would be reasonable.

REFERRING VET

Dr. Coghlan

INVOICE

14276

DATE

7/12/22



PATIENT

Zena Lusty

SPECIES

Canine

BREED

Shep X

SEX

FS

AGE

10 years

WEIGHT

31.2 kg

INTERPRETED BY

R. McKenzie Daniel,
DVM, DABVP

**IMAGING
PERFORMED BY**

Kelly Reschny

HOSPITAL NAME

Preston AC

REFERRING VET

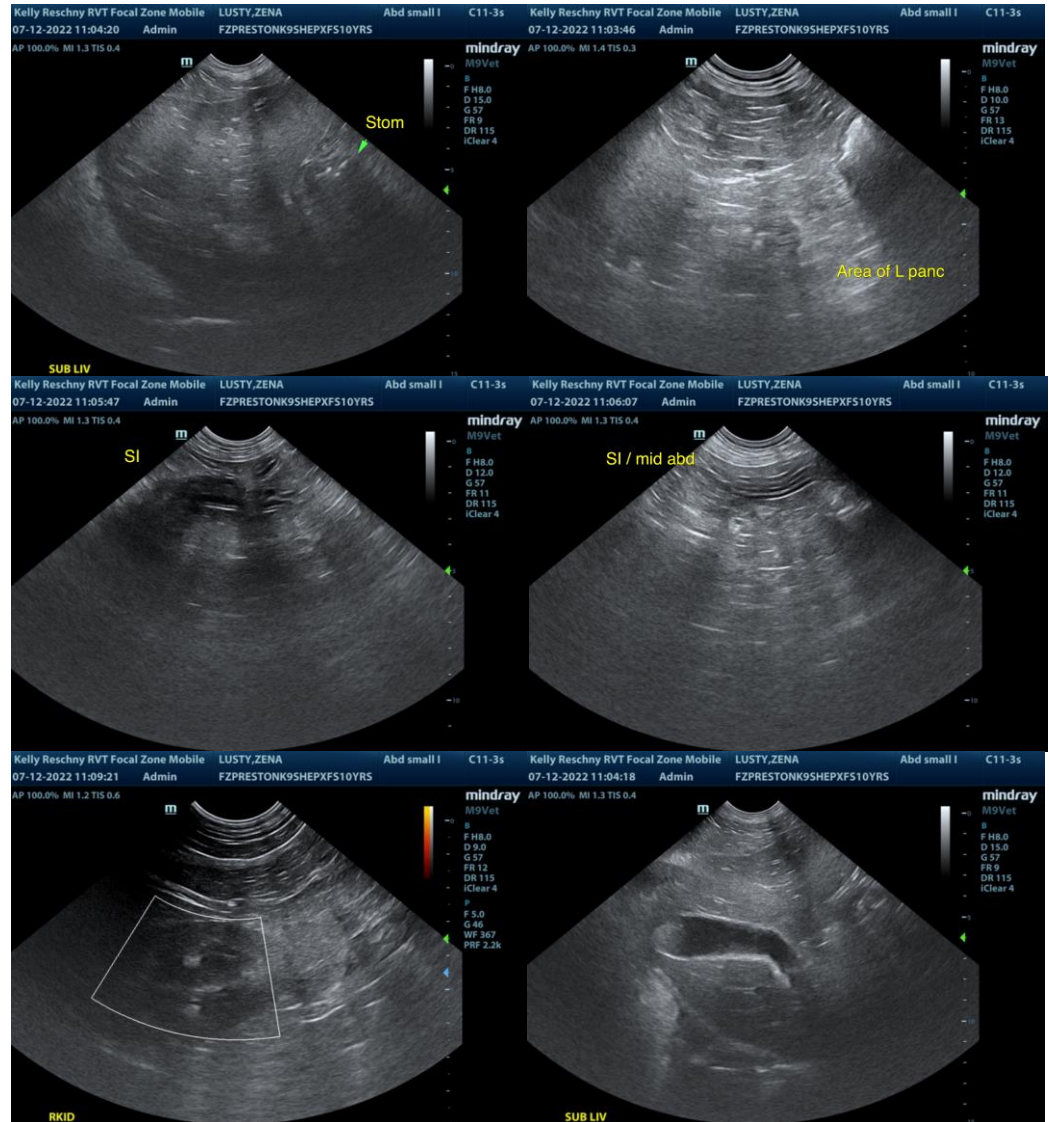
Dr. Coghlan

INVOICE

14276

DATE

7/12/22





PATIENT

Zena Lusty

SPECIES

Canine

BREED

Shep X

SEX

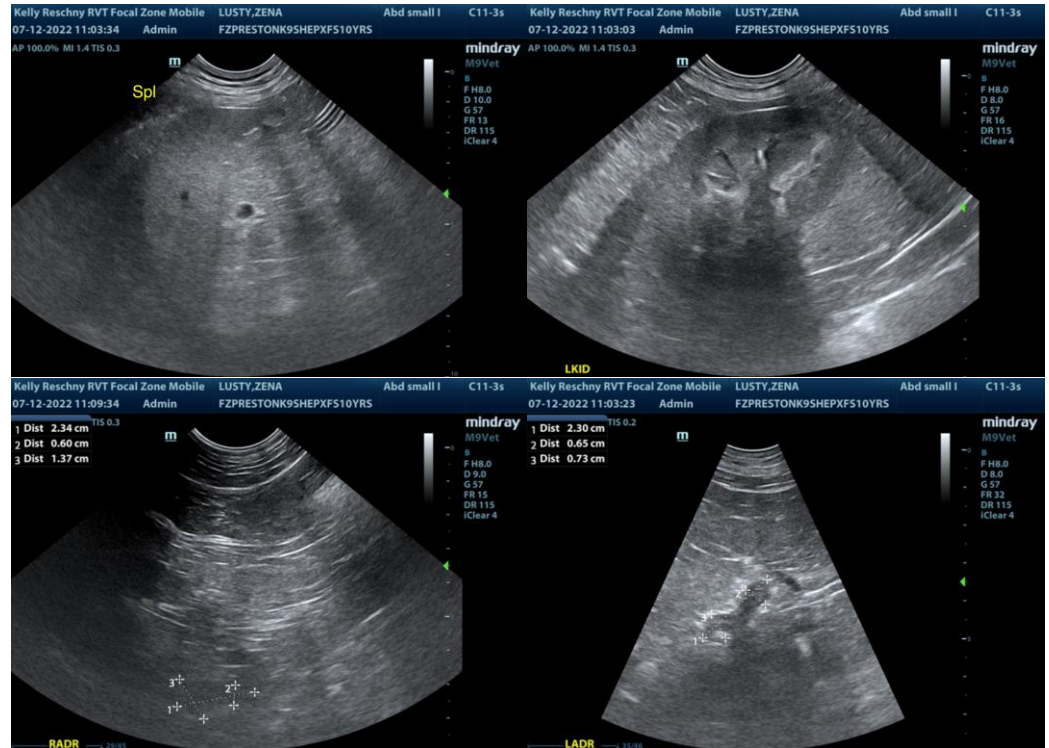
FS

AGE

10 years

WEIGHT

31.2 kg



INTERPRETED BY

R. McKenzie Daniel,
DVM, DABVP

**IMAGING
PERFORMED BY**

Kelly Reschny

HOSPITAL NAME

Preston AC

REFERRING VET

Dr. Coghlan

INVOICE

14276

DATE

7/12/22

The information and recommendations provided are based on the images presented by the referring veterinarian/sonographer. No evaluation can be communicated regarding pathology that was not visible in the image/video clips provided.

Thank you for this referral. If the clinical or image interpretation does not parallel your findings or if I can be of any further assistance please contact me.

R. McKenzie Daniel, DVM, DABVP (Canine / Feline Practice)
info@SonoPath.com