

PATIENT

Jameson Damewood

SPECIES

Feline

BREED

DLH

SEX

MN

AGE

15 yr

WEIGHT

7.68lb

INTERPRETED BY

R. McKenzie Daniel,
DVM, DABVP
(Canine and Feline)

**IMAGING
PERFORMED BY**

Sara Hansen

HOSPITAL NAME

Cottage Grove
Veterinary Hospital

REFERRING VET

Dr. Damewood

INVOICE

11114ag

DATE

07/12/2022

PRESENTING CLINICAL SIGNS

History: Significant recent weight loss. Brief period of diarrhea 3 weeks ago, now resolved. Appetite fair, still losing weight. FB sx for hairball removal 10/19 with resection and again on 4/20.

Abnormal PE/Chem/CBC/UA Results: SDMA 16 Creat 2.2 Alb 2.3 rest unremarkable.

ULTRASONOGRAPHIC EXAMINATION OF THE ABDOMEN

Urinary System

The urinary bladder, trigone, cystourethral junction, and visible pelvic urethra to a depth of 2 cm exhibited normal thickness and tone. Anechoic urine was present in the lumen with no uroliths or sediment. The ureteral papillae were normal. The ureters were not visible which is normal. No evidence of inflammatory or neoplastic changes were noted.

The left kidney was subnormal in size with asymmetrical margination, marked loss of corticomedullary border demarcation and subjective reduced medullary volume. Normal size and margination were present in the kidneys. The left kidney measured 2.4 cm in length.

Normal renal size with symmetrical margination was present in the right kidney. The renal cortex presented uniformly increased in echogenicity with uniform echotexture. The renal cortex appeared to be hypertrophied resulting in an altered cortex: medulla ratio. Mild loss of corticomedullary distinction was also present. The renal medullary volume was subjectively reduced. The right kidney measured 4.5 cm in length.

The area of the aortic trifurcation was free of pathology.

Adrenal Glands

The left adrenal gland was uniform in size and contour with a uniformly hypoechoic parenchyma. The left adrenal gland measured 0.36 cm width. The right adrenal gland was uniform in size and contour with a uniformly hypoechoic parenchyma. The right adrenal gland measured 0.45 cm width.

Spleen

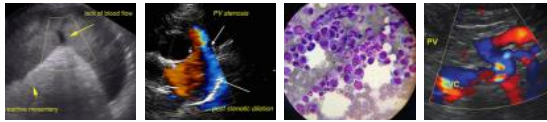
The spleen exhibited a finely textured and homogenous parenchyma which was hyperechoic to the liver and renal cortical parenchyma. The capsule was smooth and regular without apparent expansion. The splenic vasculature at the hilus was normal in volume with no evidence of congestion or thrombosis. Acute to chronic inflammatory, neoplastic, or benign parenchyma changes were not noted. The spleen measured 0.5 cm in width at the level of the hilus.

Liver

The liver was subjectively normal in size, structure, and contour. The liver parenchyma was mildly nonuniform and hypoechoic to the spleen with a moderate coarse echotexture and subjective mild to benign parenchymal remodeling. The hepatic and portal vasculature were normal in appearance without signs of congestion.

The gallbladder was non-distended in size with thin walls and primarily anechoic luminal content. The cystic and common bile ducts were normal.

Gastrointestinal



PATIENT
Jameson Damewood

The stomach presented intact wall layering with a normal wall layer ratio. The lumen of the stomach contained a mild amount of retained mildly hyperechoic to progressively shadowing ingesta with no signs of ileus, obstruction or foreign material.

SPECIES
Feline

A large intestinal mural mass occupying the majority of the mid to cranial abdomen measuring approximately 7-8 cm in length was present. The mass exhibited decreased mural echogenicity and a loss of discernible intestinal wall layering.

BREED
DLH

Normal visible colon wall layers were present with apparent formed feces in lumen.

SEX
MN

Pancreas

The parenchyma of the left limb, body and right limb of the pancreas presented isoechoic to the adjacent omental fat. A normal curvilinear capsule contour of the pancreas was present. The visible pancreatic duct was normal. No signs of active inflammation or neoplastic disease was evident.

AGE
15 yr

Free Abdomen

Regional nonuniform to hypoechoic nodular omentum within the mid to cranial abdomen was present primarily around the intestinal mural mass. Mild volume peritoneal free fluid was present.

WEIGHT
7.68lb

ULTRASONOGRAPHIC FINDINGS

INTERPRETED BY
R. McKenzie Daniel,
DVM, DABVP
(Canine and Feline)

- Large intestinal mural mass
- Mid to cranial abdominal nonuniform nodular mesentery
- Mild volume peritoneal free fluid exhibiting echogenic changes
- Bilateral chronic renal changes

INTERPRETATION OF THE FINDINGS & FURTHER RECOMMENDATIONS

IMAGING PERFORMED BY
Sara Hansen

The primary finding of the large intestinal mural mass is consistent with high grade neoplastic criteria. The nonuniform nodular mid to cranial abdominal mesentery is strongly suggestive of regional omental seeding to ill-defined mesenteric mass and suspected lymphomatosis. An ultrasound guided FNA of the mass +/- fluid analysis cytology could be considered for further assessment with potential for oncology consult. However surgical options appear to be precluded in this case. An unfavorable long-term prognosis is likely indicated.

HOSPITAL NAME
Cottage Grove
Veterinary Hospital

REFERRING VET
Dr. Damewood

INVOICE
11114ag

DATE
07/12/2022



PATIENT

Jameson Damewood

SPECIES

Feline

BREED

DLH

SEX

MN

AGE

15 yr

WEIGHT

7.68lb

INTERPRETED BY

R. McKenzie Daniel,
DVM, DABVP
(Canine and Feline)

IMAGING PERFORMED BY

Sara Hansen

HOSPITAL NAME

Cottage Grove
Veterinary Hospital

REFERRING VET

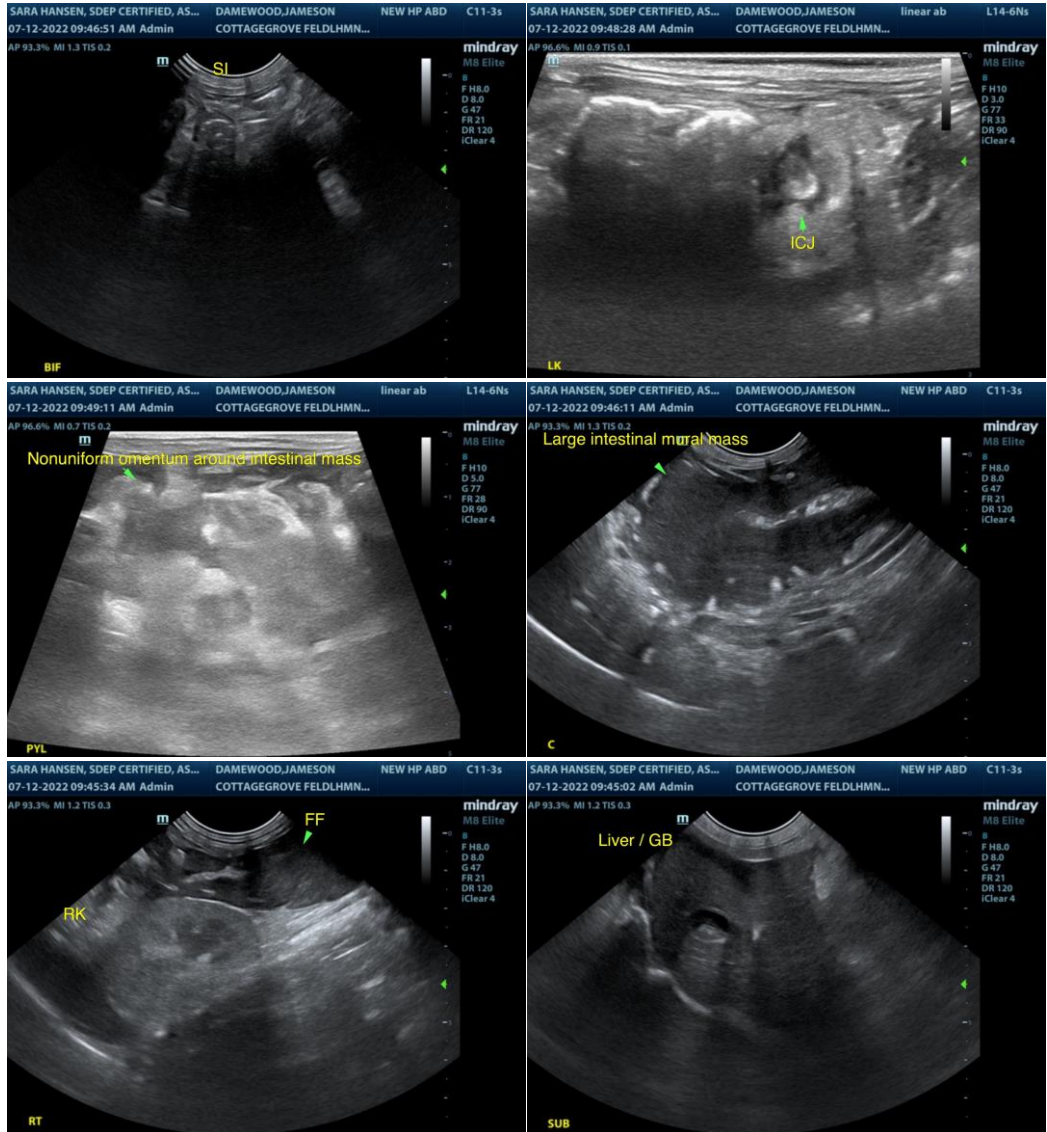
Dr. Damewood

INVOICE

11114ag

DATE

07/12/2022





PATIENT

Jameson Damewood

SPECIES

Feline

BREED

DLH

SEX

MN

AGE

15 yr

WEIGHT

7.68lb

INTERPRETED BY

R. McKenzie Daniel,
DVM, DABVP
(Canine and Feline)

IMAGING PERFORMED BY

Sara Hansen

HOSPITAL NAME

Cottage Grove
Veterinary Hospital

REFERRING VET

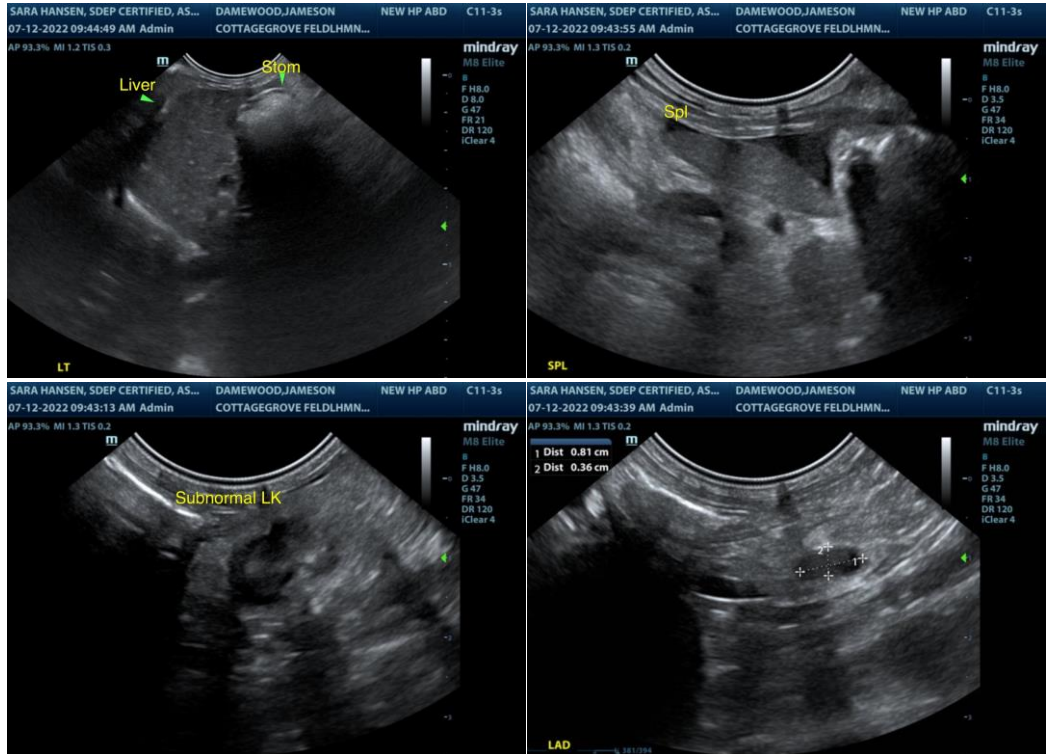
Dr. Damewood

INVOICE

11114ag

DATE

07/12/2022



The information and recommendations provided are based on the images presented by the referring veterinarian/sonographer. No evaluation can be communicated regarding pathology that was not visible in the image/video clips provided.

Thank you for this referral. If the clinical or image interpretation does not parallel your findings or if I can be of any further assistance please contact me.

R. McKenzie Daniel, DVM, DABVP (Canine / Feline Practice)

info@SonoPath.com