



PATIENT

Misty Grosh

SPECIES

Feline

BREED

DSH

SEX

FS

AGE

4yr

WEIGHT

10.7lb

INTERPRETED BY

R. McKenzie Daniel,
DVM, DABVP
(Canine and Feline)

IMAGING PERFORMED BY

Dr. Jennifer Todd

HOSPITAL NAME

Lambs Gap Animal
Hospital

REFERRING VET

Dr. Michelle Nelson

INVOICE

11105ag

DATE

07/12/2022

PRESENTING CLINICAL SIGNS

History: Misty is a four year old, FS, DSH cat who was presented to our local ER on 7/2/22. Seen at ER 7/2/22 for diarrhea, decreased appetite and lethargy. 2V Abd Rads unremarkable and CBC/Chem/Lytes showed mild dehydration. Owner chose to try outpatient care (SQF, Cerenia inj, Metronidazole to go home). Pet initially showed some improvement (not 100%) but appetite and energy declining again.

Abnormal PE/Chem/CBC/UA Results: 7/12/22: CBC, Chemistry, Electrolytes and Felv/FIV test all normal

ULTRASONOGRAPHIC EXAMINATION OF THE ABDOMEN

Urinary System

The urinary bladder, trigone, cystourethral junction, and visible pelvic urethra to a depth of 2 cm exhibited normal thickness and tone. Anechoic urine was present in the lumen with dependent nonmineralized sediment. The ureteral papillae were normal. The ureters were not visible which is normal. No evidence of inflammatory or neoplastic changes were noted.

Normal size and margination were present in the kidneys. A normal 1:3 cortex / medulla ratio and normal corticomedullary definition were maintained. The echogenicity of the cortex was similar to or slightly less than normal liver parenchyma while the medulla echogenicity was hypoechoic to the cortex with no evidence of pelvic dilation. The left kidney measured 3.6 cm in length. The right kidney measured 3.9 cm in length.

The area of the aortic trifurcation was free of pathology.

Adrenal Glands

The left adrenal gland was uniform in size and contour with a uniformly hypoechoic parenchyma. The left adrenal gland measured 0.27 cm width. The right adrenal gland was uniform in size and contour with a uniformly hypoechoic parenchyma. The right adrenal gland measured 0.38 cm width.

Spleen

The spleen exhibited a finely textured and homogenous parenchyma which was hyperechoic to the liver and renal cortical parenchyma. The capsule was smooth and regular without apparent expansion. The splenic vasculature at the hilus was normal in volume with no evidence of congestion or thrombosis. Acute to chronic inflammatory, neoplastic, or benign parenchyma changes were not noted. The spleen measured 0.7 cm in width at the level of the hilus.

Liver

The liver was subjectively normal in size, structure, and contour. The liver parenchyma was uniform and hypoechoic to the spleen with a mild coarse echotexture. The hepatic and portal vasculature were normal in appearance without signs of congestion. The gallbladder was non-distended in size with thin walls and primarily anechoic luminal content. The cystic and common bile ducts were normal.

Gastrointestinal

The stomach presented intact wall layering with a normal wall layer ratio. The lumen of the stomach was empty with no signs of ileus, obstruction or foreign material. The gastric body wall measured 0.25 cm in width.



PATIENT

Misty Grosh

The small intestine presented intact wall layering with 1:3 muscularis/mucosa ratio. The lumen of the small intestine was empty with no signs of ileus, obstruction or foreign material. The duodenum wall measured 0.22 cm in width. The jejunum wall measured 0.21 cm in width.

SPECIES

Feline

Normal visible colon wall layers were present with apparent formed feces in lumen.

Pancreas

The parenchyma of the left limb, body and right limb of the pancreas presented isoechoic to the adjacent omental fat. A normal curvilinear capsule contour of the pancreas was present. The visible pancreatic duct was normal. No signs of active inflammation or neoplastic disease was evident.

BREED

DSH

Free Abdomen

No peritoneal effusion was present.

SEX

FS

Intermittent mildly enlarged mid abdominal mesenteric lymph nodes were present. These lymph nodes were homogenous, mildly hypoechoic and smoothly marginated. A normal width: length ratio was maintained (<0.5). Evidence of perilymphatic inflammation was evident. An example of lymph node size was 0.33 cm width.

AGE

4yr

ULTRASONOGRAPHIC FINDINGS

WEIGHT

10.7lb

- Sonographically unremarkable GI tract and pancreas
- Mildly prominent mid abdominal mesenteric lymph nodes

INTERPRETATION OF THE FINDINGS & FURTHER RECOMMENDATIONS

Overall, no evidence of significant abdominal visceral pathology or disease was observed. Suspect minor mesenteric lymphadenitis potentially owing to a structurally insignificant inflammatory episode. No overt evidence of GI pancreatic or lymphatic neoplastic criteria was present. Potential for concurrent low-grade pancreatitis could be present yet appear sonographically normal. A spec fPL or A GI panel to include PLI/TLI/Cobalamin/Folate is recommended for further assessment. Supportive care for inflammatory bowel episode and suspected mild lymphadenitis which may include a hydrolyzed diet trial, Zithromax/metronidazole combination and as needed GI support. If current or recurrent diarrhea, a fresh fecal analysis to rule out parasitic ova/giardia +/- diarrhea PCR panel could be considered.

INTERPRETED BY

R. McKenzie Daniel,
DVM, DABVP
(Canine and Feline)

IMAGING PERFORMED BY

Dr. Jennifer Todd

HOSPITAL NAME

Lambs Gap Animal
Hospital

REFERRING VET

Dr. Michelle Nelson

INVOICE

11105ag

DATE

07/12/2022



PATIENT

Misty Grosh

SPECIES

Feline

BREED

DSH

SEX

FS

AGE

4yr

WEIGHT

10.7lb

INTERPRETED BY

R. McKenzie Daniel,
DVM, DABVP
(Canine and Feline)

IMAGING PERFORMED BY

Dr. Jennifer Todd

HOSPITAL NAME

Lambs Gap Animal Hospital

REFERRING VET

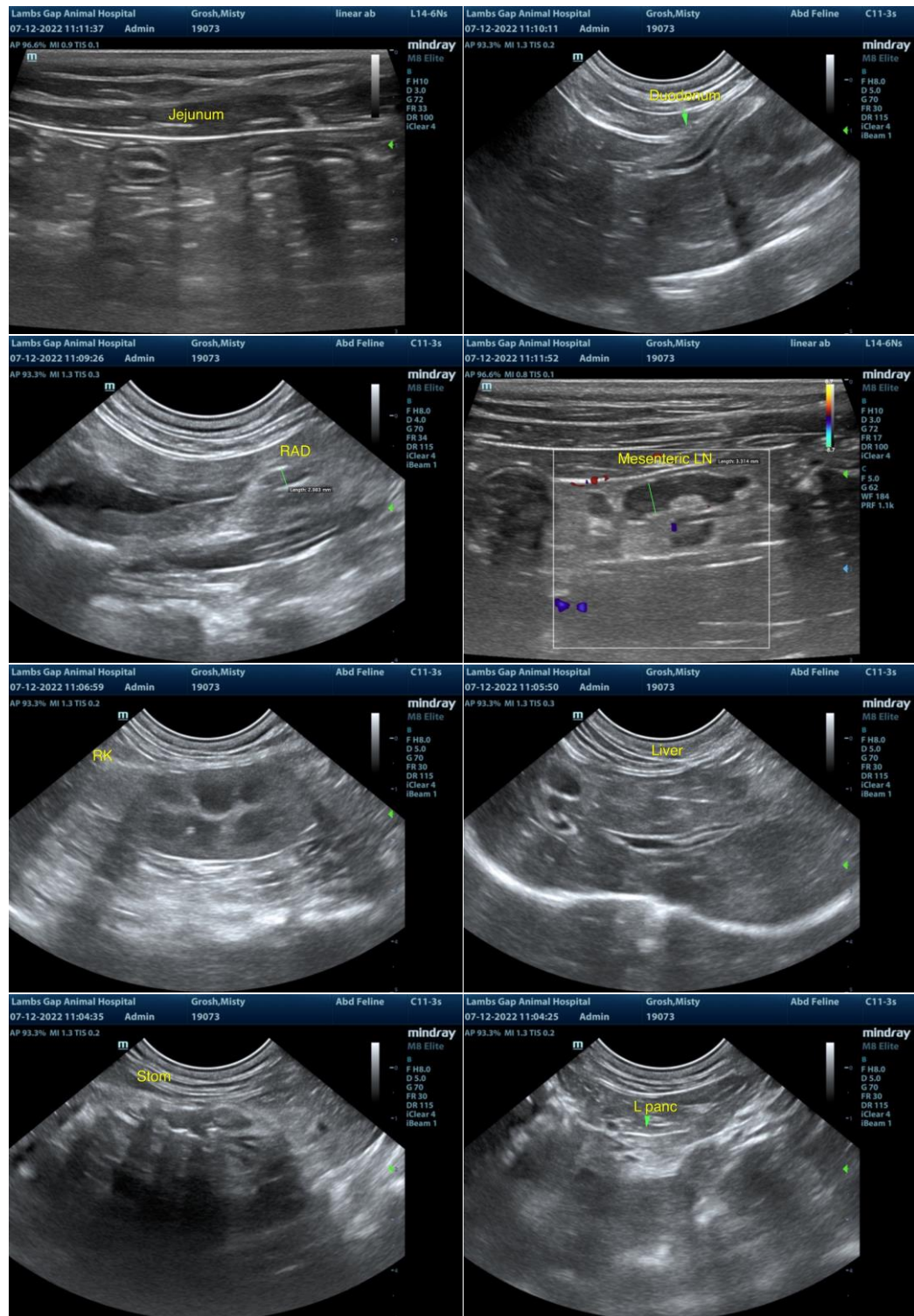
Dr. Michelle Nelson

INVOICE

11105ag

DATE

07/12/2022





PATIENT

Misty Grosh

SPECIES

Feline

BREED

DSH

SEX

FS

AGE

4yr

WEIGHT

10.7lb

INTERPRETED BY

R. McKenzie Daniel,
DVM, DABVP
(Canine and Feline)

IMAGING PERFORMED BY

Dr. Jennifer Todd

HOSPITAL NAME

Lambs Gap Animal
Hospital

REFERRING VET

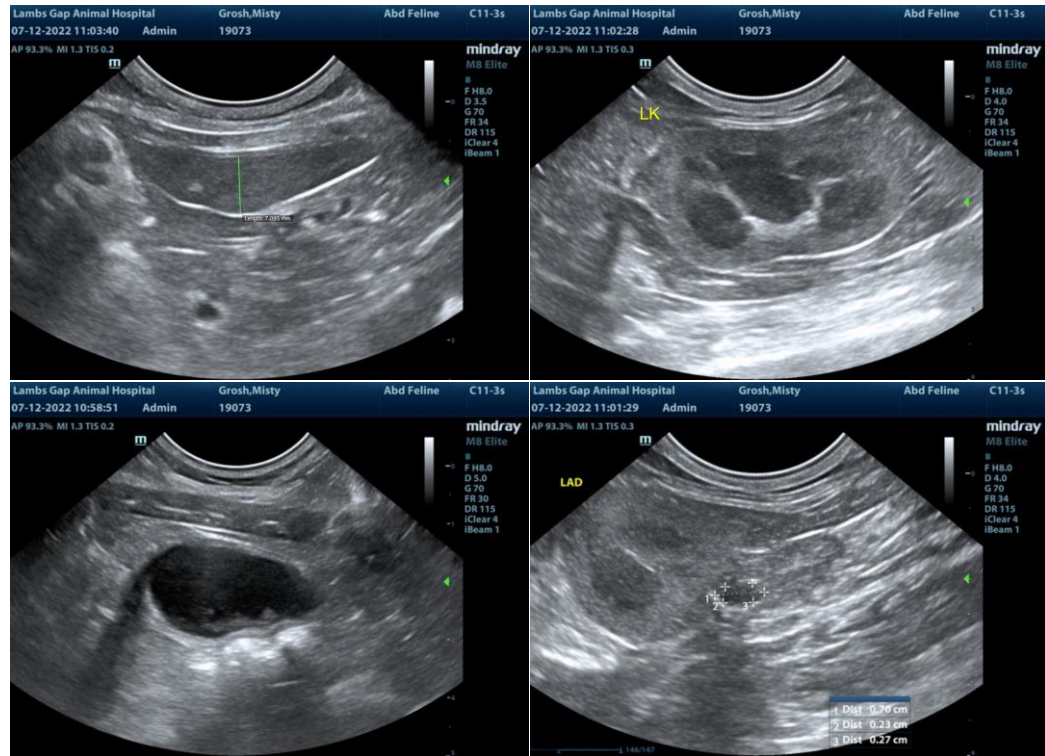
Dr. Michelle Nelson

INVOICE

11105ag

DATE

07/12/2022



The information and recommendations provided are based on the images presented by the referring veterinarian/sonographer. No evaluation can be communicated regarding pathology that was not visible in the image/video clips provided.

Thank you for this referral. If the clinical or image interpretation does not parallel your findings or if I can be of any further assistance please contact me.

R. McKenzie Daniel, DVM, DABVP (Canine / Feline Practice)

info@SonoPath.com