



**PATIENT**

Hayley Andrea

**SPECIES**

Canine

**BREED**

Husky

**SEX**

FS

**AGE**

16 years

**WEIGHT**

36 lbs.

**INTERPRETED BY**

R. McKenzie Daniel, DVM,  
DABVP (Canine and  
Feline)

**IMAGING  
PERFORMED BY**

Pamela Harrigan, RDCS

**HOSPITAL NAME**

Wood River AH

**REFERRING VET**

Leah Fischer, DVM

**INVOICE**

14189

**DATE**

7/1/22

**PRESENTING CLINICAL SIGNS**

History mild chronic renal disease, presented this week for ADR and lethargy. Anorexia x 3 days. Icteric on exam. 3 lb weight loss since January. Creat 1.5; SDMA 13; BUN 25; ALP and ALT too high to read; GGT 21; Tbili 6.7

**ULTRASONOGRAPHIC EXAMINATION OF THE ABDOMEN**

**Urinary System**

The urinary bladder, trigone, and cystourethral junction exhibited normal thickness and tone. Anechoic urine was present in the lumen with no uroliths or sediment. The ureteral papillae were normal. The ureters were not visible which is normal. No evidence of inflammatory or neoplastic changes was noted.

Visualized medial iliac lymph nodes were sonographically normal exhibiting normal width to length: length ratio (<0.5) and uniform isoechoic parenchyma. No evidence of medial iliac inflammatory or neoplastic criteria was noted.

Normal margination was present in the kidneys. A normal 1:3 cortex / medulla ratio was maintained. The medulla and cortices were uniform in texture with some increased echogenicity and mild loss of corticomedullary symmetry and definition expected for the age of the patient. Small thinly-walled cortical cyst containing anechoic fluid was present in the left kidney measuring 0.65 cm in diameter. Minor pyelectasia was noted in the left and right kidneys. The left kidney measured 6.0 cm in length. The right kidney was mildly subnormal in size compared to the left measuring 4.6 cm in length.

**Adrenal Glands**

The left adrenal gland was uniform in size and contour with a uniformly hypoechoic parenchyma. The left adrenal gland measured 0.39 cm width at the caudal pole and 0.45 cm width at the cranial pole. The right adrenal gland was uniform in size and contour with a uniformly hypoechoic parenchyma. The right adrenal gland measured 0.54 cm width at the caudal pole.

**Spleen**

The spleen exhibited primarily finely textured parenchyma which was hyperechoic to the liver and renal cortical parenchyma. Mild generalized parenchyma heterogeneity was present without evidence of nodular changes. The capsule was smooth and regular without apparent expansion. The splenic vasculature at the hilus was normal in volume with no evidence of congestion or thrombosis. The parenchymal heterogeneity is likely consistent with benign changes such as extramedullary hematopoiesis or age-related remodeling with minor potential for inflammatory or neoplastic disease.

**Liver/ Gallbladder**

The liver was overtly normal in size. The hepatic parenchyma was mildly hypoechoic compared to the spleen and renal cortical parenchyma with a mild coarse echotexture. Mild increased portal vein prominence was evident. The capsule of the liver was normal in margination. Distinct masses or nodules were not evident. The hepatic and portal vasculature were normal in appearance.

The gallbladder was mildly distended with sonographically normal gallbladder walls without evidence of inflammatory criteria. Primarily anechoic content was present with mild hyperechoic nonshadowing,



**PATIENT**

Hayley Andrea

primarily dependent to mildly nondependent luminal debris. The common bile duct was normal. No evidence of peripheral gallbladder inflammation was noted.

***Gastrointestinal***

**SPECIES**

Canine

The stomach presented intact wall layering with a normal wall layer ratio. The lumen of the stomach was empty with no signs of ileus, obstruction, or foreign material. The gastric body wall width measured 0.4 cm.

**BREED**

Husky

The small intestine presented intact wall layering with 1:3 muscularis/mucosa ratio. The lumen of the small intestine was empty with no signs of ileus, obstruction, or foreign material. The duodenum wall measured 0.48 cm width. The jejunum wall measured 0.35 cm width.

**SEX**

FS

Normal visible colon wall layers were present with apparent formed feces in lumen.

***Pancreas***

**AGE**

16 years

The pancreas was normal in size and contour with heterogeneous, mildly hyperechoic parenchyma compared to adjacent omentum. No signs of active inflammation or neoplasia.

***Free Abdomen***

**WEIGHT**

36 lbs.

No omental masses, lymphadenopathy or peritoneal free fluid were present.

Potential spherical nonhomogeneous pancreatic vs. hepatic nodule was noted caudodorsal to the stomach measuring 2.54 cm. The nodule was not overtly consistent with neoplastic criteria with symmetrical contour.

**INTERPRETED BY**

R. McKenzie Daniel, DVM,  
 DABVP (Canine and  
 Feline)

**ULTRASONOGRAPHIC FINDINGS**

- Hepatopathy - subjectively acute or acute on chronic
- Mild hyperechoic gallbladder debris (non-mucocele) - no evidence of post hepatic obstruction
- Sonographically unremarkable gastrointestinal tract
- Mild pancreatic remodeling with potential mid pancreas nodule
- Bilateral mild chronic renal changes with minor pyelectasia and left kidney cortical cysts

**IMAGING**

**PERFORMED BY**

Pamela Harrigan, RDCS

**INTERPRETATION OF THE FINDINGS & FURTHER RECOMMENDATIONS**

**HOSPITAL NAME**

Wood River AH

The overall liver was nonspecific with potential considerations including vacuolar hepatopathy, suspected acute or acute on chronic hepatitis (viral/bacterial/Leptospirosis/toxin/etc.,) and nonobstructive cholestasis, while the possibility of occult neoplasia cannot be excluded. Further assessment of the liver may include ultrasound-guided FNA, assuming normal clotting status, and Leptospirosis titer/PCR.

**REFERRING VET**

Leah Fischer, DVM

**INVOICE**

14189

A GI panel to include PLI/TLI/Cobalamin/Folate as well as three view chest radiographs to rule out occult disease as a contributing factor to the patient's weight loss may be considered.

**DATE**

7/1/22

Hepatosupportive medications +/- empirical therapy for nonspecific hepatitis and gastrointestinal support would be reasonable. Further renal staging to include urine C/S and protein: creatinine ratio on sterile urine sample may be considered.



**PATIENT**

Hayley Andrea

**SPECIES**

Canine

**BREED**

Husky

**SEX**

FS

**AGE**

16 years

**WEIGHT**

36 lbs.

**INTERPRETED BY**

R. McKenzie Daniel, DVM,  
 DABVP (Canine and  
 Feline)

**IMAGING  
 PERFORMED BY**

Pamela Harrigan, RDCS

**HOSPITAL NAME**

Wood River AH

**REFERRING VET**

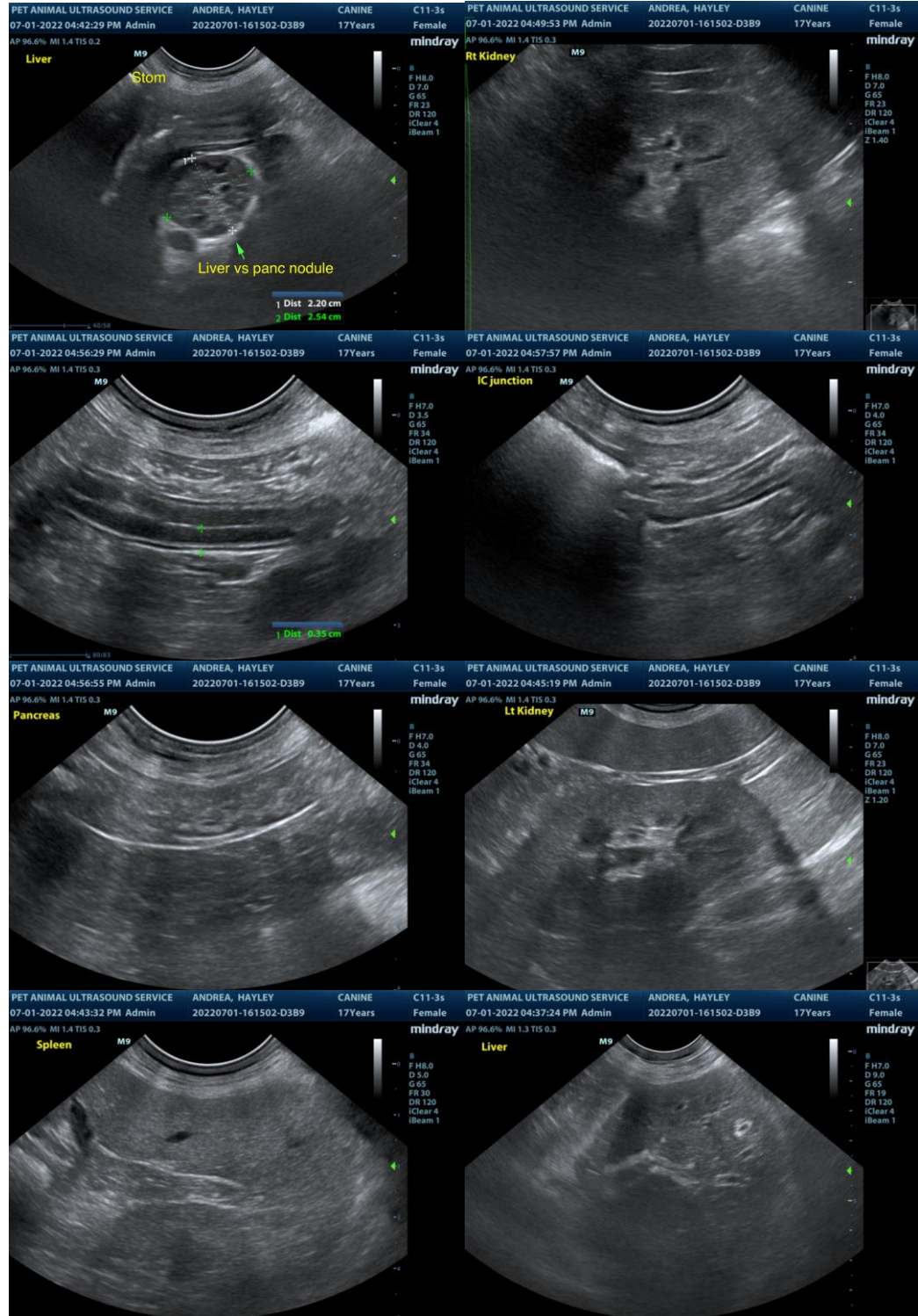
Leah Fischer, DVM

**INVOICE**

14189

**DATE**

7/1/22





**PATIENT**

Hayley Andrea

**SPECIES**

Canine

**BREED**

Husky

**SEX**

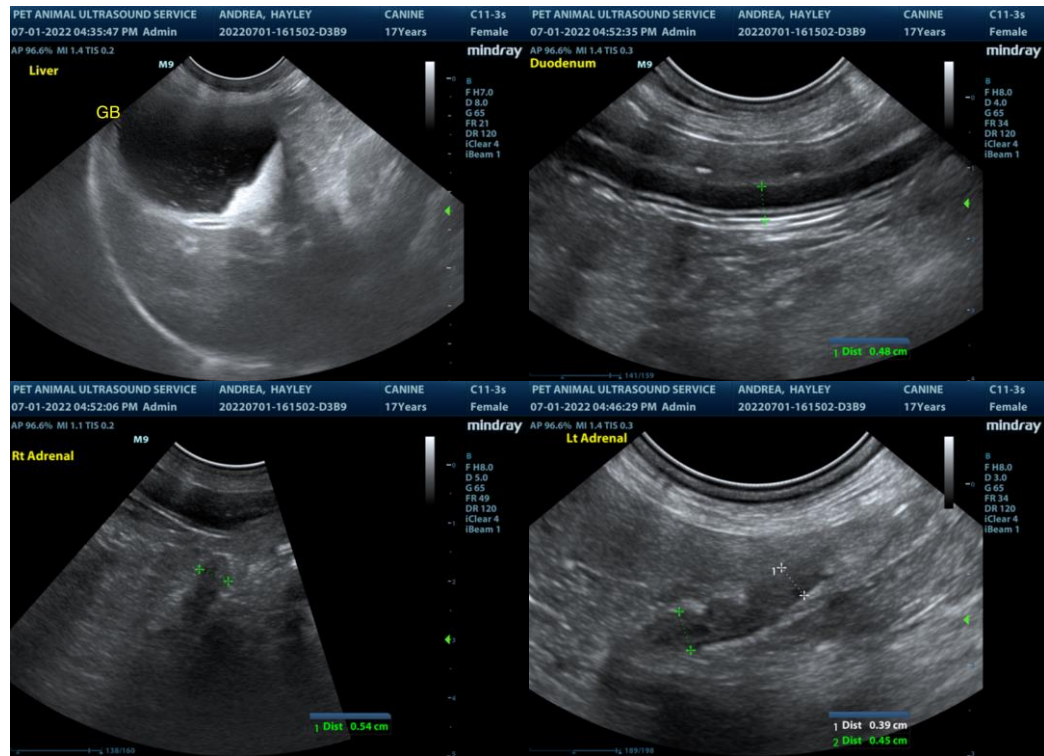
FS

**AGE**

16 years

**WEIGHT**

36 lbs.



**INTERPRETED BY**

R. McKenzie Daniel, DVM,  
 DABVP (Canine and  
 Feline)

**IMAGING**

**PERFORMED BY**

Pamela Harrigan, RDCS

**HOSPITAL NAME**

Wood River AH

**REFERRING VET**

Leah Fischer, DVM

**INVOICE**

14189

**DATE**

7/1/22

The information and recommendations provided are based on the images presented by the referring veterinarian/sonographer. No evaluation can be communicated regarding pathology that was not visible in the image/video clips provided.

Thank you for this referral. If the clinical or image interpretation does not parallel your findings or if I can be of any further assistance please contact me.

**R. McKenzie Daniel, DVM, DABVP (Canine / Feline Practice)**  
 info@SonoPath.com