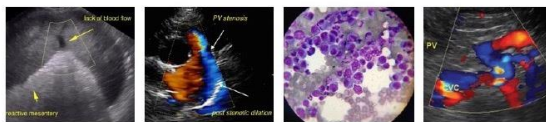




<b>PATIENT</b>	<b>PRESENTING CLINICAL SIGNS</b>
Clove Magathaes	Was in for routine spay surgery and found mass on ovarian ligament. Postponed surgery and booked ultrasound.
<b>SPECIES</b>	Abnormal PE/Chem/CBC/UA Results: Platelets high 473(143-448). CBC morphology normal. Rest of chemistry WNL.
Canine	
<b>BREED</b>	<b>ULTRASONOGRAPHIC EXAMINATION OF THE ABDOMEN</b>
Mini Schnauzer	<b>Urinary System</b>
<b>SEX</b>	The urinary bladder, trigone, cystourethral junction, and visible pelvic urethra to a depth of 2.0 cm exhibited normal thickness and tone. Anechoic urine was present in the lumen with no uroliths or sediment. The ureteral papillae were normal. The ureters were not visible which is normal. No evidence of inflammatory or neoplastic changes was noted.
FI	The left ovary was overtly normal in size, contour, and echogenicity measuring 0.7 cm in diameter. No overt pathology was noted in the area of the right ovary. Sonographic evaluation in the area of the left suspensory ligament and broad ligament revealed no overt evidence of pathology, including no sonographically evident mass lesions.
<b>AGE</b>	The uterus was sonographically normal, without evidence of pathology or luminal fluid accumulation.
18 months	The area of the aortic trifurcation was free of pathology.
<b>WEIGHT</b>	Normal size and margination were present in the kidneys. A normal 1:3 cortex / medulla ratio and normal corticomedullary definition were maintained. The echogenicity of the cortex was similar to or slightly less than normal liver parenchyma while the medulla echogenicity was hypoechoic to the cortex with no evidence of pelvic dilation. The left kidney measured 3.7 cm in length. The right kidney measured 3.6 cm in length.
4.7 kg	
<b>INTERPRETED BY</b>	<b>Adrenal Glands</b>
R. McKenzie Daniel, DVM, DABVP	The left adrenal gland was uniform in size and contour with a uniformly hypoechoic parenchyma. The left adrenal gland measured 0.28 cm width at the caudal pole and 0.44 cm width at the cranial pole. The right adrenal gland was uniform in size and contour with a uniformly hypoechoic parenchyma. The right adrenal gland measured 0.35 cm width at the caudal pole and 0.27 cm width at the cranial pole.
<b>IMAGING PERFORMED BY</b>	<b>Spleen</b>
Crystal Hill	The spleen was normal in size with a focal area of mid to cranial spleen lateral asymmetrical contour with associated nondisruptive hyperechoic nodular-like lesion. Normal splenic vascularity was present. The remainder of the spleen exhibited a finely textured homogeneous parenchyma.
<b>HOSPITAL NAME</b>	<b>Liver/ Gallbladder</b>
Sixteen Mile VC	The liver was subjectively normal in size, structure, and contour. The liver parenchyma was uniform and hypoechoic to the spleen with a mild coarse echotexture. The hepatic and portal vasculature were normal in appearance without signs of congestion. The gallbladder was non-distended in size with thin walls and primarily anechoic luminal content. The cystic and common bile ducts were normal.
<b>REFERRING VET</b>	
Dr. Gibbs	
<b>INVOICE</b>	
14050	
<b>DATE</b>	
6/8/22	



**PATIENT**

**Gastrointestinal**

Clove Magathaes

The stomach presented intact wall layering with a normal wall layer ratio. The lumen of the stomach was empty with no signs of ileus, obstruction, or foreign material.

**SPECIES**

Canine

The small intestine presented intact wall layering with 1:3 muscularis/mucosa ratio. The lumen of the small intestine was empty with no signs of ileus, obstruction, or foreign material.

**BREED**

Mini Schnauzer

Normal visible colon wall layers were present with apparent formed feces in lumen.

**SEX**

FI

**Pancreas**

The parenchyma of the left limb, body, and right limb of the pancreas presented isoechoic to the adjacent omental fat. A normal curvilinear capsule contour of the pancreas was present. The visible pancreatic duct was normal. No signs of active inflammation or neoplastic disease were evident.

**AGE**

18 months

**Free Abdomen**

No overt lymphadenopathy or peritoneal effusion was present.

**WEIGHT**

4.7 kg

**ULTRASONOGRAPHIC FINDINGS**

- Sonographically unremarkable bilateral ovaries, uterus, and surrounding structures - no overt evidence of a mass or lesion in the area of the left ovary
- Normal bilateral kidneys
- Possible focal mid to cranial lateral splenic infarct- incidental

**INTERPRETED BY**

R. McKenzie Daniel,  
DVM, DABVP

**INTERPRETATION OF THE FINDINGS & FURTHER RECOMMENDATIONS**

Sonographically, no evidence of pathology such as mass or nodular lesions in the area of the left ovary and surrounding ligament to structures. A uniform lesion isoechoic to surrounding omentum could be present and difficult to visualize with ultrasound. However, evidence of significant pathology in the area of the left kidney, left ovary, and left uterine horn was not overtly evident.

**IMAGING PERFORMED BY**

Crystal Hill

Ovariohysterectomy is recommended with close gross inspection in the area of the left ovary and surrounding structures. If the previously identified mass lesion is still present, biopsy or Ideally resection of the lesion for histopathology and definitive diagnosis is recommended.

**HOSPITAL NAME**

Sixteen Mile VC

**REFERRING VET**

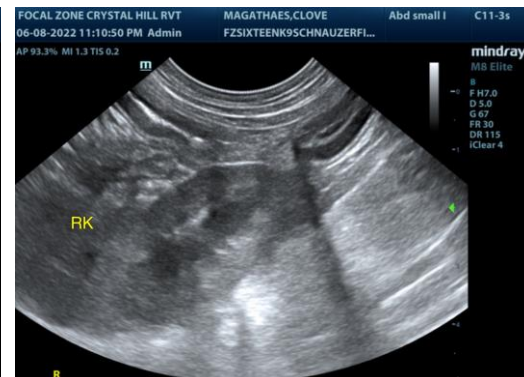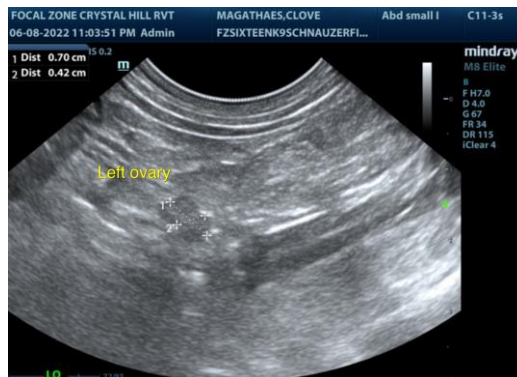Dr. Gibbs

**INVOICE**

14050

**DATE**

6/8/22





**PATIENT**

Clove Magathaes

**SPECIES**

Canine

**BREED**

Mini Schnauzer

**SEX**

FI

**AGE**

18 months

**WEIGHT**

4.7 kg

**INTERPRETED BY**

R. McKenzie Daniel,  
DVM, DABVP

**IMAGING  
PERFORMED BY**

Crystal Hill

**HOSPITAL NAME**

Sixteen Mile VC

**REFERRING VET**

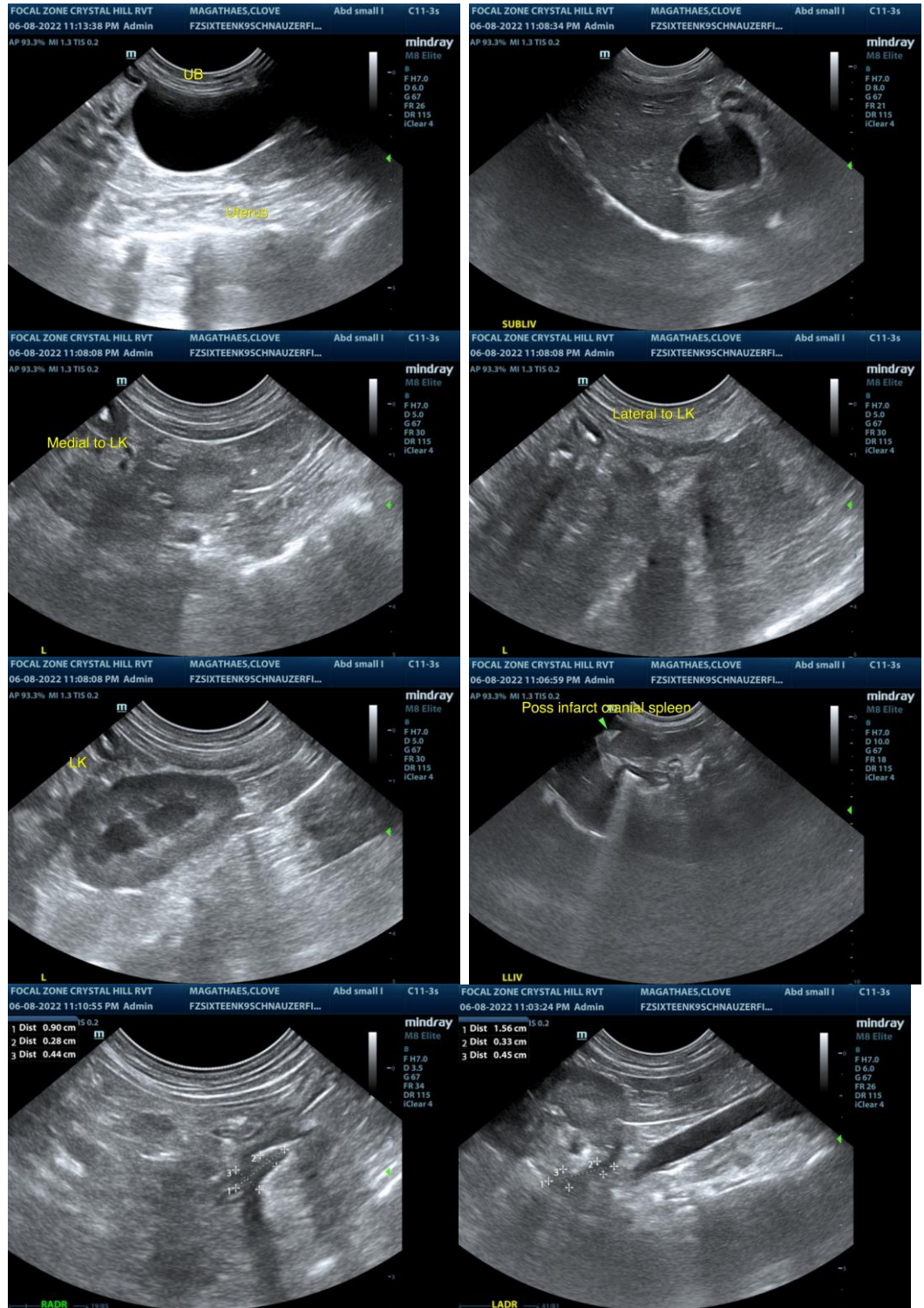
Dr. Gibbs

**INVOICE**

14050

**DATE**

6/8/22





**PATIENT**

Clove Magathaes

**SPECIES**

Canine

**BREED**

Mini Schnauzer

**SEX**

FI

**AGE**

18 months

**WEIGHT**

4.7 kg

**INTERPRETED BY**

R. McKenzie Daniel,  
DVM, DABVP

**IMAGING  
PERFORMED BY**

Crystal Hill

**HOSPITAL NAME**

Sixteen Mile VC

**REFERRING VET**

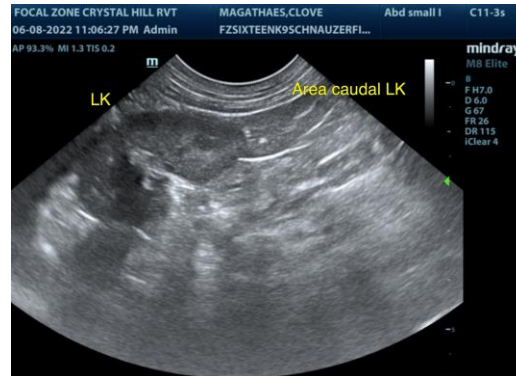Dr. Gibbs

**INVOICE**

14050

**DATE**

6/8/22



The information and recommendations provided are based on the images presented by the referring veterinarian/sonographer. No evaluation can be communicated regarding pathology that was not visible in the image/video clips provided.

Thank you for this referral. If the clinical or image interpretation does not parallel your findings or if I can be of any further assistance please contact me.

**R. McKenzie Daniel, DVM, DABVP (Canine / Feline Practice)**  
info@SonoPath.com