



PATIENT

Rhino Otero

SPECIES

Canine

BREED

Pit Bull

SEX

MN

AGE

13

WEIGHT

25kg

INTERPRETED BY

R. McKenzie Daniel,
DVM, DABVP
(Canine and Feline)

IMAGING PERFORMED BY

Abby Gerenser

HOSPITAL NAME

ABBY ROAD
VETERINARY

REFERRING VET

Ashley Tichy

INVOICE

25023

DATE

06/07/2026

PRESENTING CLINICAL SIGNS

Rhino is a neutered male Pit Bull presenting for a pre-dental evaluation. Chronic issues include dental disease with gingival swelling, cutaneous masses, muscle mass loss, and chronic nasal hyperkeratosis. The patient is maintained on a hydrolyzed protein diet (Purina HA) and is not currently receiving flea/tick or heartworm preventives.

Abnormal PE/Chem/CBC/UA Results: See attached file of BW and radiographs. BW showed mild hypoalbuminemia, mild proteinuria, and a low-normal total T4, and mild anemia. Heartworm and tick-borne disease testing was negative. PE: Dry nasal planum, no discharge Oral: Moderate amount of tartar, worn down teeth, swelling of gums around right canine tooth with pocket formation containing hair and food debris Heart: Grade 2/6 heart murmur Musculoskeletal: Prominent spine, decreased muscle mass

ULTRASONOGRAPHIC EXAMINATION OF THE ABDOMEN

Urinary System

The urinary bladder, trigone, cystourethral junction, and visible pelvic urethra to a depth of 3 cm exhibited normal thickness and tone. Anechoic urine was present in the lumen with no evidence of urine/lumen sediment, mineral, or calculi. The ureteral papillae were normal. The ureters were not visible, which is normal. No evidence of inflammatory or neoplastic changes was noted.

Normal size and margination were present in the kidneys. A normal 1:3 cortex / medulla ratio was maintained. The medulla and cortices were uniform in texture with some increased echogenicity and moderate loss of corticomedullary symmetry and definition expected for the age of the patient. No evidence of pelvic dilation was present. The left kidney measured – cm in length. The right kidney measured – cm in length.

No obvious pathology visualized in the area of the residual prostate.

Adrenal Glands

The left adrenal gland was not definitively visualized. Mild parenchyma heterogeneity and mild capsule asymmetry was present without suspicion for overt neoplasia. The left adrenal gland measured 0.78 cm at the caudal pole subjectively. The right adrenal gland was not definitively visualized.

Spleen

The spleen exhibited normal size and contour. Mild heterogeneous splenic parenchyma exhibiting solitary to possible intermittent subtle hypoechoic non-capsule deforming nodules was present. An example of a splenic nodule measured 2.0 cm in diameter.

Liver/Gallbladder

The liver was subjectively normal in size, structure, and contour. The liver parenchyma was uniform and hypoechoic to the spleen with a mild coarse echotexture. Normal vascular volume. The hepatic and portal vasculature were normal in appearance without signs of congestion. The gallbladder was non-distended in size with thin walls and mild non-organized debris. The cystic and common bile ducts were normal.

Gastrointestinal



PATIENT

Rhino Otero

The stomach presented intact wall layering with a normal wall layer ratio. The lumen of the stomach contained mild non-shadowing to progressively shadowing ingesta sonographically suggestive of food echogenicity with no signs of obstruction or foreign material.

SPECIES

Canine

The small intestine presented overall intact wall layering with primarily maintained muscularis/mucosa ratio. Propensity for segmental mildly prominent small intestine muscularis layer subjectively. The duodenum wall measured 0.58 cm width. The jejunum wall measured 0.54 cm width.

Normal visible colon wall layers were present with semi formed feces in lumen.

BREED

Pancreas

Pit Bull

The area of the pancreas was sonographically normal.

Free Abdomen

SEX

No evidence of peritoneal effusion was present.

MN

Intermittent mildly prominent to enlarged jejunal and medial iliac lymph nodes were present. The lymph nodes were essentially isoechoic to adjacent omentum without evidence of peripheral inflammation and maintaining a normal width: length ratio (<0.5). An example measured 2.3 cm x 0.89 cm.

AGE

13

ULTRASONOGRAPHIC FINDINGS

WEIGHT

25kg

Primary

- Bilateral chronic renal changes
- Subtle splenic nodule
- Mild non-shadowing to progressively shadowing gastric ingesta
- Possible non-specific chronic enteropathy
- Intermittent mild jejunal / medial iliac lymphadenopathy

INTERPRETED BY

R. McKenzie Daniel,
DVM, DABVP
(Canine and Feline)

INTERPRETATION OF THE FINDINGS & FURTHER RECOMMENDATIONS

IMAGING PERFORMED BY

Abby Gerenser

Given no significant proteinuria or hepatic disease, underlying non-specific potentially chronic intestinal disease as a primary cause of the subnormal ALB level is favored. A GI panel to include PLI/TLI/Cobalamin/Folate is recommended.

HOSPITAL NAME

ABBY ROAD
VETERINARY

The subtle splenic nodule is non-specific with considerations including nodular to generalized incidental hyperplasia, hematopoiesis suspected with mild potential for emerging splenic neoplasia not definitively excluded. Assuming normal clotting status and using 25ga needle, splenic FNA cytology warranted to assess for occult disease if evidence of weight loss.

REFERRING VET

Ashley Tichy

Correlation with neurological and musculoskeletal exam is recommended. No overt abdominal anesthetic contraindications.

INVOICE

25023

DATE

06/07/2026



PATIENT

Rhino Otero

SPECIES

Canine

BREED

Pit Bull

SEX

MN

AGE

13

WEIGHT

25kg

INTERPRETED BY

R. McKenzie Daniel,
DVM, DABVP
(Canine and Feline)

IMAGING PERFORMED BY

Abby Gerenser

HOSPITAL NAME

ABBY ROAD
VETERINARY

REFERRING VET

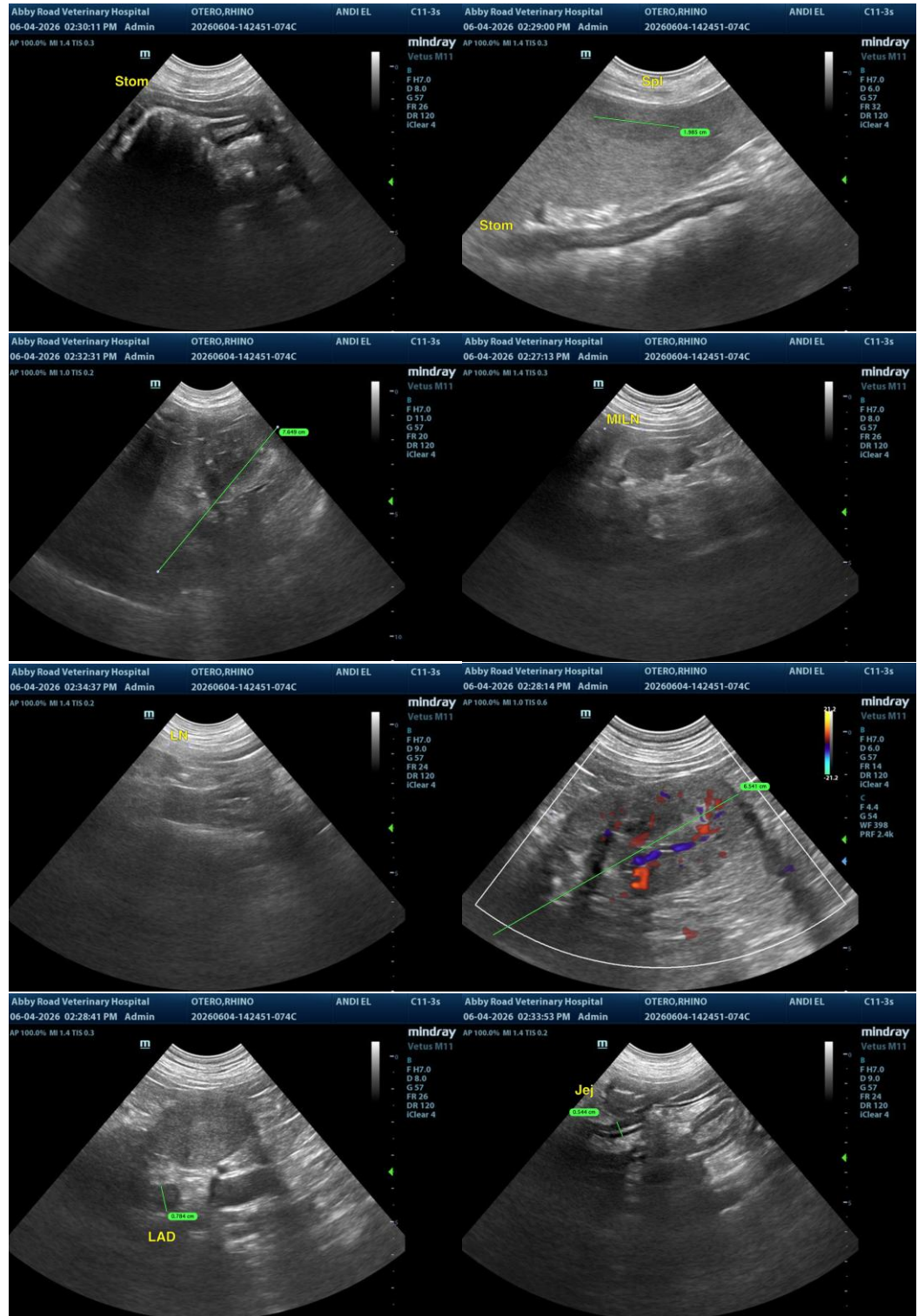
Ashley Tichy

INVOICE

25023

DATE

06/07/2026





PATIENT

Rhino Otero

SPECIES

Canine

BREED

Pit Bull

SEX

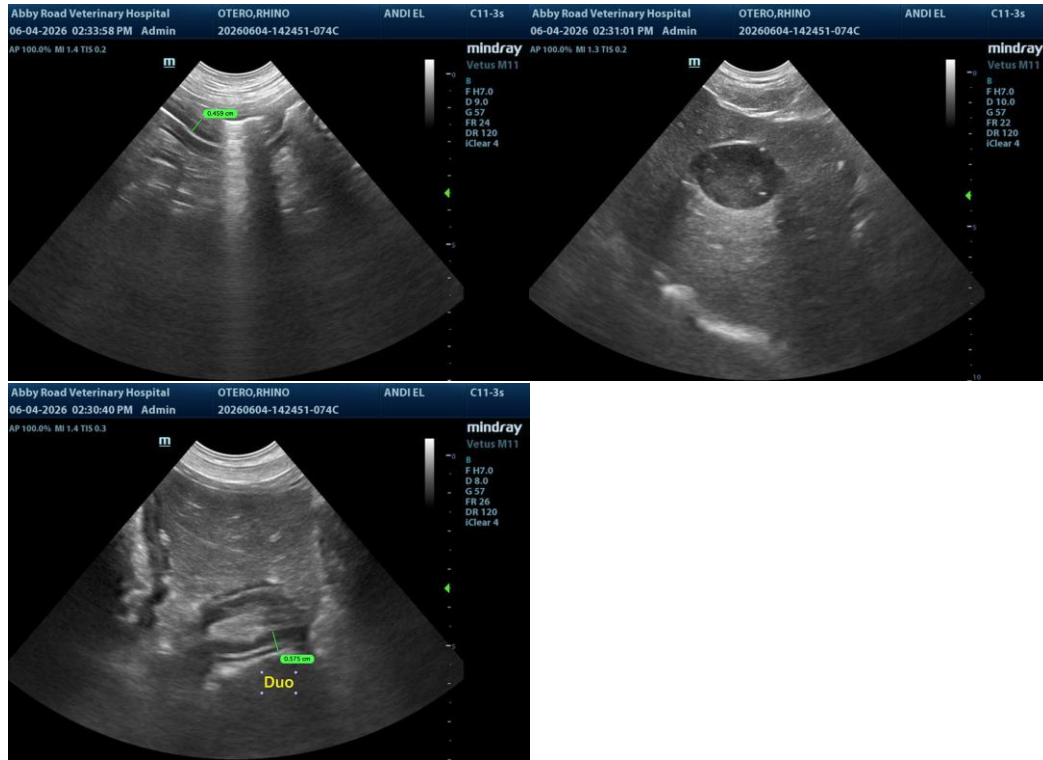
MN

AGE

13

WEIGHT

25kg



INTERPRETED BY

R. McKenzie Daniel,
DVM, DABVP
(Canine and Feline)

IMAGING PERFORMED BY

Abby Gerenser

HOSPITAL NAME

ABBY ROAD
VETERINARY

REFERRING VET

Ashley Tichy

INVOICE

25023

DATE

06/07/2026

The information and recommendations provided are based on the images presented by the referring veterinarian/sonographer. No evaluation can be communicated regarding pathology that was not visible in the image/video clips provided.

Thank you for this referral. If the clinical or image interpretation does not parallel your findings or if I can be of any further assistance, please contact me.

R. McKenzie Daniel, DVM, DABVP (Canine/Feline Practice)
info@sonopath.com