



**PATIENT**

Vito Kallhoff

**SPECIES**

Feline

**BREED**

DSH

**SEX**

Intact Male

**AGE**

10 Months

**WEIGHT**

10.8 Pounds

**INTERPRETED BY**

R. McKenzie Daniel,  
DVM, DABVP  
(Canine and Feline)

**IMAGING PERFORMED BY**

Rachel Runnells, RVT

**HOSPITAL NAME**

SVS Imaging KC

**REFERRING VET**

Dr. Kristine Mulloy

**INVOICE**

15918

**DATE**

6/6/22

**PRESENTING CLINICAL SIGNS**

History: Presented on 5/9/22 for shaking/high fever. E/D okay, no V/D. Had two rounds of kitten vax/deworming. Patient came back in 4 more times with high fever after trying antibiotics and fluids. Patient went to ER 5/12/22 for IV fluids, IV antibiotics, and IV steroids. Was tested for FEVER UNKNOWN ORIGIN, results were WNL.

Abnormal PE/Chem/CBC/UA Results: We took abdominal radiographs on 5/24/22 = mild diffuse bronchial pattern (most consistent with infection bronchitis), ill-defined partially mineralized structure caudal to left kidney on VD view, small amount of heterogenous soft tissue material in stomach. All visits from 5/9/22 - 5/24/22 patient has had temps between 103.1-103.7 F. Exam= WNL, except elevated temp. Combo test (FIV/FELUK/HWT) = negative. (5/9/22) CBC/CHEM = WNL (5/11/22) Fecal = WNL (5/11/22) U/A = WNL (5/11/22)

**ULTRASONOGRAPHIC EXAMINATION OF THE ABDOMEN**

**Urinary System**

The urinary bladder, trigone, cystourethral junction, and visible pelvic urethra to a depth of 2.0 cm exhibited normal thickness and tone. Primarily anechoic urine was present in the lumen. Mild nondependent particulate sediment was present without evidence of calculus formation. The ureteral papillae were normal. The ureters were not visible which is normal. No evidence of inflammatory urinary bladder mural criteria. Aortic trifurcation was normal. No evidence of medial iliac or sublumbar lymphadenopathy.

Normal size and margination was present in the kidneys. A normal 1:3 cortex / medulla ratio and normal corticomedullary definition were maintained. The echogenicity of the cortex was similar to or slightly less than normal liver parenchyma while the medulla echogenicity was hypoechoic to the cortex with no evidence of pelvic dilation. A hyperechoic corticomedullary band, consistent with a prominent to hyperechoic medullary rim sign, was present in both kidneys. This is a nonspecific finding seen in both normal and abnormal kidneys. It may be associated interstitial renal disease, hypercalcemia, tubular necrosis, lymphoma, and FIP. However, it is a nonspecific finding. The left kidney measured 4.6 cm. The right kidney measured 4.6 cm.

**Adrenal Glands**

The left adrenal gland was uniform in size and contour with a uniformly hypoechoic parenchyma. The left adrenal gland measured 0.42 cm.

The right adrenal gland was uniform in size and contour with a uniformly hypoechoic parenchyma. The right adrenal gland measured 0.52 cm.

**Spleen**

The spleen was borderline enlarged, measuring 1.0 cm in width at the level of the hilus. Maintained symmetrical capsule contour and primarily finely textured homogeneous parenchyma noted. No intraparenchymal masses or nodules noted. Splenic vascularity was normal.

**Liver**

The liver was subjectively normal in size, structure, and contour. The liver parenchyma was uniform and hypoechoic to the spleen with a mild coarse echotexture. The hepatic and portal vasculature were normal in appearance without signs of congestion. The gallbladder was non-distended in size with thin walls and primarily anechoic luminal content. The cystic and common bile ducts were normal.



**PATIENT**

***Gastrointestinal***

Vito Kallhoff

The stomach presented intact wall layering with a normal wall layer ratio. The lumen of the stomach was empty with no signs of ileus, obstruction or foreign material.

**SPECIES**

Feline

The small intestine presented intact wall layering with 1:3 muscularis/mucosa ratio. The lumen of the small intestine was empty with no signs of ileus, obstruction or foreign material.

Normal visible colon wall layers were present with apparent formed feces in lumen.

**BREED**

***Pancreas***

DSH

The parenchyma of the left limb, body and right limb of the pancreas presented isoechoic to the adjacent omental fat. A normal curvilinear capsule contour of the pancreas was present. The visible pancreatic duct was normal. No signs of active inflammation or neoplastic disease was evident.

**SEX**

Intact Male

***Free Abdomen***

**AGE**

10 Months

A solitary small to spherical area of mineralization, exhibiting distal acoustic shadowing was present directly adjacent to the caudolateral spleen and in the area of the left kidney, measuring approximately 0.71 cm in diameter.

No omental masses, lymphadenopathy or evidence of peritoneal effusion.

**WEIGHT**

10.8 Pounds

**ULTRASONOGRAPHIC FINDINGS**

- Urinary bladder sediment
- Bilateral nonspecific yet prominent renal medullary rim sign
- Borderline splenomegaly
- Focal small to spherical area of mineralization in the left abdomen adjacent to or possible involving the caudal spleen- nonspecific, suspect focal area of nodular fat necrosis or bates body, potential for mineralized splenic nodule or previous splenic infarct. The mineralized nodule was not overtly consistent with neoplastic criteria.
- Otherwise sonographically normal abdomen

**INTERPRETED BY**

R. McKenzie Daniel,  
DVM, DABVP  
(Canine and Feline)

**IMAGING PERFORMED BY**

Rachel Runnells, RVT

**HOSPITAL NAME**

SVS Imaging KC

**REFERRING VET**

Dr. Kristine Mulloy

**INVOICE**

15918

**DATE**

6/6/22

**INTERPRETATION OF THE FINDINGS & FURTHER RECOMMENDATIONS**

The etiologies for the focal spherical area of mineralization, adjacent to or possible involving the spleen, is nonspecific yet suspected to be incidental. Overall, a definitive cause of the patients fever and clinical signs was not definitively evident. No evidence of peritoneal effusion or overt peritonitis.

Although the borderline splenomegaly is nonspecific, potential ultrasound guided splenic FNA, using a 25-gauge needle, and assuming normal clotting status, could be considered primarily to ensure only benign changes, i.e., hyperplasia, hematopoiesis, etc., are present. Given the lack of significant abdominal visceral pathology yet persistent fever, expanded infectious disease testing, which may potentially include toxoplasma or FIP, given the presence of the nonspecific renal medullary rim sign could be considered. Continued as needed supportive care is recommended.



**PATIENT**

Vito Kallhoff

**SPECIES**

Feline

**BREED**

DSH

**SEX**

Intact Male

**AGE**

10 Months

**WEIGHT**

10.8 Pounds

**INTERPRETED BY**

R. McKenzie Daniel,  
DVM, DABVP  
(Canine and Feline)

**IMAGING PERFORMED BY**

Rachel Runnells, RVT

**HOSPITAL NAME**

SVS Imaging KC

**REFERRING VET**

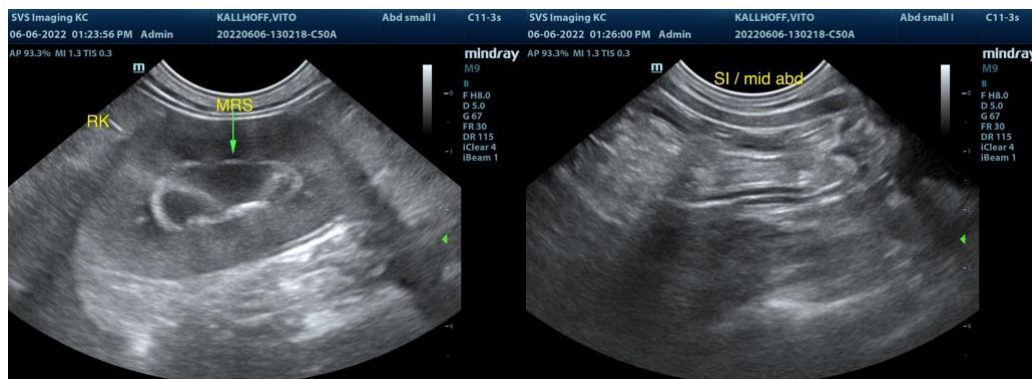
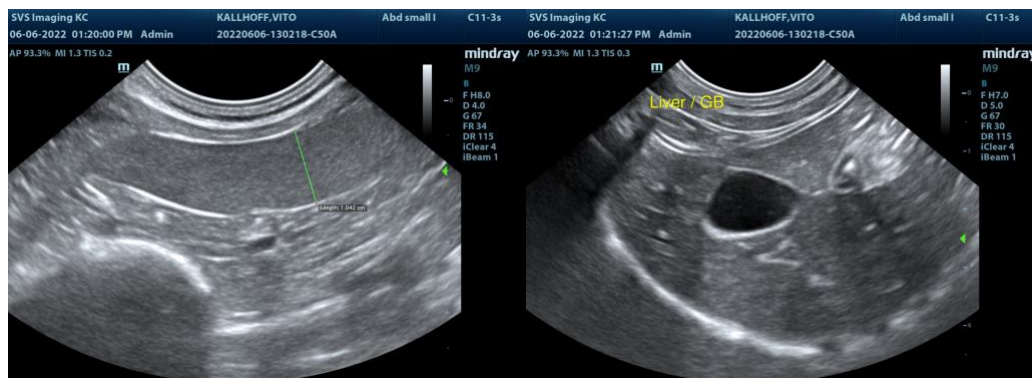
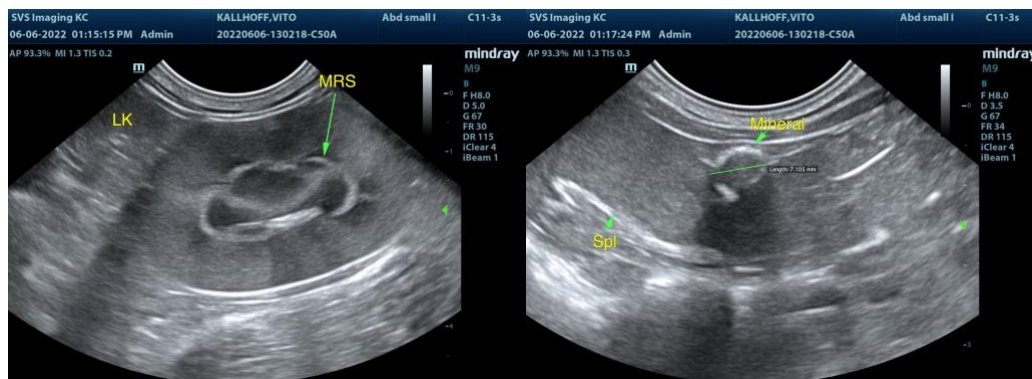
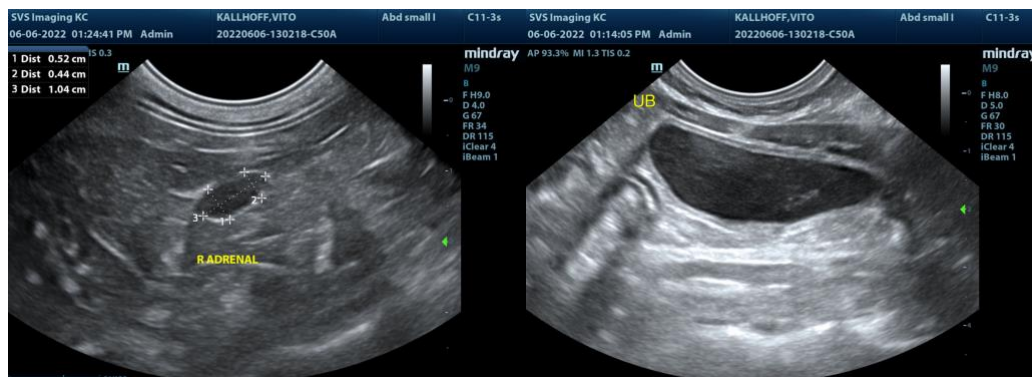
Dr. Kristine Mulloy

**INVOICE**

15918

**DATE**

6/6/22





**PATIENT**

Vito Kallhoff

The information and recommendations provided are based on the images presented by the referring veterinarian. No evaluation can be communicated regarding pathology that was not visible in the image/video clips provided.

**SPECIES**

Feline

Thank you for this referral. If the clinical or image interpretation does not parallel your findings or if I can be of any further assistance please contact me.

**BREED**

DSH

**R. McKenzie Daniel, DVM, DABVP (Canine / Feline Practice)**  
info@SonoPath.com

**SEX**

Intact Male

**AGE**

10 Months

**WEIGHT**

10.8 Pounds

**INTERPRETED BY**

R. McKenzie Daniel,  
DVM, DABVP  
(Canine and Feline)

**IMAGING  
PERFORMED BY**

Rachel Runnells, RVT

**HOSPITAL NAME**

SVS Imaging KC

**REFERRING VET**

Dr. Kristine Mulloy

**INVOICE**

15918

**DATE**

6/6/22