

PATIENT

Theo Ruzzi

SPECIES

Canine

BREED

Rottweiler

SEX

M

AGE

6 years

WEIGHT

103

INTERPRETED BY

R. McKenzie Daniel,
DVM, DABVP
(Canine and Feline)

IMAGING PERFORMED BY

Allison Gomer

HOSPITAL NAME

Shohola VH

REFERRING VET

Dr. Livia Demeo

INVOICE

10956

DATE

6/4/56

PRESENTING CLINICAL SIGNS

Different hospital treated prostate infection in April. X-ray indicated prostate enlargement. Intact male. Treated and urine came back normal. Owner requesting prostate check on ultrasound. On palpation prostate felt normal.

The submitted study contained 7 images, primarily of the prostate.

LIMITED ULTRASONOGRAPHIC EXAMINATION OF THE PROSTATE

The visible caudal urinary bladder and the area of the cystourethral junction were free of pathology.

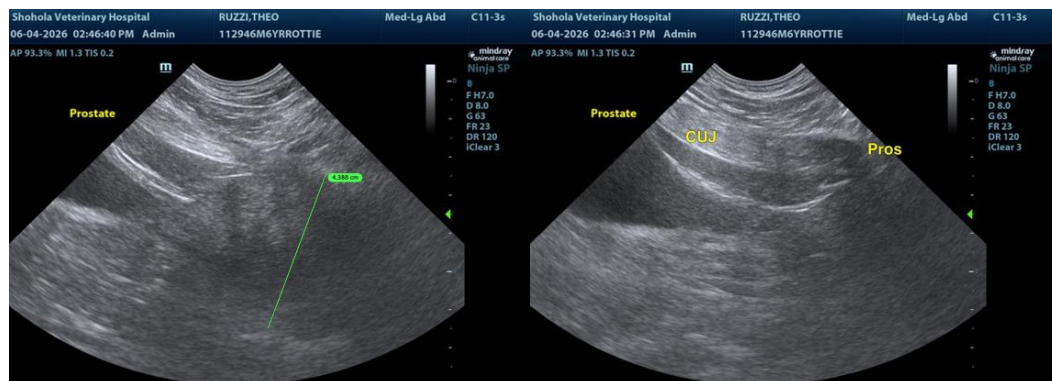
The prostate was enlarged in size with an intact, symmetrical capsule contour. The margins of the gland were intact and able to be differentiated from the surrounding tissue. The prostatic parenchyma was mildly echogenic to heteroechoic without parenchymal mineralization. The prostate measured 4.4 cm in diameter.

ULTRASONOGRAPHIC FINDINGS

- Mildly enlarged nonhomogeneous nonmineralized prostate – consistent with benign prostatic hyperplasia, potential for resolved or low-grade prostatitis

INTERPRETATION OF THE FINDINGS & FURTHER RECOMMENDATIONS

There is no evidence of prostatic or visible urinary bladder neoplastic criteria. Continued Monitoring for evidence of prostatic discomfort on palpation and urinalysis, if clinical signs consistent with lower urinary tract or prostatic disease are noted, is recommended. Neutering, if the patient is not intended for breeding purposes, is suggested to minimize the potential for recurrent or future prostatic pathology.



The information and recommendations provided are based on the images presented by the referring veterinarian/sonographer. No evaluation can be communicated regarding pathology that was not visible in the image/video clips provided.



PATIENT

Theo Ruzzi

Thank you for this referral. If the clinical or image interpretation does not parallel your findings or if I can be of any further assistance, please contact me.

SPECIES

Canine

R. McKenzie Daniel, DVM, DABVP (Canine/Feline Practice)

info@sonopath.com

BREED

Rottweiler

SEX

M

AGE

6 years

WEIGHT

103

INTERPRETED BY

R. McKenzie Daniel,
DVM, DABVP
(Canine and Feline)

IMAGING PERFORMED BY

Allison Gomer

HOSPITAL NAME

Shohola VH

REFERRING VET

Dr. Livia Demeo

INVOICE

10956

DATE

6/4/56