

**PATIENT**

Westley Ricjardson

SPECIES

Canine

BREED

Lab Mix

SEX

NM

AGE

5 years

WEIGHT

72 lbs.

INTERPRETED BY

R. McKenzie Daniel,
DVM, DABVP
(Canine and Feline)

IMAGING PERFORMED BY

Sarah Pender, CVT

HOSPITAL NAME

SVS Imaging QC

REFERRING VET

Dr. Sydney Schermer

INVOICE

14164

DATE

6/30/22

PRESENTING CLINICAL SIGNS

routine physical exam- had a brief episode of loss of appetite last summer no other GI signs now
Abnormal PE/Chem/CBC/UA Results: no abnormal findings doing as a precaution- check for cancer

ULTRASONOGRAPHIC EXAMINATION OF THE ABDOMEN**Urinary System**

The urinary bladder, trigone, cystourethral junction, and visible pelvic urethra to a depth of 4.0 cm exhibited normal thickness and tone. Anechoic urine was present in the lumen with no uroliths or sediment. The ureteral papillae were normal. The ureters were not visible which is normal. No evidence of inflammatory or neoplastic changes was noted.

The residual prostate was symmetrically normal in size with uniform parenchyma and slight coarse echotexture measuring 0.7 cm in diameter.

The area of the aortic trifurcation was free of pathology.

Normal size and margination were present in the kidneys. A normal 1:3 cortex / medulla ratio and normal corticomedullary definition were maintained. The echogenicity of the cortex was similar to or slightly less than normal liver parenchyma while the medulla echogenicity was hypoechoic to the cortex with no evidence of pelvic dilation. The left kidney measured 5.8 cm in length. The right kidney measured 6.5 cm in length.

Adrenal Glands

The left adrenal gland was uniform in size and contour with a uniformly hypoechoic parenchyma. The left adrenal gland measured 2.8 cm length x 0.85 cm width at the caudal pole. The right adrenal gland was uniform in size and contour with a uniformly hypoechoic parenchyma. The right adrenal gland measured 2.4 cm length x 0.75 cm width at the caudal pole.

Spleen

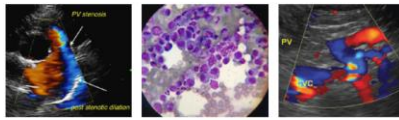
The spleen exhibited a finely textured and homogenous parenchyma which was hyperechoic to the liver and renal cortical parenchyma. The capsule was smooth and regular without apparent expansion. The splenic vasculature at the hilus was normal in volume with no evidence of congestion or thrombosis. Acute to chronic inflammatory, neoplastic, or benign parenchyma changes were not noted.

Liver/ Gallbladder

The liver was subjectively normal in size, structure, and contour. The liver parenchyma was uniform and hypoechoic to the spleen with a mild coarse echotexture. The hepatic and portal vasculature were normal in appearance without signs of congestion. The gallbladder was non-distended in size with thin walls and primarily anechoic luminal content. The cystic and common bile ducts were normal.

Gastrointestinal

The stomach presented intact wall layering with a normal wall layer ratio. Mild nonshadowing ingesta / chyme was present. The ventral gastric body wall width measured 0.42 cm.



PATIENT

Westley Ricjardson

The small intestine presented intact wall layering with 1:3 muscularis/mucosa ratio. The lumen of the small intestine was empty with no signs of ileus, obstruction, or foreign material. The duodenum wall width measured 0.44 cm.

SPECIES

Canine

Normal visible colon wall layers were present with apparent formed feces in lumen.

BREED

Lab Mix

Pancreas

The parenchyma of the left limb, body, and right limb of the pancreas presented isoechoic to the adjacent omental fat. A normal curvilinear capsule contour of the pancreas was present. The visible pancreatic duct was normal. No signs of active inflammation or neoplastic disease were evident.

SEX

NM

Free Abdomen

No overt lymphadenopathy or peritoneal effusion was present.

AGE

5 years

ULTRASONOGRAPHIC FINDINGS

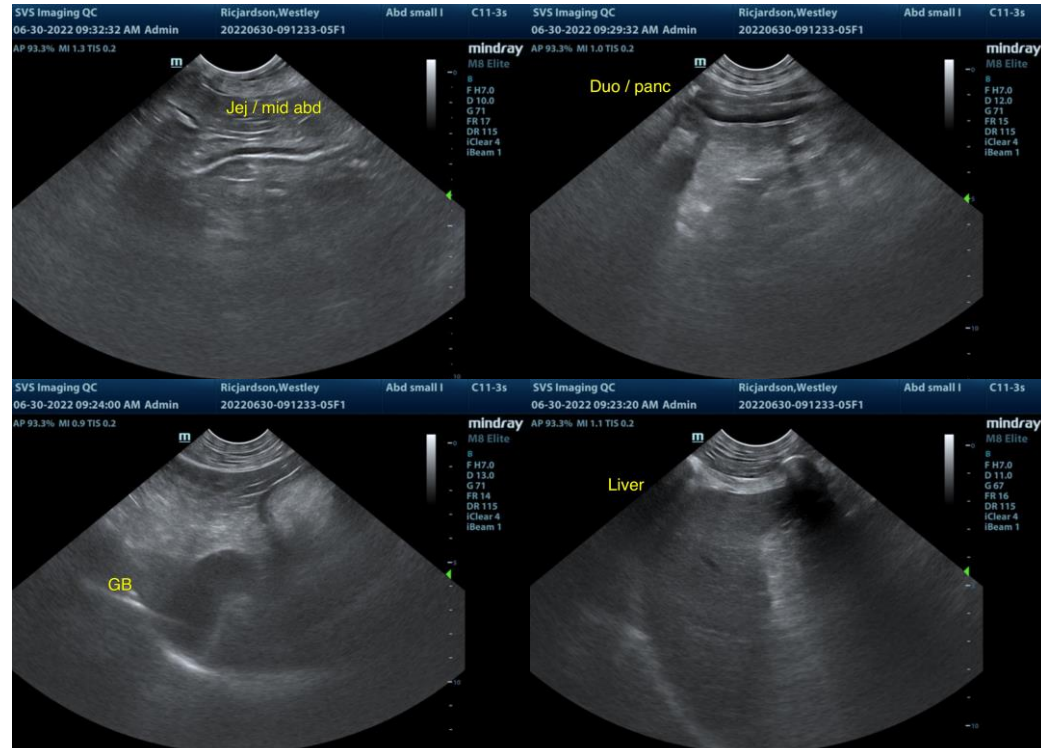
- Sonographically unremarkable abdomen

INTERPRETATION OF THE FINDINGS & FURTHER RECOMMENDATIONS

No evidence of abdominal visceral pathology was evident.

WEIGHT

72 lbs.



INTERPRETED BY

R. McKenzie Daniel,
 DVM, DABVP
 (Canine and Feline)

IMAGING PERFORMED BY

Sarah Pender, CVT

HOSPITAL NAME

SVS Imaging QC

REFERRING VET

Dr. Sydney Schermer

INVOICE

14164

DATE

6/30/22



PATIENT

Westley Ricjardson

SPECIES

Canine

BREED

Lab Mix

SEX

NM

AGE

5 years

WEIGHT

72 lbs.

INTERPRETED BY

R. McKenzie Daniel,
 DVM, DABVP
 (Canine and Feline)

IMAGING PERFORMED BY

Sarah Pender, CVT

HOSPITAL NAME

SVS Imaging QC

REFERRING VET

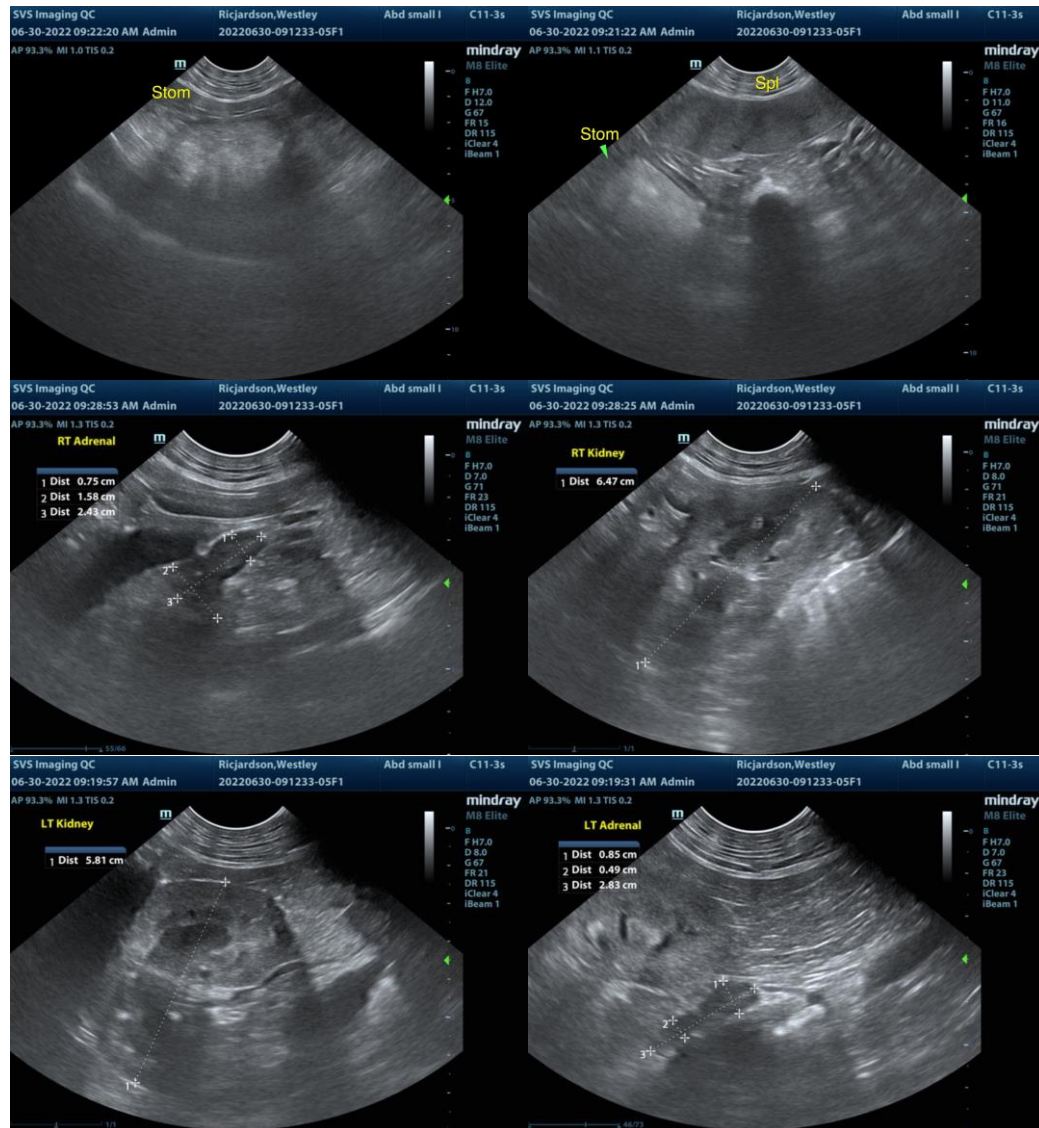
Dr. Sydney Schermer

INVOICE

14164

DATE

6/30/22



The information and recommendations provided are based on the images presented by the referring veterinarian/sonographer. No evaluation can be communicated regarding pathology that was not visible in the image/video clips provided.

Thank you for this referral. If the clinical or image interpretation does not parallel your findings or if I can be of any further assistance please contact me.

R. McKenzie Daniel, DVM, DABVP (Canine / Feline Practice)
 info@SonoPath.com