



PATIENT

Dolly Ordaz

SPECIES

Canine

BREED

German Shorthair
Pointer

SEX

Female Spayed

AGE

18 months

WEIGHT

32 lbs.

INTERPRETED BY

R. McKenzie Daniel,
DVM, DABVP
(Canine and Feline)

**IMAGING
PERFORMED BY**

Dr. Sam Doverspike

HOSPITAL NAME

Frankling AC Inc.

REFERRING VET

Dr. Sam Doverspike

INVOICE

14166

DATE

6/30/22

PRESENTING CLINICAL SIGNS

Hx of weight loss over several weeks. Some change in behavior.

Abnormal PE/Chem/CBC/UA Results: General Chemistry/CBC: Normal Cortisol, TLI, Cobalamine all normal. Fecal Negative (and also dewormed w/ Panacur) Diarrhea panel was normal

ULTRASONOGRAPHIC EXAMINATION OF THE ABDOMEN

Urinary System

The urinary bladder, trigone, and cystourethral junction exhibited normal thickness and tone. Anechoic urine was present in the lumen with no uroliths or sediment. The ureteral papillae were normal. The ureters were not visible which is normal. No evidence of inflammatory or neoplastic changes was noted.

The area of the aortic trifurcation was free of pathology.

Normal size and margination were present in the kidneys. A normal 1:3 cortex / medulla ratio and normal corticomedullary definition were maintained. The echogenicity of the cortex was similar to or slightly less than normal liver parenchyma while the medulla echogenicity was hypoechoic to the cortex with no evidence of pelvic dilation. The left kidney measured 5.5 cm in length. The right kidney measured 5.7 cm in length.

Adrenal Glands

The left adrenal gland was uniform in size and contour with a uniformly hypoechoic parenchyma. The left adrenal gland measured 0.43 cm width at the caudal pole and 0.44 cm width at the cranial pole. The right adrenal gland was uniform in size and contour with a uniformly hypoechoic parenchyma. The right adrenal gland measured 0.46 cm width at the caudal pole.

Spleen

The spleen exhibited a finely textured and homogenous parenchyma which was hyperechoic to the liver and renal cortical parenchyma. The capsule was smooth and regular without apparent expansion. The splenic vasculature at the hilus was normal in volume with no evidence of congestion or thrombosis. Acute to chronic inflammatory, neoplastic, or benign parenchyma changes were not noted.

Liver/ Gallbladder

The liver was subjectively normal in size, structure, and contour. The liver parenchyma was uniform and hypoechoic to the spleen with a mild coarse echotexture. The hepatic and portal vasculature were normal in appearance without signs of congestion. The gallbladder was non-distended in size with thin walls and primarily anechoic luminal content. The cystic and common bile ducts were normal.

Gastrointestinal

The stomach presented intact wall layering with a normal wall layer ratio. The lumen of the stomach was empty with no evidence of retained Ingesta, fluid or foreign material with mild luminal gas. The ventral gastric body wall width measured 0.49 cm.



PATIENT

Dolly Ordaz

The small intestine presented intact wall layering with 1:3 muscularis/mucosa ratio. The lumen of the small intestine was empty with no signs of mechanical / metabolic small intestinal ileus or foreign material. The duodenum wall measured 0.49 cm width. The jejunum wall measured 0.37 cm width.

SPECIES

Canine

Normal visible colon wall layers were present with subjective semi-formed fecal matter in lumen.

Pancreas

BREED

German Shorthair Pointer

The parenchyma of the left limb, body, and right limb of the pancreas presented isoechoic to the adjacent omental fat. A normal curvilinear capsule contour of the pancreas was present. The visible pancreatic duct was normal. No signs of active inflammation or neoplastic disease were evident.

SEX

Female Spayed

Free Abdomen

AGE

18 months

Solitary ventral abdominal mesenteric lymph node was present. The lymph node was essentially isoechoic to adjacent omentum without evidence of peripheral inflammation and maintaining a normal width: length ratio (<0.5). The lymph node measured 1.6 cm x 0.5 cm. This lymph node was not consistent with inflammatory or neoplastic criteria and suggestive of minor benign lymphoid hyperplasia. No omental masses, significant lymphadenopathy or peritoneal free fluid were evident.

WEIGHT

32 lbs.

ULTRASONOGRAPHIC FINDINGS

- Sonographically unremarkable abdomen

INTERPRETED BY

R. McKenzie Daniel, DVM, DABVP (Canine and Feline)

INTERPRETATION OF THE FINDINGS & FURTHER RECOMMENDATIONS

No evidence of abdominal visceral pathology, specifically gastrointestinal pathology, as an obvious cause of the patient's recent weight loss.

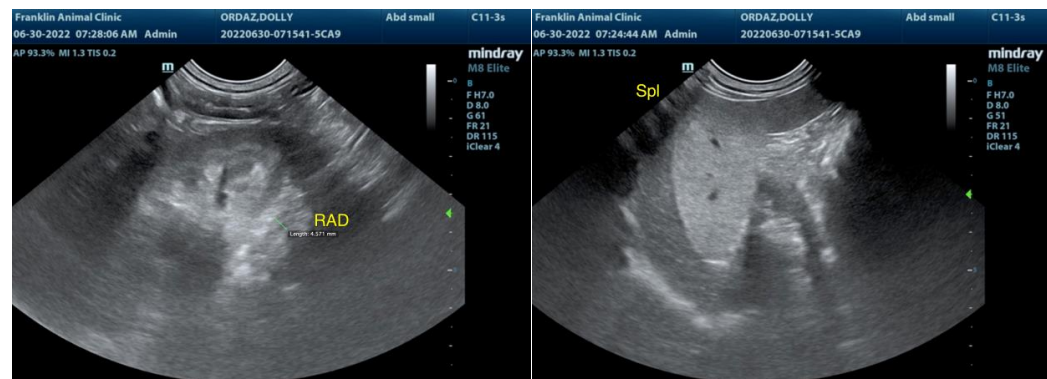
IMAGING PERFORMED BY

Dr. Sam Doverspike

Three view chest radiographs, as well as a thorough neurological / muscular skeletal examination, given the patient's reported change in behavior, are recommended to assess for or rule out occult disease which may cause weight loss. Assessment of caloric plane and for potential competitive eating environment may be considered if clinically indicated.

HOSPITAL NAME

Frankling AC Inc.



REFERRING VET

Dr. Sam Doverspike

INVOICE

14166

DATE

6/30/22



PATIENT

Dolly Ordaz

SPECIES

Canine

BREED

German Shorthair Pointer

SEX

Female Spayed

AGE

18 months

WEIGHT

32 lbs.

INTERPRETED BY

R. McKenzie Daniel,
DVM, DABVP
(Canine and Feline)

IMAGING PERFORMED BY

Dr. Sam Doverspike

HOSPITAL NAME

Frankling AC Inc.

REFERRING VET

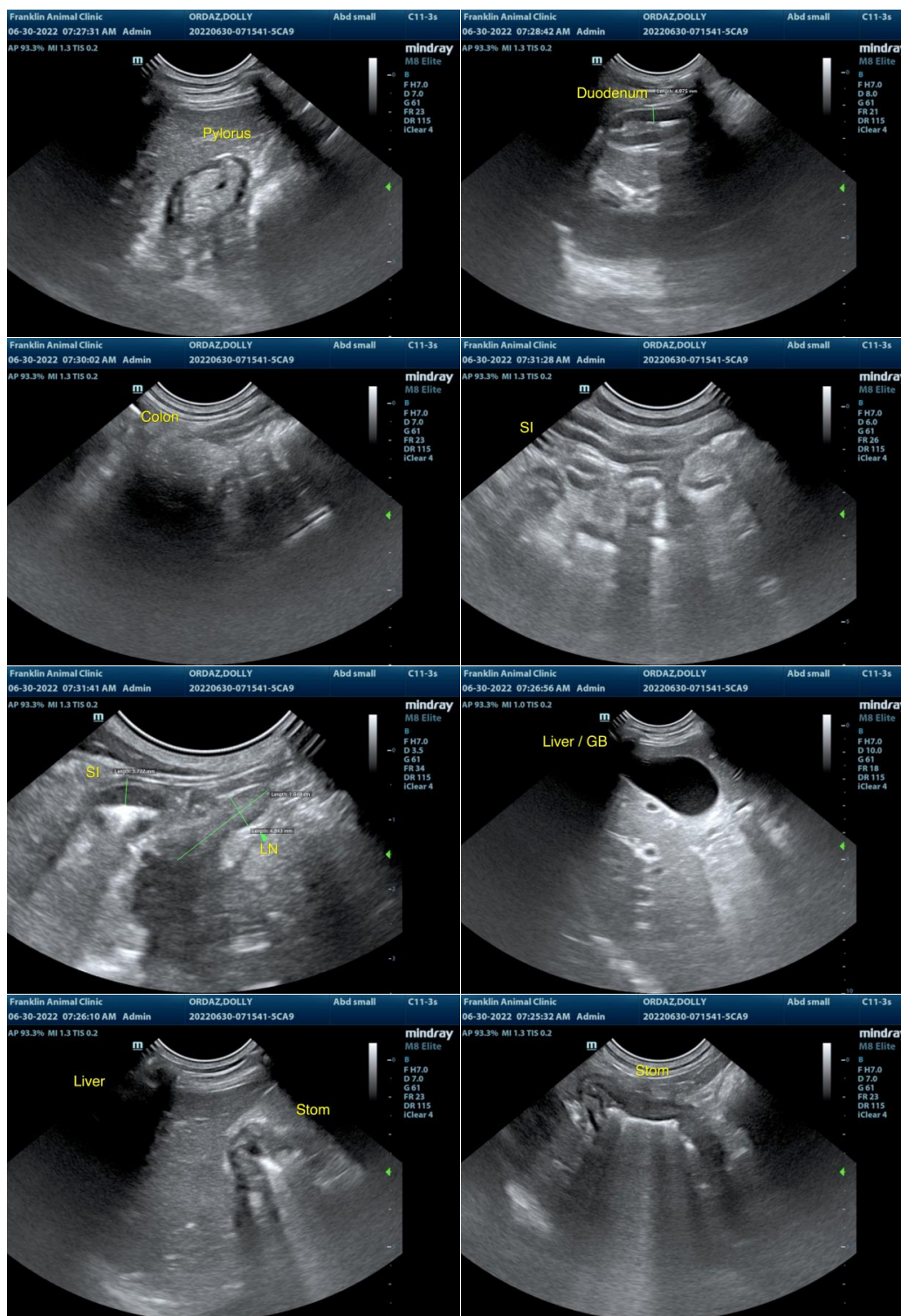
Dr. Sam Doverspike

INVOICE

14166

DATE

6/30/22





PATIENT

Dolly Ordaz

SPECIES

Canine

BREED

German Shorthair Pointer

SEX

Female Spayed

AGE

18 months

WEIGHT

32 lbs.

INTERPRETED BY

R. McKenzie Daniel,
DVM, DABVP
(Canine and Feline)

IMAGING PERFORMED BY

Dr. Sam Doverspike

HOSPITAL NAME

Frankling AC Inc.

REFERRING VET

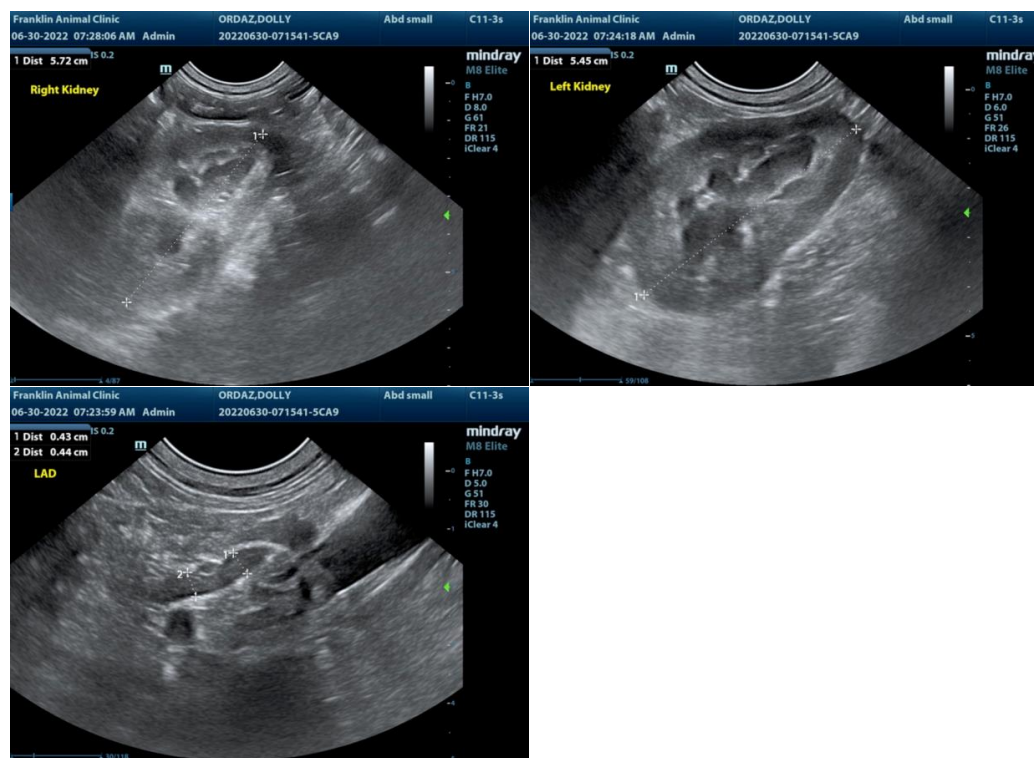
Dr. Sam Doverspike

INVOICE

14166

DATE

6/30/22



The information and recommendations provided are based on the images presented by the referring veterinarian/sonographer. No evaluation can be communicated regarding pathology that was not visible in the image/video clips provided.

Thank you for this referral. If the clinical or image interpretation does not parallel your findings or if I can be of any further assistance please contact me.

R. McKenzie Daniel, DVM, DABVP (Canine / Feline Practice)
info@SonoPath.com