



PATIENT

Hannah Peine

SPECIES

Canine

BREED

Chihuahua

SEX

FS

AGE

9 years

WEIGHT

9

INTERPRETED BY

R. McKenzie Daniel,
DVM, DABVP
(Canine and Feline)

IMAGING PERFORMED BY

Allison Gomer

HOSPITAL NAME

Shohola VH

REFERRING VET

Dr. Livia Demeo

INVOICE

10948

DATE

6/3/26

PRESENTING CLINICAL SIGNS

Signalment: Female dog. Presenting Complaint: Hannah presents for abdominal ultrasound due to elevated liver enzymes

Patient History: - Previously treated with amoxicillin-metronidazole course
- Liver values rechecked after antibiotic course showed increase (ALT increased from 661 to 946, Alk Phos increased from 182 to 213)

Abnormal PE/Chem/CBC/UA Results: Diagnostics: - Chemistry panel: - ALT: 661 (H) [reference range <118], increased to 946 on recheck - Alk Phos: 182 (H), increased to 213 on recheck - Thyroid: WNL - Urinalysis: - Specific gravity: 1.037 - pH: 8 - 2-3 struvite crystals per high power field - 2-3 RBCs per high power field - 2-3 WBCs per high power field

ULTRASONOGRAPHIC EXAMINATION OF THE ABDOMEN

Urinary System

The urinary bladder, trigone, cystourethral junction, and visible pelvic urethra to a depth of 2.0 cm exhibited normal thickness and tone. Anechoic urine was present in the lumen with no uroliths or sediment. The ureteral papillae were normal. The ureters were not visible which is normal. No evidence of inflammatory or neoplastic changes were noted.

No evidence of pathology in the area of the aortic trifurcation.

Normal size and margination were present in the kidneys. A normal 1:3 cortex / medulla ratio and normal corticomedullary definition were maintained. The echogenicity of the cortex was similar to or slightly less than normal liver parenchyma while the medulla echogenicity was hypoechoic to the cortex with no evidence of pelvic dilation. The left kidney measured 3.3 cm in length. The right kidney measured 3.7 cm in length.

Adrenal Glands

The left adrenal gland was indistinctly visualized with no obvious pathology. The left adrenal gland subjectively measured 0.32 cm width. The right adrenal gland was uniform in size and contour with a uniformly hypoechoic parenchyma. The right adrenal gland measured 0.47 cm width at the caudal pole.

Spleen

The spleen exhibited a finely textured and homogenous parenchyma which was hyperechoic to the liver and renal cortical parenchyma. The capsule was smooth and regular without apparent expansion. The splenic vasculature at the hilus was normal in volume with no evidence of congestion or thrombosis. Acute to chronic inflammatory, neoplastic, or benign parenchyma changes were not noted.

Liver/ Gallbladder

The liver presented mild hepatomegaly with a rounded, symmetrical contour. The parenchyma of the liver was mildly increased in echogenicity compared to the spleen, exhibiting a mild, variable coarse echotexture. The hepatic and portal vasculature were normal in appearance without signs of congestion. Intermittent, subtle, hypoechoic intraparenchymal nodules were present, with an example measuring 0.60 cm diameter.



PATIENT

Hannah Peine

SPECIES

Canine

BREED

Chihuahua

SEX

FS

AGE

9 years

WEIGHT

9

INTERPRETED BY

R. McKenzie Daniel,
DVM, DABVP
(Canine and Feline)

IMAGING PERFORMED BY

Allison Gomer

HOSPITAL NAME

Shohola VH

REFERRING VET

Dr. Livia Demeo

INVOICE

10948

DATE

6/3/26

The gallbladder was non-distended in size with thin walls and primarily anechoic luminal content. The cystic and common bile ducts were normal.

Gastrointestinal

The stomach presented intact wall layering with a normal wall layer ratio. The lumen of the stomach was empty without evidence of retained ingesta, fluid, or foreign material.

The small intestine presented intact wall layering with 1:3 muscularis/mucosa ratio. The lumen of the small intestine was empty with no signs of ileus, obstruction, or foreign material.

Normal visible colon wall layers were present with formed feces in lumen.

Pancreas

The pancreas was normal in size and contour with heterogeneous mildly variably hyperechoic parenchyma compared to adjacent omentum. No signs of active inflammation or neoplasia.

Free Abdomen

No overt lymphadenopathy or peritoneal effusion was present.

ULTRASONOGRAPHIC FINDINGS

- Mild enlarged nonhomogeneous discreet nodular liver
- Normal gallbladder
- Overtly normal adrenal glands
- Remodeled pancreas

INTERPRETATION OF THE FINDINGS & FURTHER RECOMMENDATIONS

The appearance of the liver was nonspecific but most consistent with benign hepatopathy. Considerations for the liver may include benign vacuolar / cholestatic hepatopathy, inflammatory/infectious/immune mediated disease, hyperplasia, hematopoiesis, toxic hepatopathy (i.e. copper), other with neoplasia thought less likely. There is no obvious adrenal pathology as a contributing factor. Adrenal screening or workup is warranted if clinical signs consistent with Cushing's Syndrome are noted, although current urine specific gravity is not overtly suggestive of PU/PD.

Ultrasound guided FNA of the liver using a 25-gauge needle and assuming normal coagulation parameters would be warranted for screening cytology. Hepatosupportive medications such as Denamarin or Vitamin E as well as Ursodiol due to its antioxidant and immunomodulatory effects within the liver would be warranted, although these medications may not result in decreased hepatic enzyme levels. Leptospirosis titers / PCR may be considered if clinically indicated. Core or surgical biopsy likely required for definitive diagnosis.



PATIENT

Hannah Peine

SPECIES

Canine

BREED

Chihuahua

SEX

FS

AGE

9 years

WEIGHT

9

INTERPRETED BY

R. McKenzie Daniel,
DVM, DABVP
(Canine and Feline)

IMAGING PERFORMED BY

Allison Gomer

HOSPITAL NAME

Shohola VH

REFERRING VET

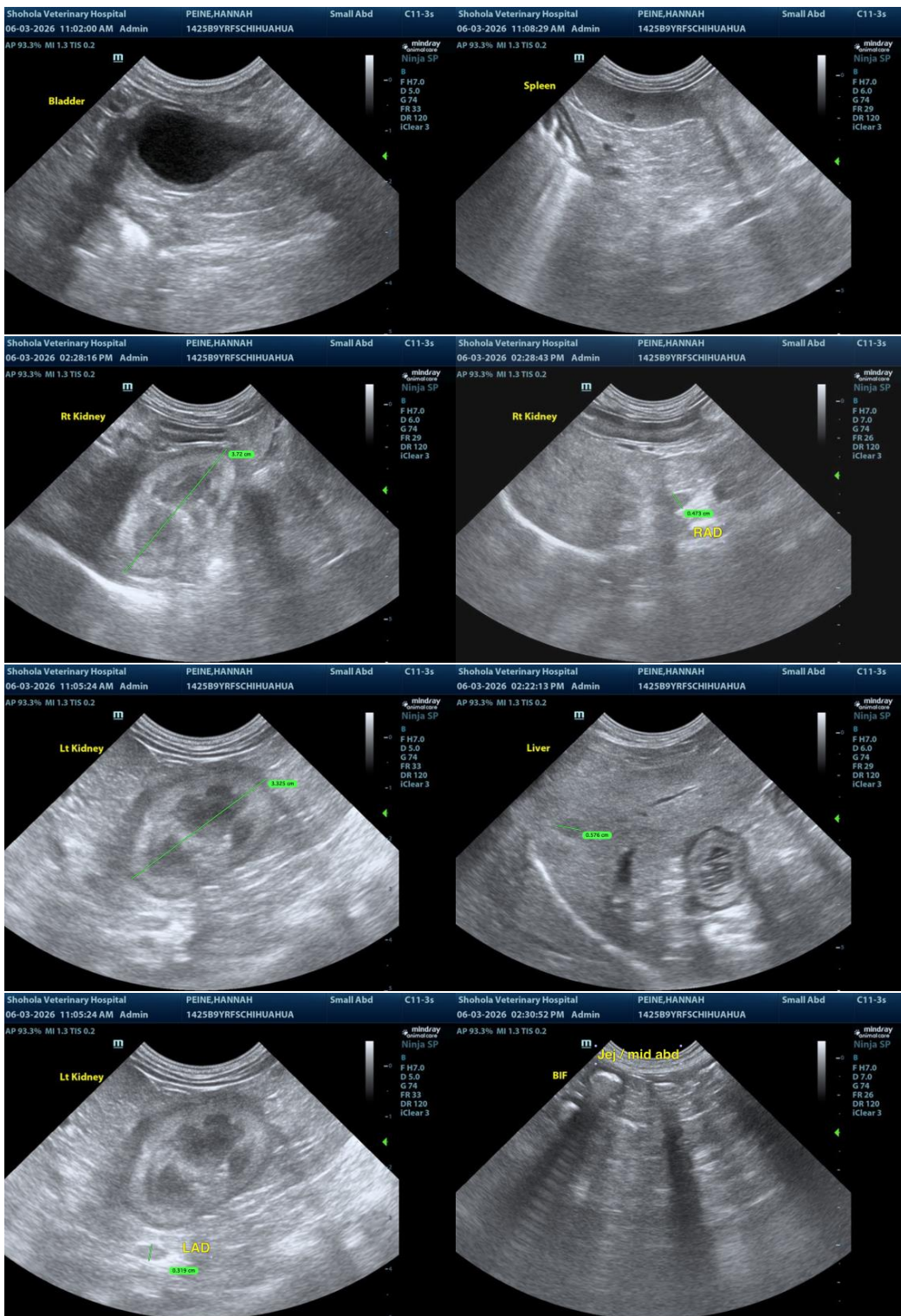
Dr. Livia Demeo

INVOICE

10948

DATE

6/3/26





PATIENT

Hannah Peine

SPECIES

Canine

BREED

Chihuahua

SEX

FS

AGE

9 years

WEIGHT

9

INTERPRETED BY

R. McKenzie Daniel,
DVM, DABVP
(Canine and Feline)

IMAGING PERFORMED BY

Allison Gomer

HOSPITAL NAME

Shohola VH

REFERRING VET

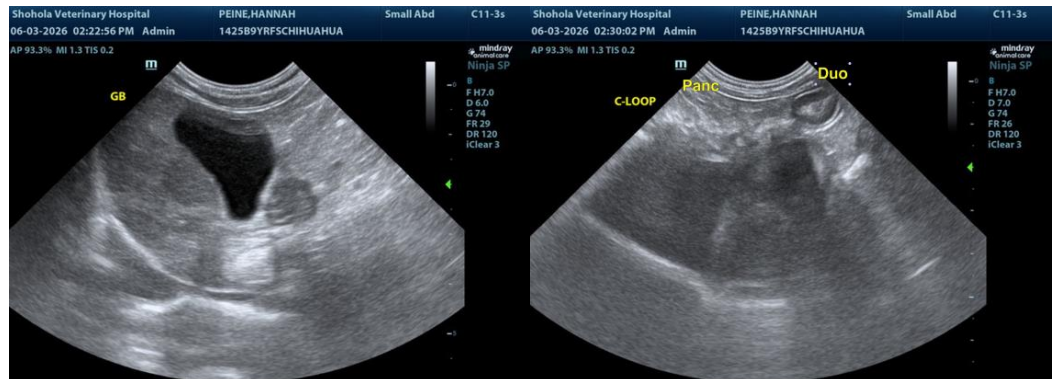
Dr. Livia Demeo

INVOICE

10948

DATE

6/3/26



The information and recommendations provided are based on the images presented by the referring veterinarian/sonographer. No evaluation can be communicated regarding pathology that was not visible in the image/video clips provided.

Thank you for this referral. If the clinical or image interpretation does not parallel your findings or if I can be of any further assistance, please contact me.

R. McKenzie Daniel, DVM, DABVP (Canine/Feline Practice)
info@sonopath.com