



**PATIENT**

Lucy Jenkins

**SPECIES**

Canine

**BREED**

Beagle

**SEX**

Female Spay

**AGE**

12

**WEIGHT**

15.4 kg

**INTERPRETED BY**

R. McKenzie Daniel,  
DVM, DABVP  
(Canine and Feline)

**IMAGING PERFORMED BY**

Dr. Belan

**HOSPITAL NAME**

Willow Park AH

**REFERRING VET**

Dr. Keeler

**INVOICE**

14014

**DATE**

6/3/22

**PRESENTING CLINICAL SIGNS**

Abdominal mass seen on x ray 1 year ago measured 3 cm now measures 7 cm on X-ray.

CBC and chem normal UA pending

**ULTRASONOGRAPHIC EXAMINATION OF THE ABDOMEN**

**Urinary System**

The urinary bladder, trigone, and cystourethral junction exhibited normal thickness and tone. Mild asymmetrical luminal surface to micropolyploid changes with mild variable thickening noted in the apical and dorsal trigone wall were present likely associated with age-related mural changes. The dorsal trigone wall width measured 0.42 cm. Suspect polyploid-like small mass in the area of the urinary bladder neck was noted measuring approximately 1.5 cm x 1.0 cm. Anechoic urine was present in the lumen with mild particulate sediment and potential pinpoint, dependent mineral. No calculi were noted. The ureteral papillae were normal. The ureters were not visible which is normal. No evidence of inflammatory or neoplastic changes were noted.

No overt pathology was noted in the area of the uterine remnant.

Normal size and margination were present in the kidneys. A normal 1:3 cortex / medulla ratio was maintained. The medulla and cortices were uniform in texture with some increased echogenicity and moderate loss of corticomedullary symmetry and definition expected for the age of the patient. No evidence of pelvic dilation was present. The left kidney measured 6.0 cm in length. The right kidney measured 6.1 cm in length.

**Adrenal Glands**

The bilateral adrenal glands were normal in size. Mild parenchyma heterogeneity and mild capsule asymmetry was present without suspicion for overt neoplasia. The left adrenal gland measured 0.53 cm width in the cranial pole and 0.60 cm width in the caudal pole. The right adrenal gland measured 0.7 cm width in the cranial pole and 0.79 cm width in the caudal pole.

**Spleen**

A moderately sized, solid, primarily uniform to isoechoic mass compared to noninvolved splenic parenchyma was present. The mass measured approximately 9.0 cm in diameter and likely involving the mid to cranial spleen. The parenchyma of the mass was heterogeneous to mixed echogenic without areas of cavitation. The non-affected spleen exhibited primarily finely textured and homogenous parenchyma which was hyperechoic to the liver and renal cortical parenchyma. The splenic vasculature at the hilus was normal in volume with no evidence of congestion or thrombosis.

**Liver/ Gallbladder**

The liver was subjectively normal in size, structure, and contour. The liver parenchyma was mildly nonuniform and hypoechoic to the spleen with a moderate coarse echotexture and subjective mild to benign parenchymal remodeling. The hepatic and portal vasculature were normal in appearance without signs of congestion. Intermittent subtle nondisruptive nonhomogeneous to mildly hyperechoic parenchymal nodules were present. An example of a liver nodule measured 1.3 cm x 1.7 cm. The



<b>PATIENT</b>	gallbladder was non-distended in size with mild gallbladder debris. The gallbladder was otherwise normal. The cystic and common bile ducts were normal.
Lucy Jenkins	
<b>SPECIES</b>	<b><i>Gastrointestinal</i></b>
Canine	The stomach presented intact wall layering with a normal wall layer ratio. The lumen of the stomach was empty with no signs of ileus, obstruction, or foreign material.
<b>BREED</b>	The small intestine presented intact wall layering with 1:3 muscularis/mucosa ratio. The lumen of the small intestine was empty with no signs of ileus, obstruction, or foreign material.
Beagle	Normal visible colon wall layers were present with apparent formed feces in lumen.
<b>SEX</b>	<b><i>Pancreas</i></b>
Female Spay	The pancreas was normal in size and contour with isoechoic to heterogeneous parenchyma compared to adjacent omentum. No signs of active inflammation or neoplasia.
<b>AGE</b>	<b><i>Free Abdomen</i></b>
12	Intermittent mesenteric and potential medial iliac lymph nodes were present. The lymph nodes were essentially isoechoic to adjacent omentum without evidence of peripheral inflammation and maintaining a normal width: length ratio (<0.5). An example of Iliac lymph node measured 1.7 cm x 0.6 cm. The lymph nodes are not consistent with inflammatory or neoplastic criteria. Brief transdiaphragmatic cardiac evaluation revealed no overt evidence of pericardial effusion or metastatic criteria.
<b>WEIGHT</b>	
15.4 kg	
<b>INTERPRETED BY</b>	
R. McKenzie Daniel, DVM, DABVP (Canine and Feline)	
<b>IMAGING PERFORMED BY</b>	
Dr. Belan	
<b>HOSPITAL NAME</b>	
Willow Park AH	
<b>REFERRING VET</b>	
Dr. Keeler	
<b>INVOICE</b>	
14014	
<b>DATE</b>	<b><u>INTERPRETATION OF THE FINDINGS &amp; FURTHER RECOMMENDATIONS</u></b>
6/3/22	Assuming no evidence of thoracic pathology on three view chest radiographs, splenectomy with gross inspection of the liver +/- hepatic and urinary bladder biopsies could be considered. Sonographic monitoring of the splenic mass and urinary bladder changes for evidence of progression would be a more conservative approach.

Pending urinalysis, cytospin cytology of urinary sample +/- screening BRAF Assay may be considered.



## PATIENT

Lucy Jenkins

## SPECIES

Canine

## BREED

Beagle

## SEX

Female Spay

## AGE

12

## WEIGHT

15.4 kg

## INTERPRETED BY

R. McKenzie Daniel,  
DVM, DABVP  
(Canine and Feline)

## IMAGING PERFORMED BY

Dr. Belan

## HOSPITAL NAME

Willow Park AH

## REFERRING VET

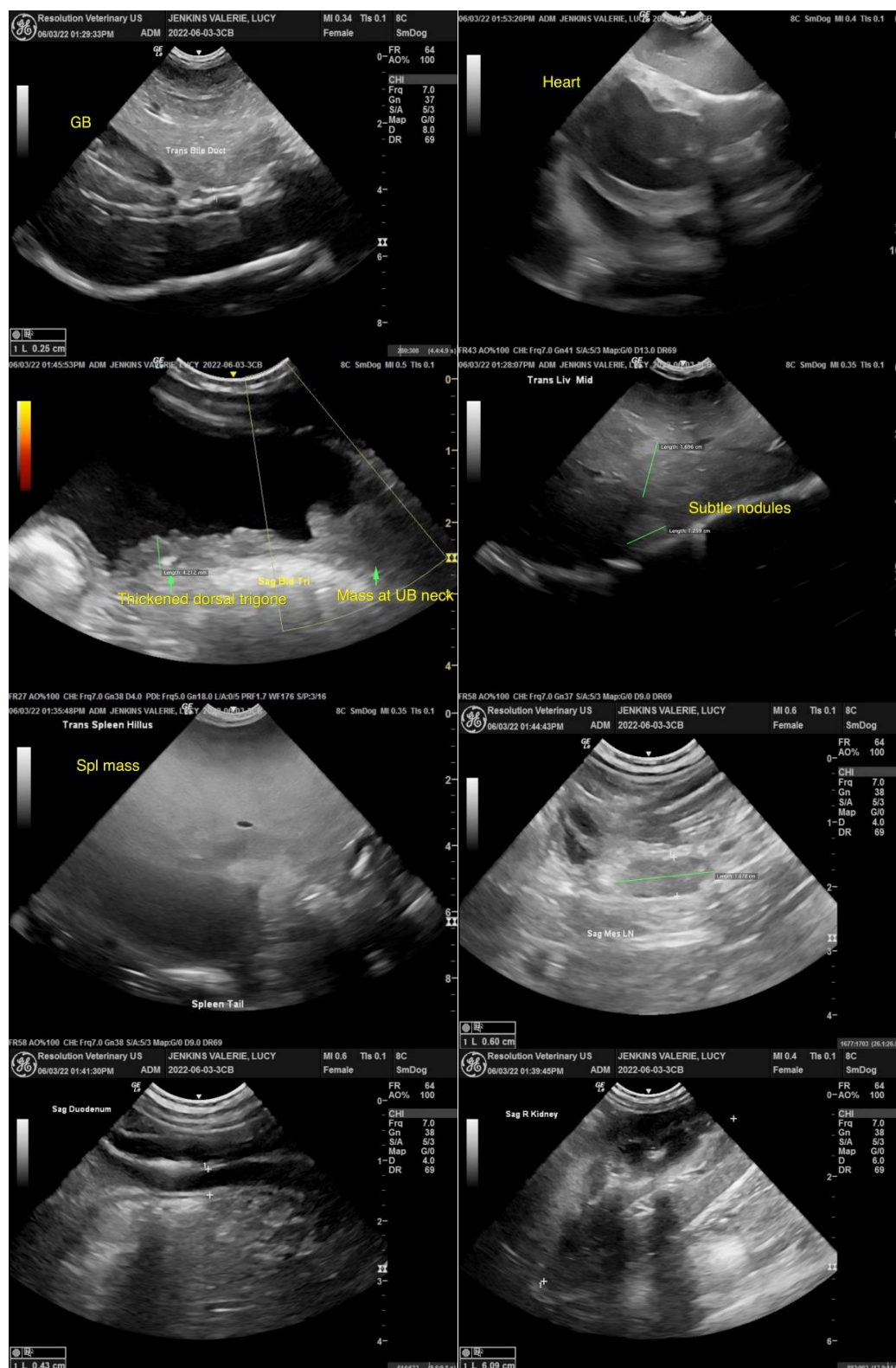
Dr. Keeler

## INVOICE

14014

## DATE

6/3/22





**PATIENT**

Lucy Jenkins

**SPECIES**

Canine

**BREED**

Beagle

**SEX**

Female Spay

**AGE**

12

**WEIGHT**

15.4 kg

**INTERPRETED BY**

R. McKenzie Daniel,  
DVM, DABVP  
(Canine and Feline)

**IMAGING PERFORMED BY**

Dr. Belan

**HOSPITAL NAME**

Willow Park AH

**REFERRING VET**

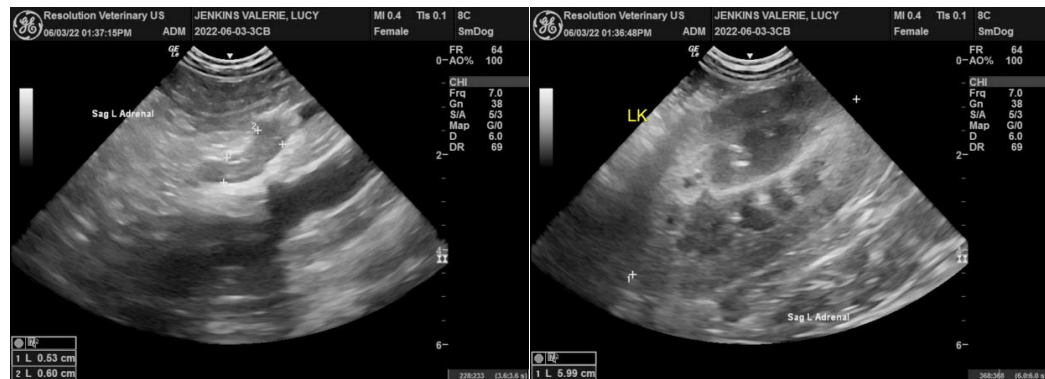
Dr. Keeler

**INVOICE**

14014

**DATE**

6/3/22



The information and recommendations provided are based on the images presented by the referring veterinarian/sonographer. No evaluation can be communicated regarding pathology that was not visible in the image/video clips provided.

Thank you for this referral. If the clinical or image interpretation does not parallel your findings or if I can be of any further assistance please contact me.

**R. McKenzie Daniel, DVM, DABVP (Canine / Feline Practice)**  
info@SonoPath.com