



PATIENT

Blade Bushor

SPECIES

Canine

BREED

Pit Bull

SEX

MN

AGE

13 years

WEIGHT

86

INTERPRETED BY

R. McKenzie Daniel,
DVM, DABVP
(Canine and Feline)

**IMAGING
PERFORMED BY**

Nicole Gotfredson

HOSPITAL NAME

Buffalo Veterinary
Clinic

REFERRING VET

Teresa Bessler

INVOICE

17198

DATE

6/29/23

PRESENTING CLINICAL SIGNS

anal sac adenocarcinoma, met check
Abnormal PE/Chem/CBC/UA Results: CA=10.9

ULTRASONOGRAPHIC EXAMINATION OF THE ABDOMEN

Urinary System

The urinary bladder, trigone, cystourethral junction, and visible pelvic urethra to a depth of 3.0 cm exhibited normal thickness and tone. Anechoic urine was present in the lumen with no uroliths or sediment. The ureteral papillae were normal. The ureters were not visible which is normal. No evidence of inflammatory or neoplastic changes was noted.

The area of the residual prostate was free of overt pathology.

No evidence of medial Iliac or sublumbar lymphadenopathy/masses.

Normal size and margination were present in the kidneys. A normal 1:3 cortex / medulla ratio was maintained. The medulla and cortices were uniform in texture with some increased echogenicity and mild loss of corticomedullary symmetry and definition expected for the age of the patient. No evidence of pelvic dilation was present. The left kidney measured 7.1 cm in length. The right kidney measured 7.3 cm in length.

Adrenal Glands

The left adrenal gland was uniform in size and contour with a uniformly hypoechoic parenchyma. The left adrenal gland measured 0.81 cm width at the caudal pole. The right adrenal gland was not definitively visualized.

Spleen

The spleen exhibited a finely textured and homogenous parenchyma which was hyperechoic to the liver and renal cortical parenchyma. The capsule was smooth and regular without apparent expansion. The splenic vasculature at the hilus was normal in volume with no evidence of congestion or thrombosis. Acute to chronic inflammatory, neoplastic, or benign parenchyma changes were not noted.

Liver/ Gallbladder

The liver was subjectively normal in size, structure, and contour. The liver parenchyma was uniform and hypoechoic to the spleen with a mild coarse echotexture. The hepatic and portal vasculature were normal in appearance without signs of congestion. The gallbladder was non-distended in size with thin walls and primarily anechoic luminal content. The cystic and common bile ducts were normal.

Gastrointestinal

The stomach presented intact wall layering with a normal wall layer ratio. The lumen of the stomach was empty with no signs of ileus, obstruction, or foreign material.

The small intestine presented intact wall layering with 1:3 muscularis/mucosa ratio. The lumen of the small intestine was empty with no signs of ileus, obstruction, or foreign material.

Normal visible colon wall layers were present with apparent formed feces in lumen.



PATIENT

Pancreas

Blade Bushor

The parenchyma of the left limb, body, and right limb of the pancreas presented isoechoic to the adjacent omental fat. A normal curvilinear capsule contour of the pancreas was present. The visible pancreatic duct was normal. No signs of active inflammation or neoplastic disease were evident.

SPECIES

Canine

Free Abdomen

BREED

No omental masses, lymphadenopathy, or evidence of peritoneal effusion were noted.

Pit Bull

ULTRASONOGRAPHIC FINDINGS

SEX

- Sonographically unremarkable abdomen

MN

INTERPRETATION OF THE FINDINGS & FURTHER RECOMMENDATIONS

AGE

There was no evidence of visceral pathology including no evidence of intrabdominal primary or metastatic neoplasia. Sonographic monitoring of the abdomen, ideally based on oncology recommendations, is suggested.

WEIGHT

86

INTERPRETED BY

R. McKenzie Daniel,
DVM, DABVP
(Canine and Feline)

IMAGING PERFORMED BY

Nicole Gotfredson

HOSPITAL NAME

Buffalo Veterinary
Clinic

REFERRING VET

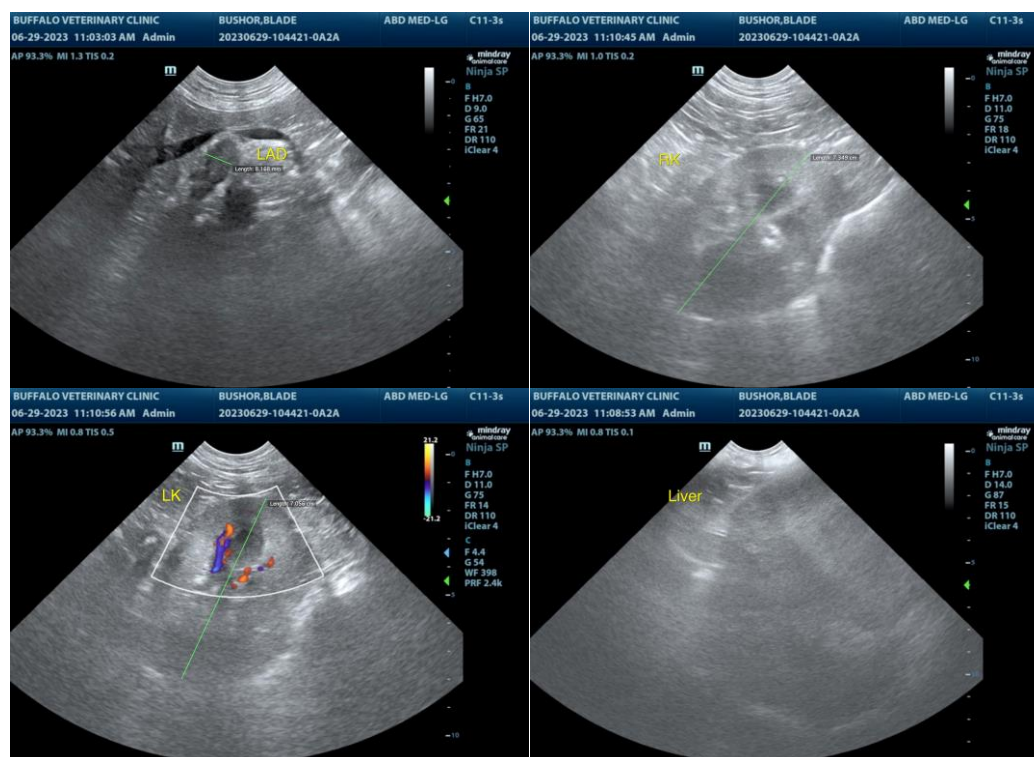
Teresa Bessler

INVOICE

17198

DATE

6/29/23





PATIENT

Blade Bushor

SPECIES

Canine

BREED

Pit Bull

SEX

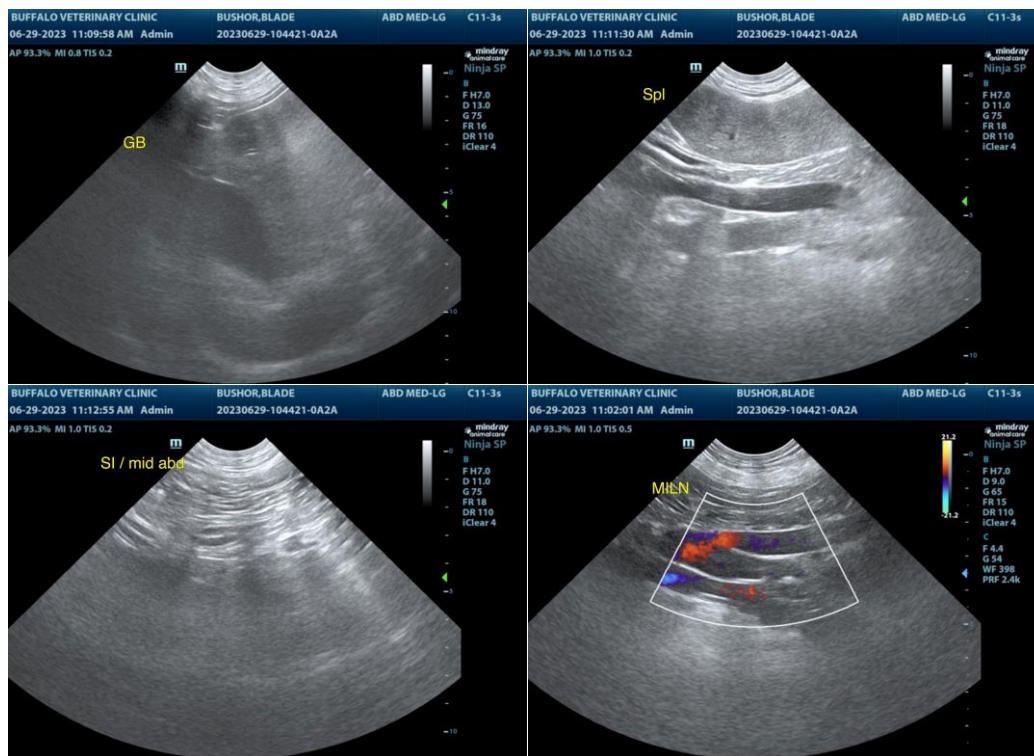
MN

AGE

13 years

WEIGHT

86



INTERPRETED BY

R. McKenzie Daniel,
DVM, DABVP
(Canine and Feline)

IMAGING PERFORMED BY

Nicole Gotfredson

The information and recommendations provided are based on the images presented by the referring veterinarian/sonographer. No evaluation can be communicated regarding pathology that was not visible in the image/video clips provided.

Thank you for this referral. If the clinical or image interpretation does not parallel your findings or if I can be of any further assistance, please contact me.

HOSPITAL NAME

Buffalo Veterinary
Clinic

R. McKenzie Daniel, DVM, DABVP (Canine/Feline Practice)

info@sonopath.com

REFERRING VET

Teresa Bessler

INVOICE

17198

DATE

6/29/23