



PATIENT

Jessy St. Paul

SPECIES

Canine

BREED

Golden Retriever

SEX

Spayed Female

AGE

9 Years

WEIGHT

76 Pounds

INTERPRETED BY

R. McKenzie Daniel,
DVM, DABVP
(Canine and Feline)

IMAGING PERFORMED BY

Rachel Runnells, RVT

HOSPITAL NAME

SVS Imaging KC

REFERRING VET

Dr. Elizabeth Oetting

INVOICE

16390

DATE

6/29/22

PRESENTING CLINICAL SIGNS

History: Recheck adrenal glands, especially right from 3/23 and 5/9 2022.

LIMITED ULTRASONOGRAPHIC EXAMINATION

The left adrenal gland was uniform in size and contour with a uniformly hypoechoic parenchyma. The left adrenal gland measured 2.9 cm in length x 0.82 cm width at the cranial pole and 0.90 cm width at the caudal pole.

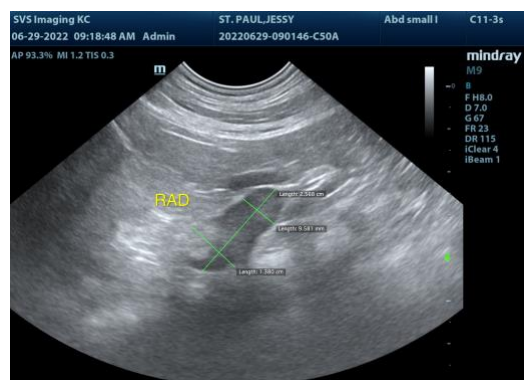
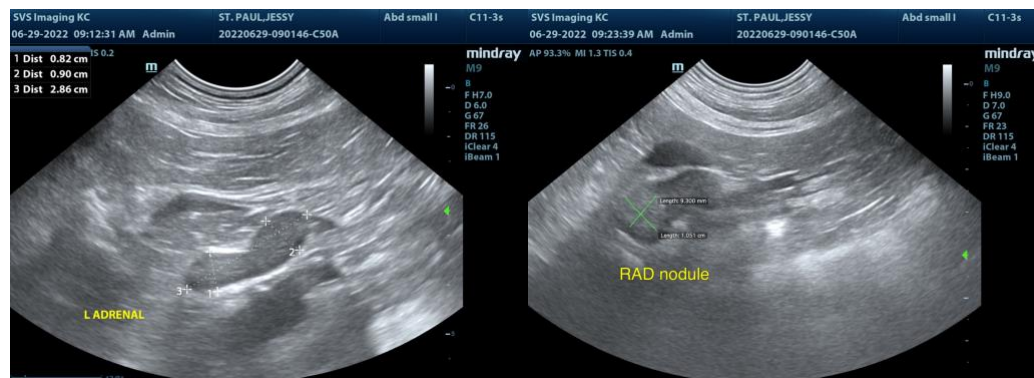
The right adrenal gland was uniform in size and contour with a uniformly hypoechoic parenchyma. The right adrenal gland measured 2.5 cm in length x 1.3 cm width at the cranial pole and 0.95 cm width at the caudal pole. A previously noted cranial right adrenal nodule exhibiting mild nonhomogeneous hyperechoic nonmineralized parenchyma, measuring 1.0 cm x 0.93 cm. The nodule did not distort the cranial right adrenal capsule. No evidence of vascular invasion or parenchymal escape.

ULTRASONOGRAPHIC FINDINGS

- Subjectively static, previously noted right adrenal nodule

INTERPRETATION OF THE FINDINGS & FURTHER RECOMMENDATIONS

Continued monitoring of the systemic BP recommended to assess for evidence of hypertension, which may allude to an emerging right adrenal pheochromocytoma. No overt evidence of overt progression compared to the previous study. Continued sonographic monitoring versus prophylactic right adrenalectomy could be considered.



The information and recommendations provided are based on the images presented by the



PATIENT

Jessy St. Paul

SPECIES

Canine

BREED

Golden Retriever

SEX

Spayed Female

AGE

9 Years

WEIGHT

76 Pounds

INTERPRETED BY

R. McKenzie Daniel,
DVM, DABVP
(Canine and Feline)

**IMAGING
PERFORMED BY**

Rachel Runnells, RVT

HOSPITAL NAME

SVS Imaging KC

REFERRING VET

Dr. Elizabeth Oetting

INVOICE

16390

DATE

6/29/22

referring veterinarian. No evaluation can be communicated regarding pathology that was not visible in the image/video clips provided.

Thank you for this referral. If the clinical or image interpretation does not parallel your findings or if I can be of any further assistance please contact me.

R. McKenzie Daniel, DVM, DABVP (Canine / Feline Practice)
info@SonoPath.com