



**PATIENT**

Dexter Shaver

**SPECIES**

Canine

**BREED**

Pug

**SEX**

Neutered Male

**AGE**

1 Year

**WEIGHT**

23 Pounds

**INTERPRETED BY**

R. McKenzie Daniel,  
DVM, DABVP  
(Canine and Feline)

**IMAGING PERFORMED BY**

Amy Mayhew, LVT

**HOSPITAL NAME**

SVS Imaging MI

**REFERRING VET**

Family pet Practice

**INVOICE**

16400

**DATE**

6/29/22

**PRESENTING CLINICAL SIGNS**

History: Presented last week for diarrhea and decreased appetite. New treats have been introduced recently. Diarrhea improved with probiotic then resumed when finished.  
Abnormal PE/Chem/CBC/UA Results: Please see attached BW. Negative fecal. Unremarkable CBC and chemistry panel, sodium to potassium ratio 36.

**ULTRASONOGRAPHIC EXAMINATION OF THE ABDOMEN**

**Urinary System**

The urinary bladder, trigone, cystourethral junction, and visible pelvic urethra to a depth of 5.0 cm exhibited normal thickness and tone. Anechoic urine was present in the lumen with no uroliths or sediment. The ureteral papillae were normal. The ureters were not visible which is normal. No evidence of inflammatory or neoplastic changes were noted.

The residual prostate was symmetrically normal in size with uniform parenchyma and slight coarse echotexture measuring 0.91 cm in diameter.

Normal size and margination was present in the kidneys. A normal 1:3 cortex / medulla ratio and normal corticomedullary definition were maintained. The echogenicity of the cortex was similar to or slightly less than normal liver parenchyma while the medulla echogenicity was hypoechoic to the cortex with no evidence of pelvic dilation. The left kidney measured 4.2 cm in length. The right kidney measured 4.37 cm in length.

**Adrenal Glands**

The left adrenal gland was uniform in size and contour with a uniformly hypoechoic parenchyma. The left adrenal gland measured 0.38 cm width at the caudal pole and 0.37 cm width at the cranial pole.

The right adrenal gland was uniform in size and contour with a uniformly hypoechoic parenchyma. The right adrenal gland measured 0.56 cm width at the caudal pole and 0.50 cm width at the cranial pole.

**Spleen**

The spleen exhibited a finely textured and homogenous parenchyma which was hyperechoic to the liver and renal cortical parenchyma. The capsule was smooth and regular without apparent expansion. The splenic vasculature at the hilus was normal in volume with no evidence of congestion or thrombosis. Acute to chronic inflammatory, neoplastic, or benign parenchyma changes were not noted.

**Liver**

The liver was subjectively normal in size, structure, and contour. The liver parenchyma was uniform and hypoechoic to the spleen with a mild coarse echotexture. The hepatic and portal vasculature were normal in appearance without signs of congestion. The gallbladder was non-distended in size with thin walls and primarily anechoic luminal content. The cystic and common bile ducts were normal.

**Gastrointestinal**

The stomach walls were sonographically normal. The lumen of the stomach contained mild to moderate nonshadowing ingesta/chyme. The ventral gastric body wall measured 0.44 cm. No evidence of mechanical pyloric outflow obstruction.



**PATIENT**

Dexter Shaver

The small intestine presented intact wall layering and maintained 1:3 muscularis/mucosa ratio. Mild duodenojejunal mucosal speckling was present, along with segmental nonshadowing duodenojejunal chyme. No evidence of mechanical obstructive pattern. The duodenum wall measured 0.56 cm. The jejunum wall measured 0.40 cm.

**SPECIES**

Canine

The colon revealed intact yet mild prominent wall layering. The colon exhibited generalized mild distention with non-formed echogenic fecal matter consistent with diarrhea. The descending colon wall measured 0.21 cm.

**BREED**

Pug

***Pancreas***

The parenchyma of the left limb, body and right limb of the pancreas presented isoechoic to the adjacent omental fat. A normal curvilinear capsule contour of the pancreas was present. The visible pancreatic duct was normal. No signs of active inflammation or neoplastic disease was evident.

**SEX**

Neutered Male

***Free Abdomen***

Intermittent mildly prominent to enlarged colic and medial iliac lymph nodes were present. The lymph nodes were essentially isoechoic to adjacent omentum without evidence of peripheral inflammation and maintaining a normal width: length ratio (<0.5). An example of medial iliac lymph node measured 1.2 cm x 0.45 cm. An example of colic lymph node measured 1.4 cm x 0.62 cm.

**AGE**

1 Year

No evidence of peritoneal free fluid.

**WEIGHT**

23 Pounds

**ULTRASONOGRAPHIC FINDINGS**

- Normal stomach with mild to moderate ingesta/chyme
- Overtly normal small bowel with mild nonspecific duodenojejunal mucosal speckling
- Mild colitis pattern
- Intermittent, subjectively reactive/benign mesenteric and medial iliac lymphadenopathy

**INTERPRETED BY**

R. McKenzie Daniel,  
DVM, DABVP  
(Canine and Feline)

**INTERPRETATION OF THE FINDINGS & FURTHER RECOMMENDATIONS**

No evidence of significant gastroenterocolic pathology such as intussusception, loss of intestinal wall layering, mechanical obstructive pattern or foreign material. In patients with recurrent GI signs, considerations may include dietary intolerance/food allergy, dysbiosis, occult parasitism or emerging IBD. The mucosal speckling noted in the duodenum and jejunum is nonspecific yet at times has been associated with underlying inflammation. Monitoring of albumin levels is recommended. A GI panel to include PLI/TLI/Cobalamin/Folate could be considered.

**IMAGING PERFORMED BY**

Amy Mayhew, LVT

**HOSPITAL NAME**

SVS Imaging MI

**REFERRING VET**

Family pet Practice

Empirically, a limited antigen or hydrolyzed diet trial with potential long term dietary therapy, prophylactic deworming (Panacur 50 mg/kg SID x 5 consecutive days with repeat protocol in 3 weeks even if fecal testing is negative), high colony count probiotic (Provable or Visbiome), antibiotic trial and as needed gastrointestinal support with assessment of clinical response may prove beneficial. Intestinal biopsies may be indicated if GI signs continue despite empirical therapy.

**INVOICE**

16400

**DATE**

6/29/22



**PATIENT**

Dexter Shaver

**SPECIES**

Canine

**BREED**

Pug

**SEX**

Neutered Male

**AGE**

1 Year

**WEIGHT**

23 Pounds

**INTERPRETED BY**

R. McKenzie Daniel, DVM, DABVP (Canine and Feline)

**IMAGING PERFORMED BY**

Amy Mayhew, LVT

**HOSPITAL NAME**

SVS Imaging MI

**REFERRING VET**

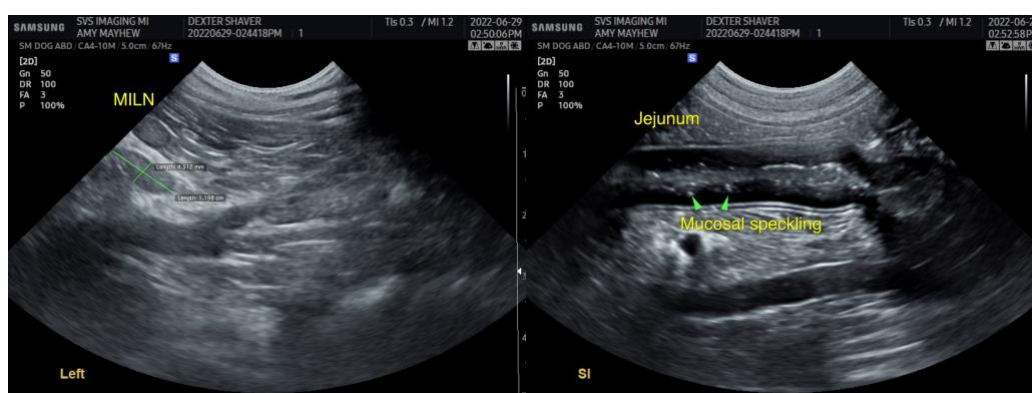
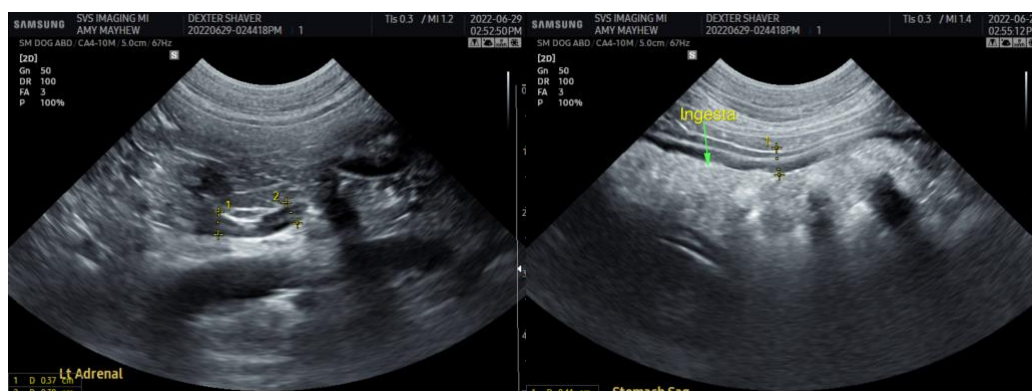
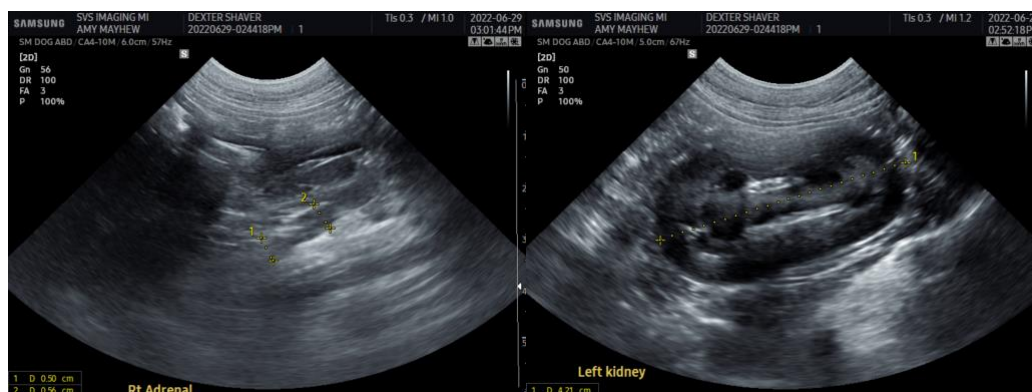
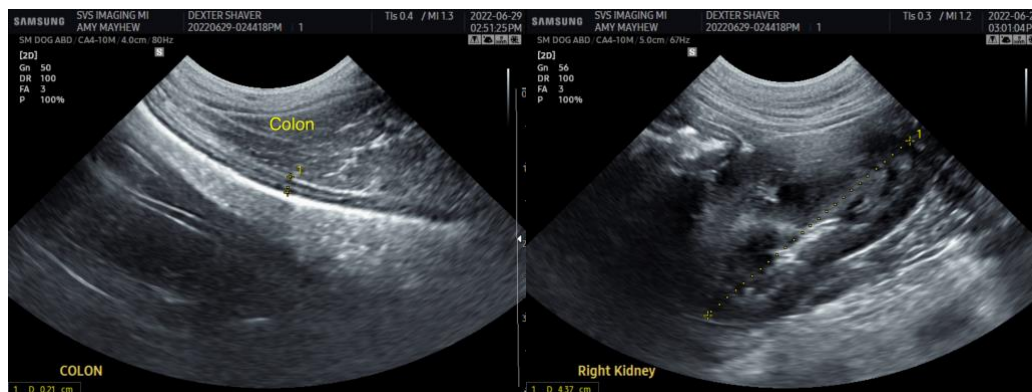
Family pet Practice

**INVOICE**

16400

**DATE**

6/29/22





**PATIENT**

Dexter Shaver

**SPECIES**

Canine

**BREED**

Pug

**SEX**

Neutered Male

**AGE**

1 Year

**WEIGHT**

23 Pounds

**INTERPRETED BY**

R. McKenzie Daniel,  
DVM, DABVP  
(Canine and Feline)

**IMAGING PERFORMED BY**

Amy Mayhew, LVT

**HOSPITAL NAME**

SVS Imaging MI

**REFERRING VET**

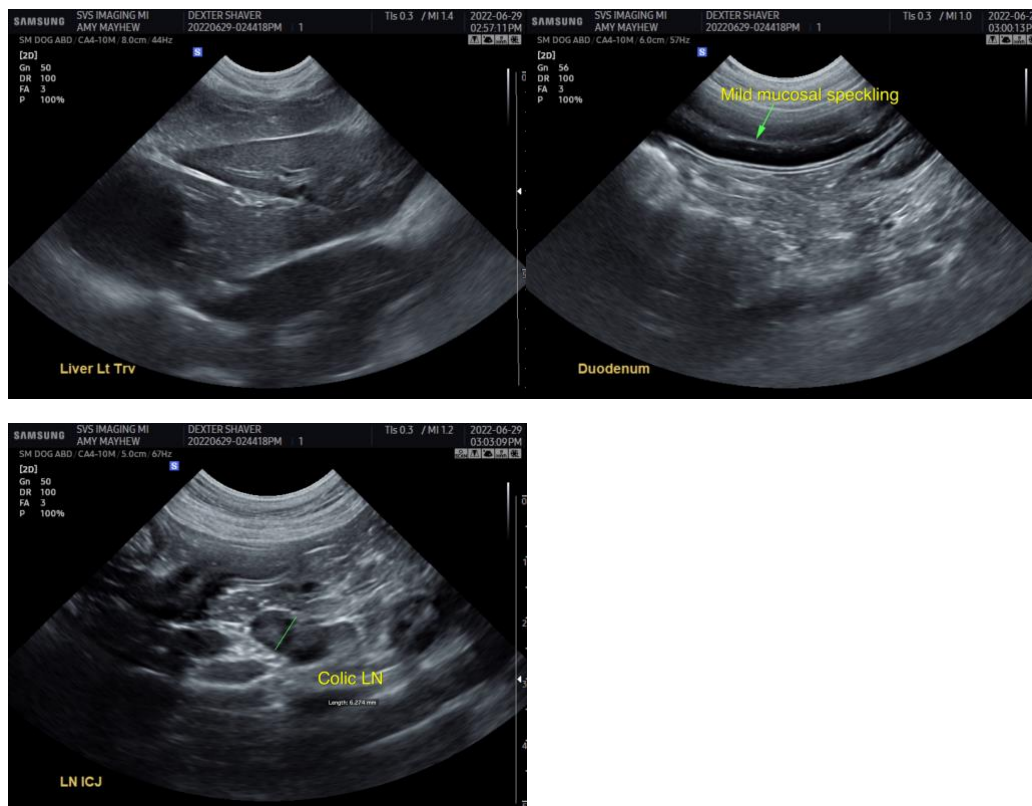
Family pet Practice

**INVOICE**

16400

**DATE**

6/29/22



The information and recommendations provided are based on the images presented by the referring veterinarian. No evaluation can be communicated regarding pathology that was not visible in the image/video clips provided.

Thank you for this referral. If the clinical or image interpretation does not parallel your findings or if I can be of any further assistance please contact me.

**R. McKenzie Daniel, DVM, DABVP (Canine / Feline Practice)**  
info@SonoPath.com