



PATIENT

Harley Rosalia

SPECIES

Feline

BREED

DSH

SEX

Female Spayed

AGE

1

WEIGHT

6.9

INTERPRETED BY

R. McKenzie Daniel,
DVM, DABVP
(Canine and Feline)

IMAGING PERFORMED BY

Marco Lichfield

HOSPITAL NAME

Sova AH

REFERRING VET

Robert Sova

INVOICE

17178

DATE

6/28/23

PRESENTING CLINICAL SIGNS

R/O UTI vs. Idiopathic cystitis vs. neoplasia currently on Prazosin and gabapentin
Abnormal PE/Chem/CBC/UA Results: Crystals in Urine

ULTRASONOGRAPHIC EXAMINATION OF THE URINARY TRACT

Urinary System

The urinary bladder was normal in size and tone with normal urinary bladder wall. No evidence of inflammatory mural criteria was noted. Anechoic urine was present with no sediment, mineral, or calculi. The urethra exhibited normal structure and tone to a depth of 3.0 cm.

No evidence of pathology in the area of the aortic trifurcation.

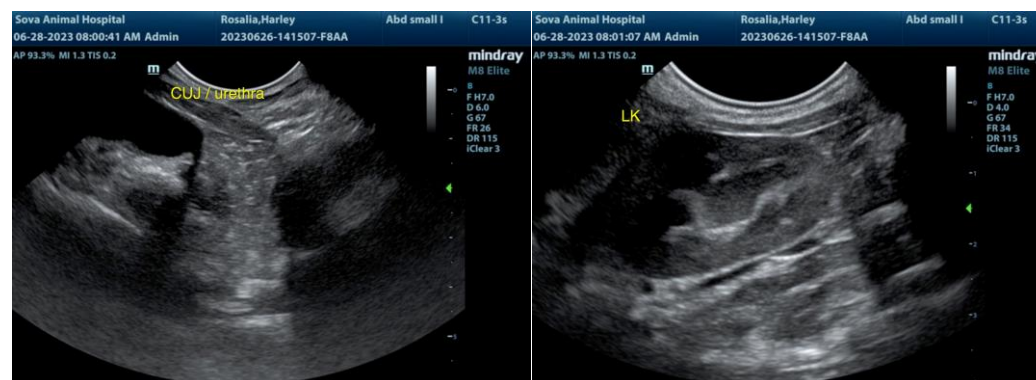
Normal size and margination were present in the kidneys. A normal 1:3 cortex / medulla ratio was present. No evidence of pyelectasia or dystrophic disease was noted. The left kidney measured 3.3 cm in length. The right kidney measured 3.5 cm in length.

ULTRASONOGRAPHIC FINDINGS

- Sonographically unremarkable bilateral kidneys
- Sonographically unremarkable urinary bladder and visible proximal urethra.

INTERPRETATION OF THE FINDINGS & FURTHER RECOMMENDATIONS

There was no evidence of upper or lower urinary tract pathology.





PATIENT

Harley Rosalia

SPECIES

Feline

BREED

DSH

SEX

Female Spayed

AGE

1

WEIGHT

6.9

INTERPRETED BY

R. McKenzie Daniel,
DVM, DABVP
(Canine and Feline)

IMAGING PERFORMED BY

Marco Lichfield

HOSPITAL NAME

Sova AH

REFERRING VET

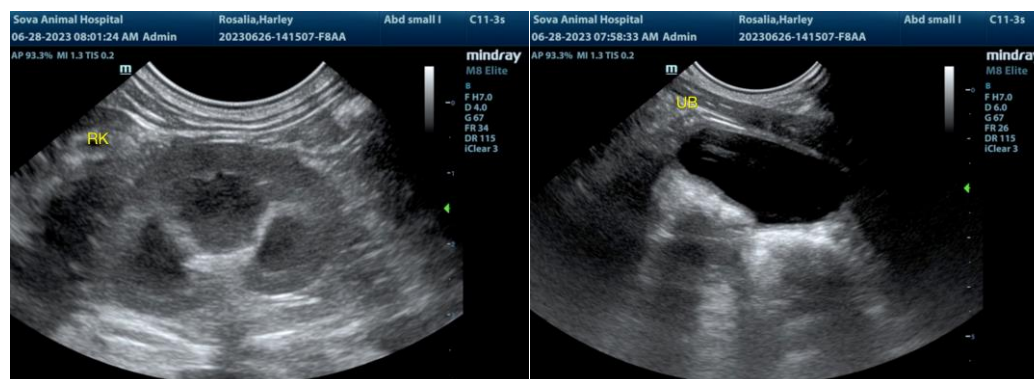
Robert Sova

INVOICE

17178

DATE

6/28/23



The information and recommendations provided are based on the images presented by the referring veterinarian/sonographer. No evaluation can be communicated regarding pathology that was not visible in the image/video clips provided.

Thank you for this referral. If the clinical or image interpretation does not parallel your findings or if I can be of any further assistance, please contact me.

R. McKenzie Daniel, DVM, DABVP (Canine/Feline Practice)
info@sonopath.com