



PATIENT

Bandy Silowka

PRESENTING CLINICAL SIGNS

Elevated Calcium, PU/PD, desmopressin trial done with no improvement SQF

ALP 433, Calcium > 16, Phosphorous 2.6

SPECIES

Canine

ULTRASONOGRAPHIC EXAMINATION OF THE ABDOMEN

BREED

Terrier Mix

Urinary System

The urinary bladder was mildly distended containing anechoic urine with no overt inflammatory or neoplastic urinary bladder criteria. The urethra appeared to be potentially displaced ventrally secondary to an undifferentiated, mild nonhomogeneous mass noted dorsal to the urinary bladder / urethra, as well as ventral to the distal descending colon colorectum within the area of the pelvic canal extending cranially into the area of the iliac trifurcation. The mass measured approximately 5.0 cm in diameter, but likely larger as the entire mass would not fit into a single viewing window. Subtle evidence of associated regional inflammation was noted. No overt evidence of free fluid was noted.

SEX

MN

Normal size and margination were present in the kidneys. A normal 1:3 cortex / medulla ratio was maintained. The medulla and cortices were uniform in texture with some increased echogenicity and mild loss of corticomedullary symmetry and definition expected for the age of the patient. mild pyelectasia was noted in both kidneys. The left kidney measured 6.2 cm in length. The right kidney measured 6.5 cm in length.

AGE

2001

WEIGHT

42

Adrenal Glands

INTERPRETED BY

R. McKenzie Daniel,
 DVM, DABVP
 (Canine and Feline)

The left adrenal gland was uniform in size and contour with a uniformly hypoechoic parenchyma. The left adrenal gland measured 2.3 cm length x 0.79 cm width at the caudal pole. The right adrenal gland was uniform in size and contour with a uniformly hypoechoic parenchyma. The right adrenal gland measured 1.9 cm length x 0.71 cm width at the caudal pole.

IMAGING

PERFORMED BY

Rebekah Jakum, CVT
 ARDMS/RVT

Spleen

The spleen exhibited subjective normal size with subtle areas of asymmetrical medial capsule contour with minor generalized splenic parenchyma heterogeneity. No masses or nodules are noted.

HOSPITAL NAME

Maple Hills VH

Liver/ Gallbladder

The liver presented enlarged in size. The parenchyma of the liver was subjectively normal in echogenicity compared to the spleen and renal cortices. The liver parenchyma was uniform with a mildly coarse echotexture. A solitary nondisruptive uniform mildly hyperechoic intraparenchymal nodule was present measuring 2.0 cm in diameter. The capsule of the liver was symmetrically rounded to mildly swollen in margination. The hepatic and portal vasculature were normal in appearance without signs of congestion. The gallbladder was non-distended in size with mild gallbladder debris. The cystic and common bile ducts were normal.

REFERRING VET

Dr. Eckman

INVOICE

14158

Gastrointestinal

The stomach presented intact wall layering with a normal wall layer ratio. The lumen of the stomach was empty with no signs of ileus, obstruction, or foreign material.

DATE

6/28/22



PATIENT

Bandy Silowka

The small intestine presented intact wall layering with 1:3 muscularis/mucosa ratio. The lumen of the small intestine was empty with no signs of ileus, obstruction, or foreign material.

Normal visible colon wall layers were present with apparent formed feces in lumen.

SPECIES

Canine

Pancreas

The parenchyma of the left limb, body, and right limb of the pancreas presented isoechoic to the adjacent omental fat. A normal curvilinear capsule contour of the pancreas was present. The visible pancreatic duct was normal. No signs of active inflammation or neoplastic disease were evident.

BREED

Terrier Mix

Free Abdomen

No evidence of mid to cranial abdominal omental lymphadenopathy or masses were present. No overt evidence of peritoneal free fluid was noted.

SEX

MN

ULTRASONOGRAPHIC FINDINGS

AGE

2001

- Unspecified nonhomogeneous mass in the area of the pelvic inlet dorsal to the urinary bladder ventral to the colon extending cranially into the area of the iliac trifurcation
- Mild nonhomogeneous spleen
- Vacuolar hepatopathy pattern with nonspecific yet subjectively benign intraparenchymal nodule - nodule suggestive of benign lipogranuloma
- Mild gallbladder debris (non-mucocele)
- Mild age-related kidneys exhibiting minor pyelectasia

WEIGHT

42

INTERPRETED BY

R. McKenzie Daniel,
 DVM, DABVP
 (Canine and Feline)

INTERPRETATION OF THE FINDINGS & FURTHER RECOMMENDATIONS

Although sampling is required for further assessment, the unspecified mass in the area of the pelvic inlet dorsal to the urinary bladder is suggestive of neoplastic criteria given the hypercalcemia. Non-neoplastic etiologies such as granuloma or other are considered less likely. Potential origin of the mass may include uterine remnant, lymph node, or other unspecified neoplasia.

IMAGING PERFORMED BY

Rebekah Jakum, CVT
 ARDMS/RVT

HOSPITAL NAME

Maple Hills VH

Assuming normal clotting status, ultrasound-guided FNA of the mass is warranted for screening cytology and potential oncology consultation. Rectal palpation and three view chest radiographs, if not done, are recommended. Concurrent screening hepatosplenic FNA, assuming normal clotting status and using a 25-gauge needle, to rule out additional evidence of multicentric neoplasia is warranted.

REFERRING VET

Dr. Eckman

INVOICE

14158

DATE

6/28/22



PATIENT

Bandy Silowka

SPECIES

Canine

BREED

Terrier Mix

SEX

MN

AGE

2001

WEIGHT

42

INTERPRETED BY

R. McKenzie Daniel,
DVM, DABVP
(Canine and Feline)

IMAGING PERFORMED BY

Rebekah Jakum, CVT
ARDMS/RVT

HOSPITAL NAME

Maple Hills VH

REFERRING VET

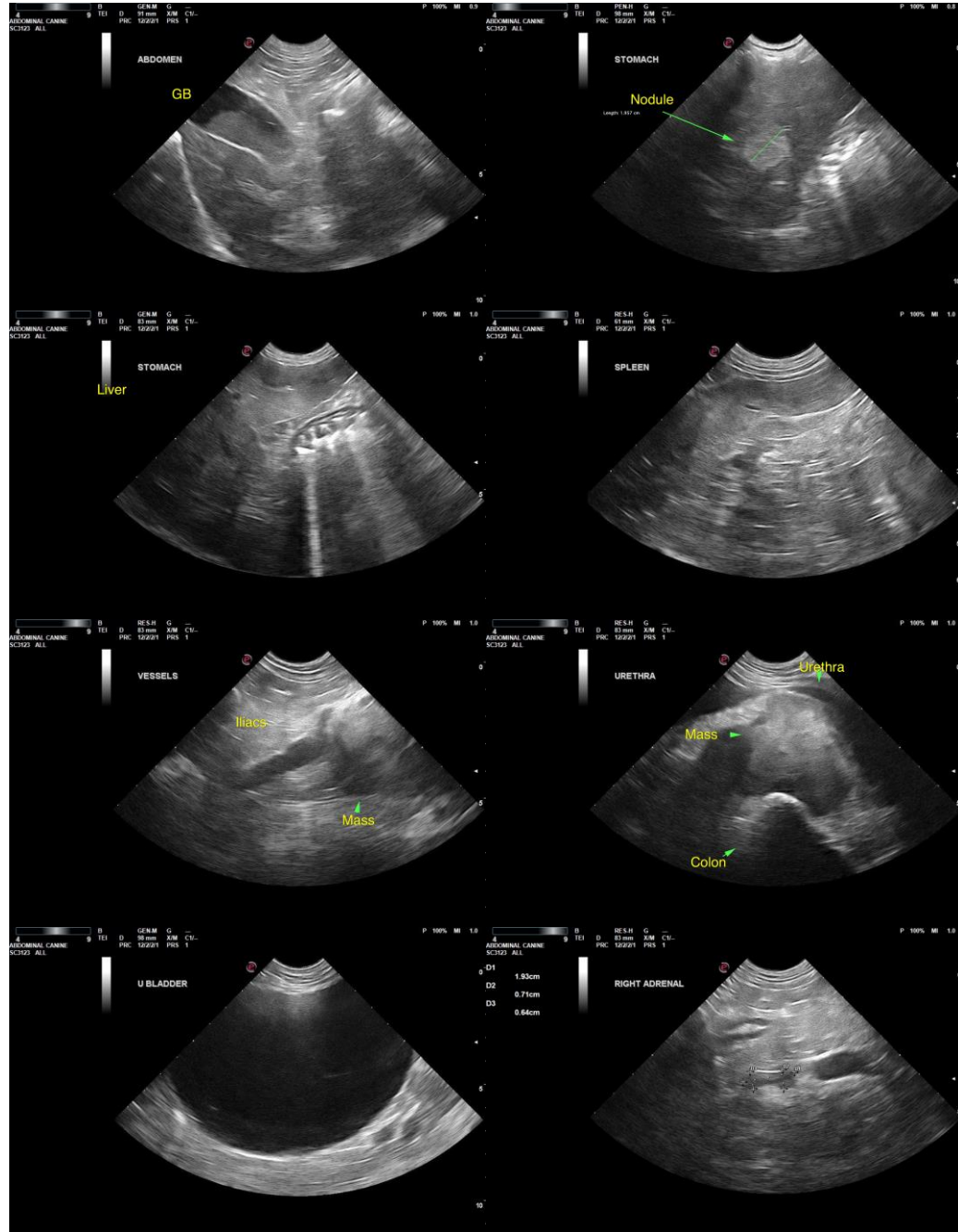
Dr. Eckman

INVOICE

14158

DATE

6/28/22





PATIENT

Bandy Silowka

SPECIES

Canine

BREED

Terrier Mix

SEX

MN

AGE

2001

WEIGHT

42

INTERPRETED BY

R. McKenzie Daniel,
 DVM, DABVP
 (Canine and Feline)

**IMAGING
 PERFORMED BY**

Rebekah Jakum, CVT
 ARDMS/RVT

HOSPITAL NAME

Maple Hills VH

REFERRING VET

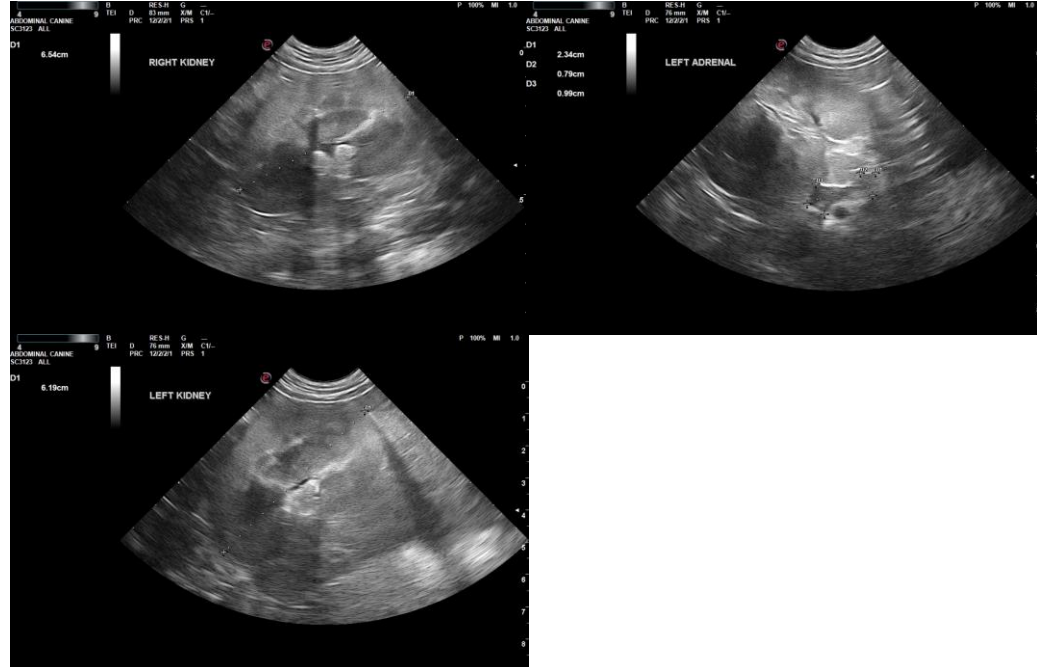
Dr. Eckman

INVOICE

14158

DATE

6/28/22



The information and recommendations provided are based on the images presented by the referring veterinarian/sonographer. No evaluation can be communicated regarding pathology that was not visible in the image/video clips provided.

Thank you for this referral. If the clinical or image interpretation does not parallel your findings or if I can be of any further assistance, please contact me.

R. McKenzie Daniel, DVM, DABVP (Canine/Feline Practice)
mac.daniel@sonopath.com