



PATIENT	PRESENTING CLINICAL SIGNS
Moose Roman	History: Chronic diarrhea, occasional vomiting, on hydrolyzed diet. Current meds: Tylan powder, Lomotil
SPECIES	ULTRASONOGRAPHIC EXAMINATION OF THE ABDOMEN
Canine	Urinary System
BREED	The urinary bladder, trigone, cystourethral junction, and visible pelvic urethra to a depth of 4.0 cm exhibited normal thickness and tone. Anechoic urine was present in the lumen with no uroliths or sediment. The ureteral papillae were normal. The ureters were not visible which is normal. No evidence of inflammatory or neoplastic changes were noted.
Basenji	
SEX	No overt pathology in the area of the prostate gland.
Neutered Male	Normal size and margination were present in the kidneys. A normal 1:3 cortex / medulla ratio was maintained. The medulla and cortices were uniform in texture with some increased echogenicity and mild loss of corticomedullary symmetry and definition. No evidence of pelvic dilation was present. Pinpoint medullary mineral was present in both kidneys. The left kidney measured 4.5 cm. The right kidney measured 4.3 cm in length.
AGE	Adrenal Glands
6 Months	The left adrenal gland was uniform in size and contour with a uniformly hypoechoic parenchyma. The left adrenal gland measured 0.55 cm width at the caudal pole and 0.47 cm width at the cranial pole.
WEIGHT	The right adrenal gland was uniform in size and contour with a uniformly hypoechoic parenchyma. The right adrenal gland measured 0.54 cm width at the caudal pole and 0.72 cm width at the cranial pole.
20.5 Pounds	Spleen
INTERPRETED BY	The spleen exhibited a finely textured and homogenous parenchyma which was hyperechoic to the liver and renal cortical parenchyma. The capsule was smooth and regular without apparent expansion. The splenic vasculature at the hilus was normal in volume with no evidence of congestion or thrombosis. Acute to chronic inflammatory, neoplastic, or benign parenchyma changes were not noted.
R. McKenzie Daniel, DVM, DABVP (Canine and Feline)	Liver
IMAGING PERFORMED BY	The liver was enlarged in size with multifocal to variably sized to expansive nonhomogeneous intraparenchymal masses to macronodules. An example of liver mass measured 4.8 cm in diameter.
Shari Reffi, CVT	The gallbladder was non-distended in size with thin walls and primarily anechoic luminal content. The cystic and common bile ducts were normal.
HOSPITAL NAME	Gastrointestinal
Newton VH	The stomach presented intact wall layering with a normal wall layer ratio. The lumen of the stomach contained moderate variably hyperechoic ingesta, exhibiting distal acoustic shadowing without signs of obstruction or foreign material.
REFERRING VET	The visualized segments of small intestine exhibited intact wall layering with 1:3 muscularis/mucosa ratio. The lumen of the small intestine was empty without evidence of mechanical/metabolic ileus.
Dr. Verhalen	
INVOICE	
16354	
DATE	
6/27/22	



PATIENT

Moose Roman

A moderately sized descending colon to colorectal mass was present in the mid caudal abdomen and dorsal to the urinary bladder. The mass exhibited marked descending colon to colorectal mural hypertrophy, nonhomogeneous mural echogenicity and loss of discernable wall layering, measuring at least 5.0 cm in diameter with wall width measuring up to 1.4 cm. Non-formed feces and mildly prominent yet intact wall layering was noted in the colon proximal to the mass.

SPECIES

Canine

Pancreas

The parenchyma of the left limb, body and right limb of the pancreas presented isoechoic to the adjacent omental fat. A normal curvilinear capsule contour of the pancreas was present. The visible pancreatic duct was normal. No signs of active inflammation or neoplastic disease was evident.

BREED

Basenji

Free Abdomen

SEX

Neutered Male

A solitary to possible intermittent mid to caudal abdominal mesenteric lymphadenopathy, exhibiting borderline to abnormal width to length ratio \geq or equal to 0.5. An example of lymph node measured 2.1 cm x 1.2 cm. No evidence of peritoneal free fluid.

AGE

6 Months

ULTRASONOGRAPHIC FINDINGS

- Descending colon to colorectal mural mass
- Multifocal hepatic intraparenchymal masses to macronodules
- Focal to possible intermittent mid to caudal abdominal mesenteric lymphadenopathy
- Gastric ingesta- nonspecific, postprandial presentation, potential for some degree of gastric hypomotility if documented NPO.

WEIGHT

20.5 Pounds

INTERPRETED BY

R. McKenzie Daniel,
DVM, DABVP
(Canine and Feline)

INTERPRETATION OF THE FINDINGS & FURTHER RECOMMENDATIONS

Although sampling is required for further prognosis, the descending colon to colorectal mass is most consistent with neoplastic criteria.

IMAGING PERFORMED BY

Shari Reffi, CVT

The multiple hepatic masses to macronodules are consistent with hepatic metastasis pattern and with high concern for mid to caudal abdominal lymphatic metastasis.

HOSPITAL NAME

Newton VH

Assuming normal clotting status, ultrasound guided FNA of the colon mass and liver mass/micronodule could be considered for screening cytology with potential for oncology consult. Unfortunately, this case appears to be nonsurgical.

Monitoring for evidence of gastric emptying is suggested.

REFERRING VET

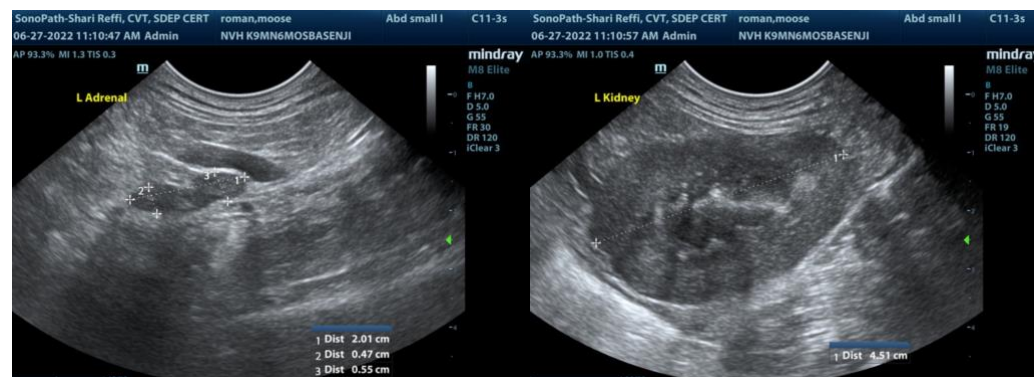
Dr. Verhalen

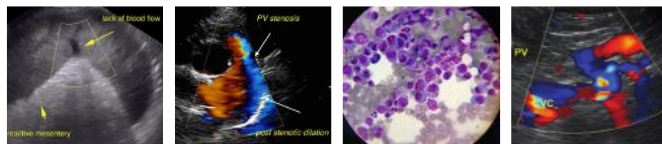
INVOICE

16354

DATE

6/27/22





PATIENT

Moose Roman

SPECIES

Canine

BREED

Basenji

SEX

Neutered Male

AGE

6 Months

WEIGHT

20.5 Pounds

INTERPRETED BY

R. McKenzie Daniel,
DVM, DABVP
(Canine and Feline)

IMAGING PERFORMED BY

Shari Reffi, CVT

HOSPITAL NAME

Newton VH

REFERRING VET

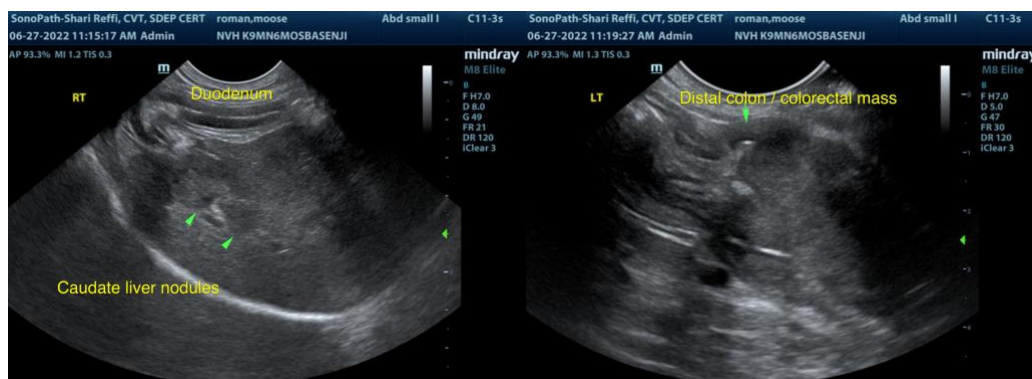
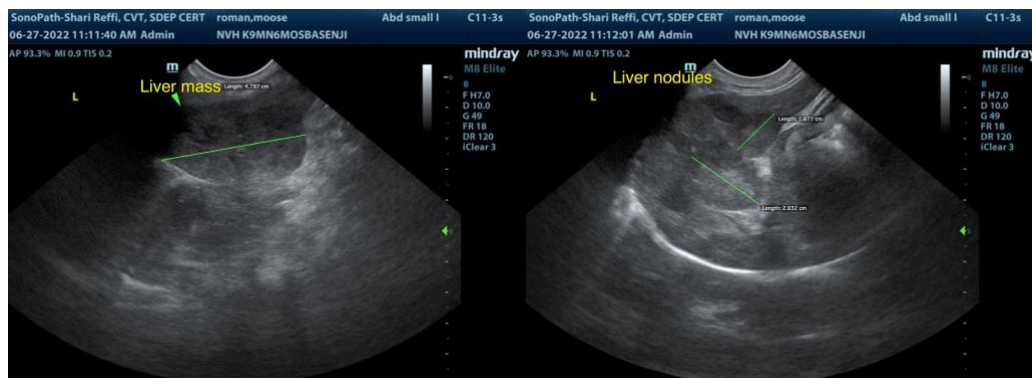
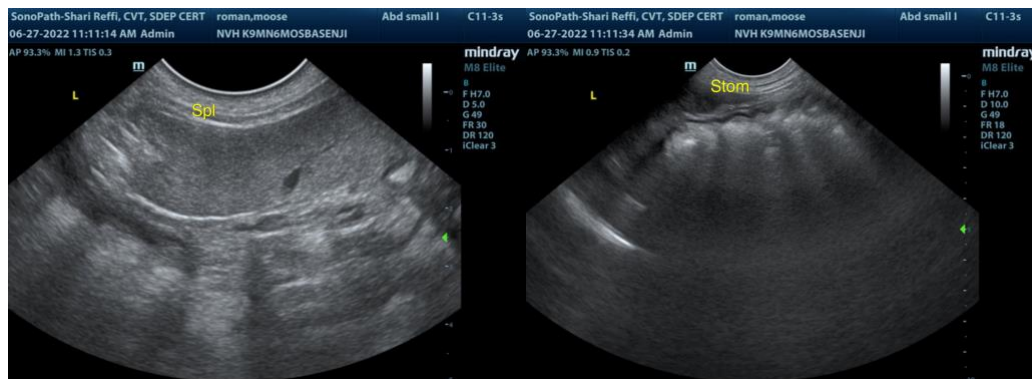
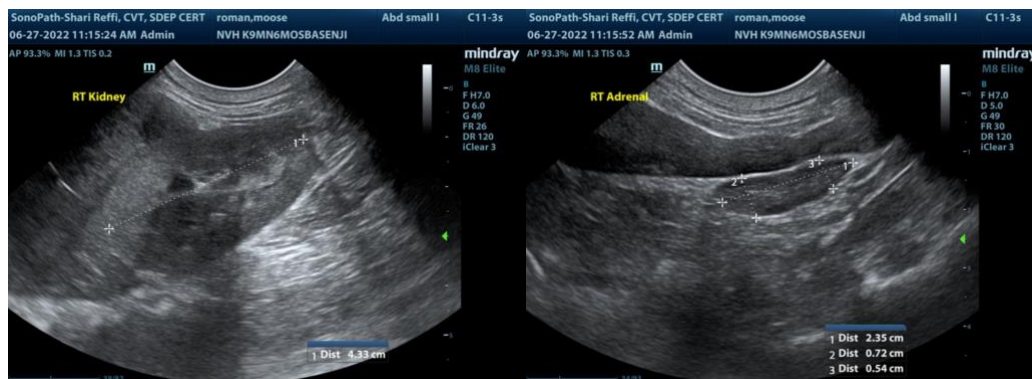
Dr. Verhalen

INVOICE

16354

DATE

6/27/22





PATIENT

Moose Roman

SPECIES

Canine

BREED

Basenji

SEX

Neutered Male

AGE

6 Months

WEIGHT

20.5 Pounds

INTERPRETED BY

R. McKenzie Daniel,
DVM, DABVP
(Canine and Feline)

IMAGING PERFORMED BY

Shari Reffi, CVT

HOSPITAL NAME

Newton VH

REFERRING VET

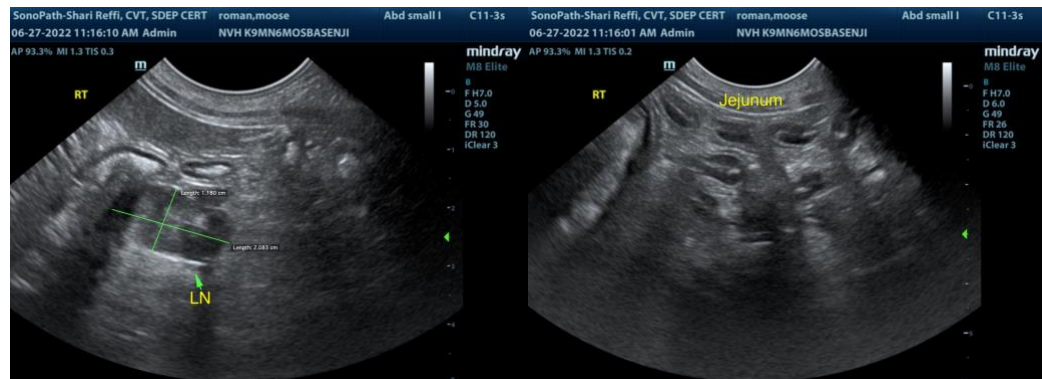
Dr. Verhalen

INVOICE

16354

DATE

6/27/22



The information and recommendations provided are based on the images presented by the referring veterinarian. No evaluation can be communicated regarding pathology that was not visible in the image/video clips provided.

Thank you for this referral. If the clinical or image interpretation does not parallel your findings or if I can be of any further assistance please contact me.

R. McKenzie Daniel, DVM, DABVP (Canine / Feline Practice)
info@SonoPath.com