


PATIENT

Hazel Byers

PRESENTING CLINICAL SIGNS

elevated liver enzymes hx of hypertension

SPECIES

Canine

ULTRASONOGRAPHIC EXAMINATION OF THE HEART AND ABDOMEN
BREED

Greyhound

| CANINE CARDIAC PARAMETERS | MR VMAX (m/s) | TR VMAX (m/s) | LA/AO (Boon method) | LA/AO (Heart Base; Swe) | FS (%) | EF (%) | EPSS (cm) |
|---------------------------|---------------|---------------|---------------------|-------------------------|---------------------------------|--|--|
| NORMAL PARAMETER | 4.5-5.5 | <2.7 | 1.3 | <1.3 | 28-40 | 40-100 | <0.6 |
| PATIENT | | | | 1.32 | 43.7 | 75.1 | 0.3 |
| CANINE CARDIAC PARAMETERS | HR (BPM) | AV VMAX (m/s) | PV MAX (m/s) | BODY WEIGHT (kg) | LA 2D short axis Base view (cm) | LVIDd Avg; 2D and m-mode short axis (cm) | LVIDs Avg; 2D and m-mode short axis (cm) |
| NORMAL PARAMETER | 50-100 | 0.7-1.7 | 0.7-1.6 | | | | |
| PATIENT | 162 | 1.2 | 1.1 | | 4.2 | 4.4 | |

SEX

FS

AGE

11

WEIGHT

63.5

Cardiac Presentation

The echocardiogram in this patient demonstrated normal left atrial size based on 3 separate methods of LA evaluation. The cranial and caudal mitral valve leaflets presented normal linear structure, extension in systole, and union in diastole with normal kinesis. The left ventricle presented thicknesses with linear contour and was not dilated nor restricted. The myocardium presented normal echogenicity without subjective evidence of significant fibrotic or ischemic disease. Contractility of the ventricular walls was adequate and in normal range for this patient evidenced by the fractional shortening measurement and subjective evaluation of the different regions of the myocardium. The left ventricular outflow tract demonstrated normal laminar flow and subjective structural integrity. The right atrium and auricle revealed normal size, structure and content. No evidence of masses was noted. Tricuspid valvular assessment demonstrated adequate linear morphology and kinesis. The right ventricle was of normal size (1/3 diameter of LV), chordae structure, myocardial echogenicity and thickness. Pulmonary outflow tract assessment revealed normal valve structure, laminar flow, and diameter (approx. 1:1 pa/ao ratio). No visible pericardial or free pleura fluid was noted. The cranial mediastinum and pericardial and extra-cardiac regions were free of masses in the visible window.

INTERPRETED BY

 R. McKenzie Daniel,
 DVM, DABVP
 (Canine and Feline)

IMAGING PERFORMED BY

Jenn

HOSPITAL NAME

 Rockaway Animal
 Hospital

REFERRING VET

Dr. Maniar

Urinary System

The urinary bladder, trigone, cystourethral junction, and visible pelvic urethra to a depth of 3 cm exhibited normal thickness and tone. Anechoic urine was present in the lumen with no uroliths or sediment. The ureteral papillae were normal. The ureters were not visible which is normal. No evidence of inflammatory or neoplastic changes were noted.

INVOICE

10982ag

DATE

06/27/2022

Normal size and margination was present in the kidneys. A normal 1:3 cortex / medulla ratio was maintained. The medulla and cortices were uniform in texture with some increased echogenicity and loss of corticomedullary symmetry and definition expected for the age of the patient. No evidence of



| | |
|--|---|
| PATIENT | pelvic dilation was present. The left kidney measured 6.8 cm in length. The right kidney measured 7.9 cm in length. |
| Hazel Byers | |
| | The area of the aortic trifurcation was free of pathology. |
| SPECIES | Adrenal Glands |
| Canine | The left adrenal gland was mildly prominent in size with symmetrical capsule contour and ill-defined nonhomogeneous to mild mixed echogenic parenchyma. No overt evidence of parenchymal mineralization. The left adrenal gland measured 1.0 cm width at the caudal pole and 3.0 cm length. The right adrenal gland was indistinctly visualized subjectively measuring 0.65 cm at the caudal pole. |
| BREED | |
| Greyhound | Spleen |
| | The spleen exhibited a finely textured and homogenous parenchyma which was hyperechoic to the liver and renal cortical parenchyma. The capsule was smooth and regular without apparent expansion. The splenic vasculature at the hilus was normal in volume with no evidence of congestion or thrombosis. Acute to chronic inflammatory, neoplastic, or benign parenchyma changes were not noted. |
| SEX | |
| FS | |
| AGE | Liver |
| 11 | The liver presented enlarged in size. The parenchyma of the liver was subjectively normal in echogenicity compared to the spleen and renal cortices. The liver parenchyma was uniform with a mildly coarse echotexture. The capsule of the liver was symmetrically rounded to mildly swollen in margination. The hepatic and portal vasculature were normal in appearance without signs of congestion. The gallbladder was non-distended in size with primarily anechoic luminal content. The cystic and common bile ducts were normal. |
| WEIGHT | |
| 63.5 | |
| INTERPRETED BY | Gastrointestinal |
| R. McKenzie Daniel, DVM, DABVP (Canine and Feline) | The stomach presented intact wall layering with a normal wall layer ratio. The lumen of the stomach was empty with no signs of ileus, obstruction or foreign material. |
| | The small intestine presented intact wall layering with 1:3 muscularis/mucosa ratio. The lumen of the small intestine was empty with no signs of ileus, obstruction or foreign material. |
| IMAGING PERFORMED BY | Normal visible colon wall layers were present with apparent formed feces in lumen. |
| Jenn | Pancreas |
| HOSPITAL NAME | The parenchyma of the left limb, body and right limb of the pancreas presented isoechoic to the adjacent omental fat. A normal curvilinear capsule contour of the pancreas was present. The visible pancreatic duct was normal. No signs of active inflammation or neoplastic disease was evident. |
| Rockaway Animal Hospital | |
| REFERRING VET | Free Abdomen |
| Dr. Maniar | No overt lymphadenopathy or peritoneal effusion was present. |
| INVOICE | ULTRASONOGRAPHIC FINDINGS |
| 10982ag | <ul style="list-style-type: none"> • Normal echocardiogram • Mildly prominent to nonhomogeneous left adrenal gland • Vacuolar hepatopathy pattern • Mild age related kidneys |
| DATE | |
| 06/27/2022 | |



PATIENT

Hazel Byers

INTERPRETATION OF THE FINDINGS & FURTHER RECOMMENDATIONS

No evidence of structural or functional cardiomyopathy.

SPECIES

Canine

The mildly prominent left adrenal gland was nonspecific with considerations including adenomatous change or benign hyperplasia while the possibility of emerging neoplastic criteria i.e.

BREED

Greyhound

pheochromocytoma given the history of hypertension or adenocarcinoma cannot be excluded. If persistent hypertension a urine catecholamine level to Marshfield Labs could be considered. A full adrenal workup is suggested if clinical signs consistent with Cushing's syndrome are present. Sonographic monitoring of the left adrenal gland for evidence of progression with initial recheck in 4-6 weeks is suggested.

SEX

FS

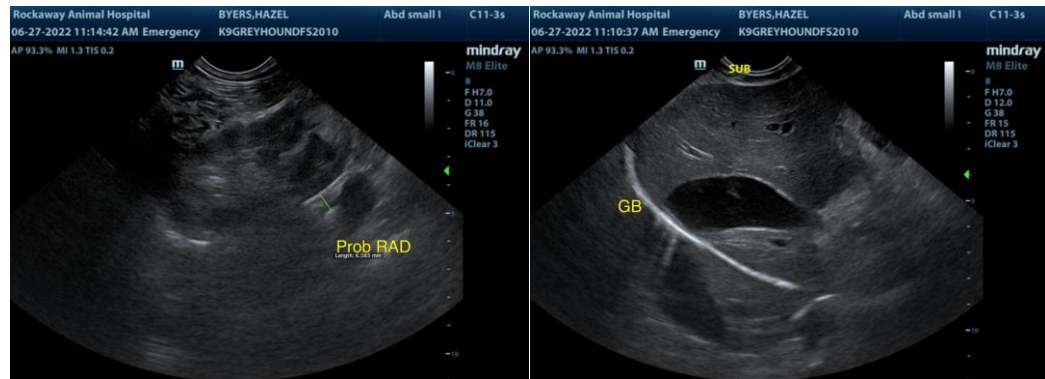
Empirical hepatosupportive medications such as Denamarin and Ursodiol may prove beneficial.

AGE

11

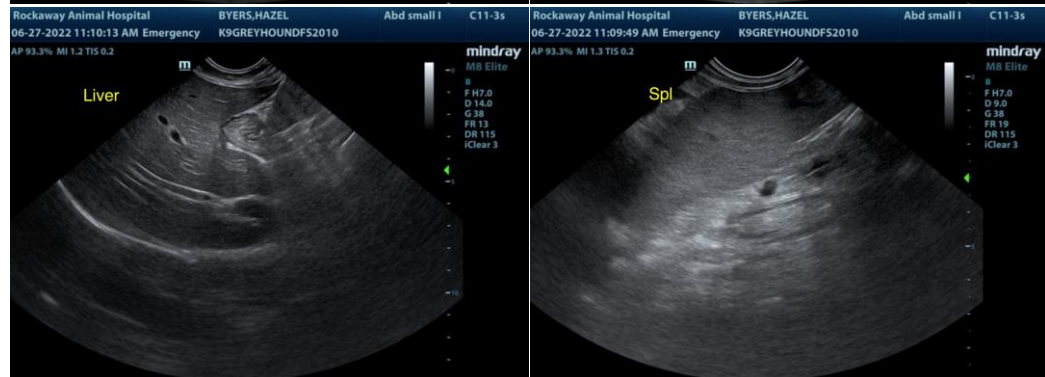
WEIGHT

63.5



INTERPRETED BY

R. McKenzie Daniel,
DVM, DABVP
(Canine and Feline)

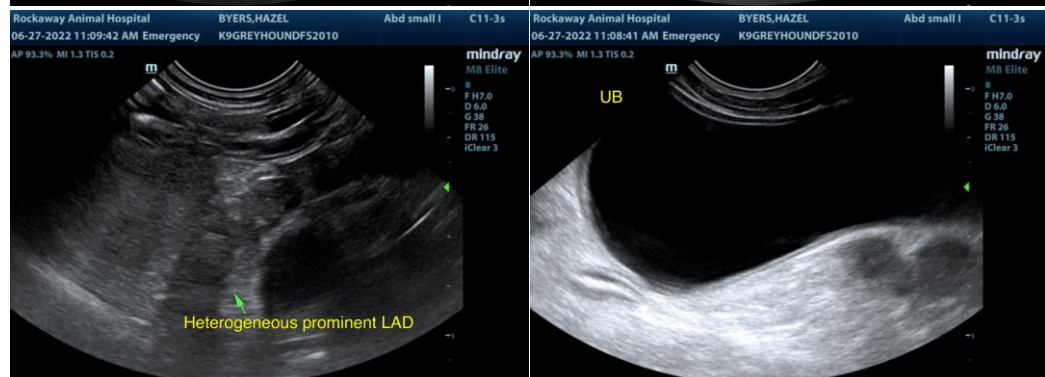


IMAGING PERFORMED BY

Jenn

HOSPITAL NAME

Rockaway Animal Hospital



REFERRING VET

Dr. Maniar

INVOICE

10982ag

DATE

06/27/2022



PATIENT

Hazel Byers

SPECIES

Canine

BREED

Greyhound

SEX

FS

AGE

11

WEIGHT

63.5

INTERPRETED BY

R. McKenzie Daniel,
DVM, DABVP
(Canine and Feline)

IMAGING PERFORMED BY

Jenn

HOSPITAL NAME

Rockaway Animal
Hospital

REFERRING VET

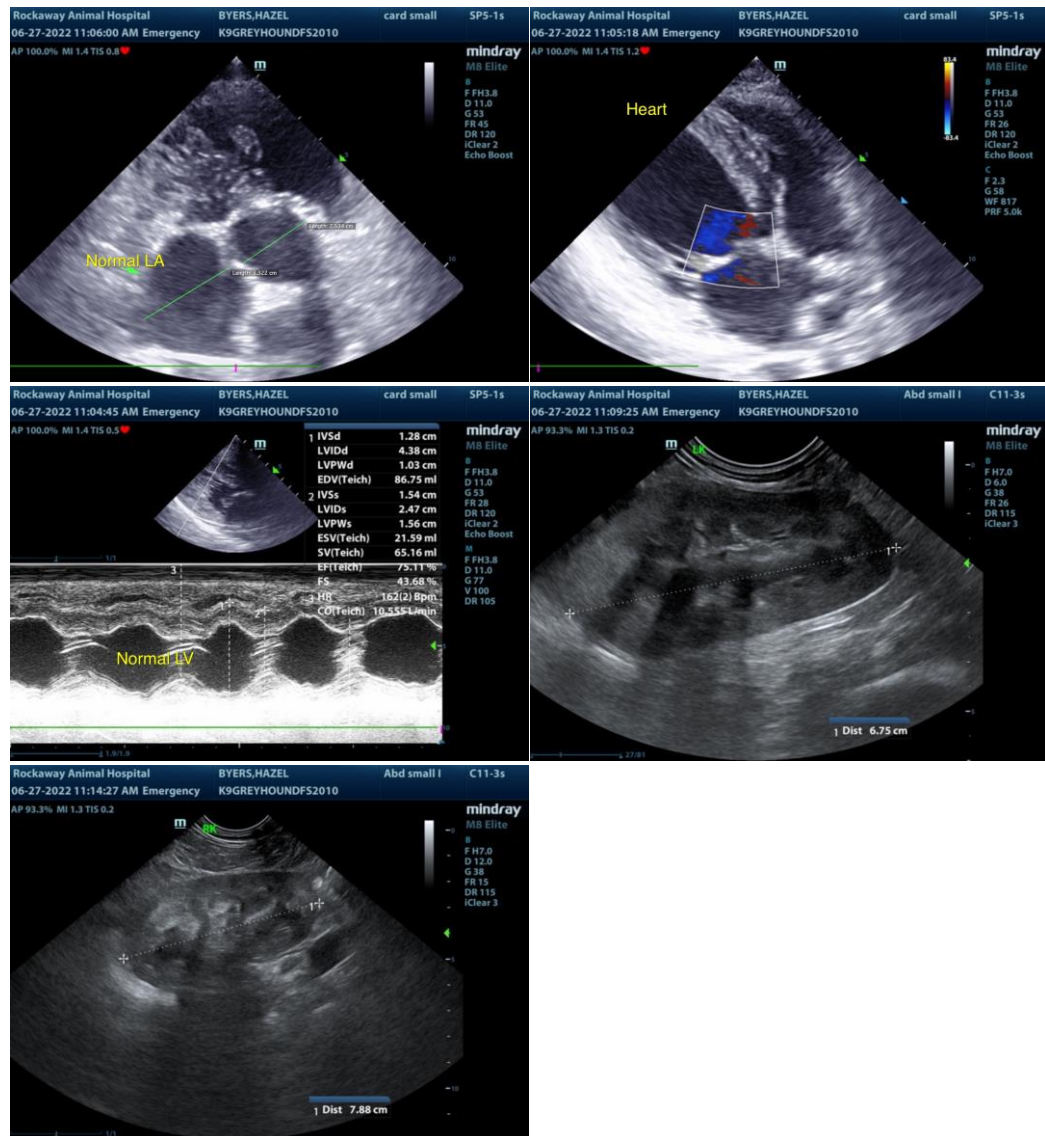
Dr. Maniar

INVOICE

10982ag

DATE

06/27/2022



The information and recommendations provided are based on the images presented by the referring veterinarian/sonographer. No evaluation can be communicated regarding pathology that was not visible in the image/video clips provided.

Thank you for this referral. If the clinical or image interpretation does not parallel your findings or if I can be of any further assistance please contact me.

R. McKenzie Daniel, DVM, DABVP (Canine / Feline Practice)

info@SonoPath.com