



**PATIENT**

"Brooklyn" Giardina

**SPECIES**

Feline

**BREED**

DSH

**SEX**

FS

**AGE**

7yr

**WEIGHT**

14.1lb

**PRESENTING CLINICAL SIGNS**

Grade 3/6 systolic murmur along left side/sternum. ProBNP 4 60 pmol/L (0-100). No current meds.

Abnormal PE/Chem/CBC/UA Results: Elevated chol., CPK, low neuts, normal WBC overall.

**ULTRASONOGRAPHIC EXAMINATION OF THE HEART**

FELINE CARDIAC PARAMETERS	BODY WEIGHT (kg)	HR (BPM)	IVSd (cm)	LVIDd (cm)	LVWd (cm)	FS (%)	EF (%)
NORMAL PARAMETER	-----	150-240	0.3-0.6	1.0-2.1	0.25-0.6	35-67	80-100
PATIENT		127	0.63	1.4	0.63	50	82
FELINE CARDIAC PARAMETERS	LA/AO (Boon)	LA/AO HEART BASE (Sisson)	LA 2D 4-chamber long axis AS to FW (Sisson) (cm)		LVOT VEL. (m/s)	RVOT VEL. (m/s)	IVRT (m/)
NORMAL PARAMETER	<1.5	0.88-1.79	0.7-1.7		<1.6	<1.3	40-60
PATIENT		1.4	1.3		1.3	1.4	

Adapted from June Boon, Veterinary Echocardiography, 1998  
Sisson D et al. JVIM 1991; 5: 232, Jacobs et al. Am J Vet Res 1985; 46:1705

**INTERPRETED BY**

R. McKenzie Daniel, DVM, DABVP (Canine and Feline)

**IMAGING PERFORMED BY**

Kelly Vazquez

**HOSPITAL NAME**

Midland Park Veterinary Hospital

**REFERRING VET**

Dr. John Shokoff

**Cardiac Presentation**

The left ventricular wall was borderline increased in dimension with mild increased endocardium echogenicity. Minor increased prominence of the basilar aspect of the interventricular septum was present. Mildly prominent to remodeled papillary muscle. The LA was normal in size and dimension with anechoic content. No evidence of LA spontaneous contrast. The RA and RV appear normal. The mitral valve was overtly normal in structure and mobility. No overt evidence of systolic anterior motion of the mitral valve. Trace MR was present on Doppler. Blood flow through the LVOT and RVOT was normal in measured velocity with subjective mild dynamic to turbulent LV outflow on color Doppler. No overt TR.

No evidence of pericardial or pleural effusion. No cardiac tumors. Overtly normal heart rate and rhythm.

**ULTRASONOGRAPHIC FINDINGS**

- Borderline prominent/thickened LV wall.
- Normal LA.
- Trace MR.

**INTERPRETATION OF THE FINDINGS & FURTHER RECOMMENDATIONS**

The borderline prominent to thickened LV wall may suggest emerging HCM criteria which is a rule out diagnosis one patient is confirmed euthyroid and normotensive. Assessment of T4 and systemic BP if not done is recommended. Overall, the heart appears to be compensated without evidence of left/right heart chamber enlargement.

The murmur is suspected to be a physiological flow murmur potentially secondary to subjective mildly

**INVOICE**

14227ag

**DATE**

06/26/2023



**PATIENT**

"Brooklyn" Giardina

dynamic to turbulent LV outflow on color Doppler. No overt indication for cardiac medications.

**SPECIES**

Feline

Conservative monitoring of the murmur and serial sonographic monitoring is required for further assessment.

**BREED**

DSH

**SEX**

FS

**AGE**

7yr

**WEIGHT**

14.1lb

**INTERPRETED BY**

R. McKenzie Daniel,  
DVM, DABVP  
(Canine and Feline)

**IMAGING PERFORMED BY**

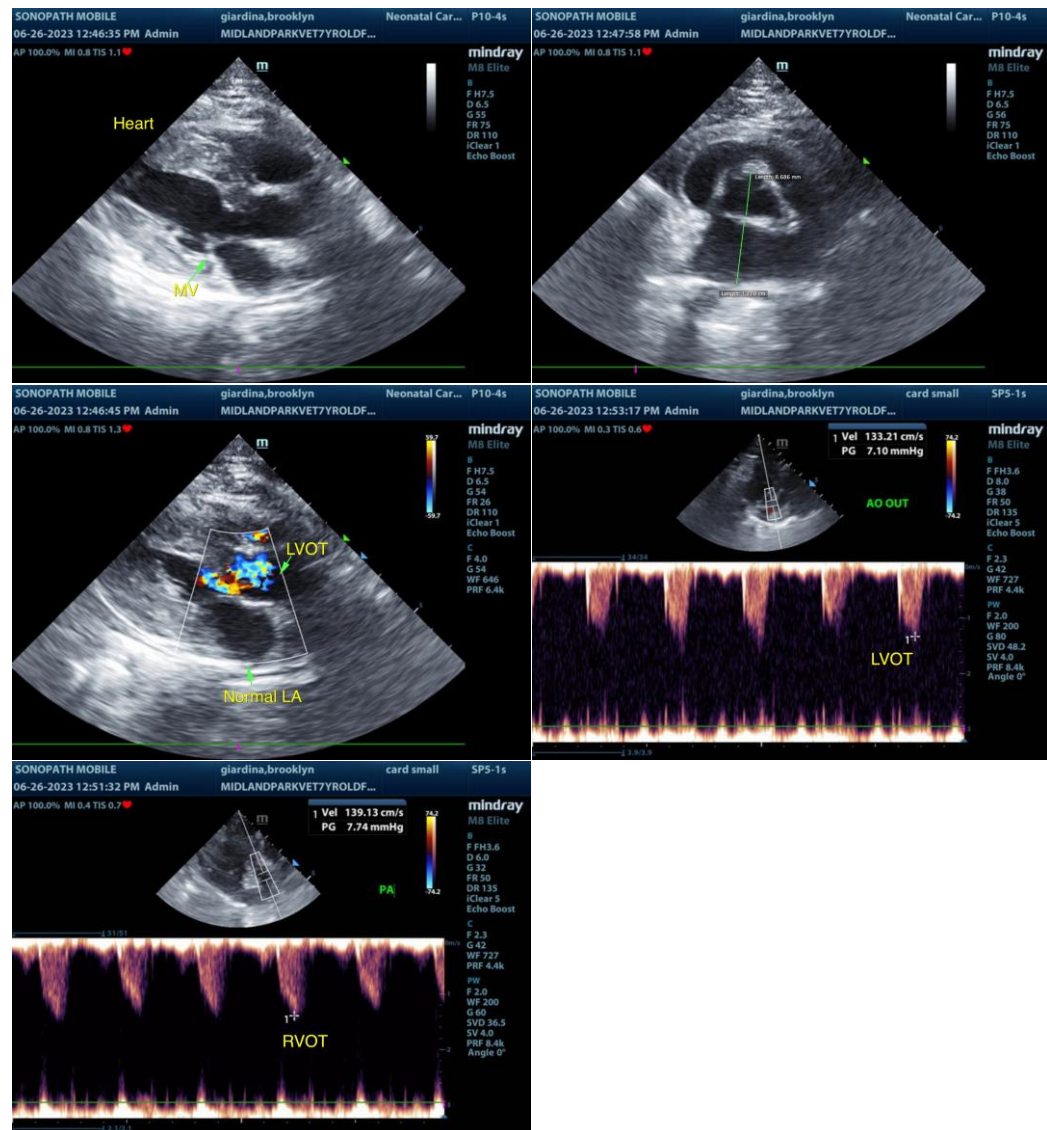
Kelly Vazquez

**HOSPITAL NAME**

Midland Park  
Veterinary Hospital

**REFERRING VET**

Dr. John Shokoff



**INVOICE**

14227ag

The information and recommendations provided are based on the images presented by the referring veterinarian/sonographer. No evaluation can be communicated regarding pathology that was not visible in the image/video clips provided.

**DATE**

06/26/2023

Thank you for this referral. If the clinical or image interpretation does not parallel your findings or if I can be of any further assistance, please contact me.



**PATIENT**

"Brooklyn" Giardina

R. McKenzie Daniel, DVM, DABVP (Canine/Feline Practice)  
[info@sonopath.com](mailto:info@sonopath.com)

**SPECIES**

Feline

**BREED**

DSH

**SEX**

FS

**AGE**

7yr

**WEIGHT**

14.1lb

**INTERPRETED BY**

R. McKenzie Daniel,  
DVM, DABVP  
(Canine and Feline)

**IMAGING  
PERFORMED BY**

Kelly Vazquez

**HOSPITAL NAME**

Midland Park  
Veterinary Hospital

**REFERRING VET**

Dr. John Shokoff

**INVOICE**

14227ag

**DATE**

06/26/2023