**PATIENT**

Xena Reinert

SPECIES

Canine

BREED

German Shepherd

SEX

FS

AGE

9 yr

WEIGHT

65 lb

INTERPRETED BYR. McKenzie Daniel,
DVM, DABVP
(Canine and Feline)**IMAGING PERFORMED BY**

Rachel Runnells RVT

HOSPITAL NAME

SVS Imaging KC

REFERRING VET

Dr. John Lyle

INVOICE

10955ag

DATE

06/24/2022

PRESENTING CLINICAL SIGNS

History: Diarrhea since 6/21/22, but not vomiting. Had been eating chicken and rice, but eating normal food now.

Abnormal PE/Chem/CBC/UA Results: T - 103.5, MM pk/moist. Rectal exam - liquid stool. Does not appear dehydrated. Rads show something in dorsal mid-abdomen, that looks like tumor or large LN.

ULTRASONOGRAPHIC EXAMINATION OF THE ABDOMEN**Urinary System**

The urinary bladder, trigone, cystourethral junction, and visible pelvic urethra exhibited normal thickness and tone. Anechoic urine was present in the lumen with no uroliths or sediment. The ureteral papillae were normal. The ureters were not visible which is normal. No evidence of inflammatory or neoplastic changes were noted.

Normal size and margination were present in the kidneys. A normal 1:3 cortex / medulla ratio and normal corticomedullary definition were maintained. The echogenicity of the cortex was similar to or slightly less than normal liver parenchyma while the medulla echogenicity was hypoechoic to the cortex with no evidence of pelvic dilation. The left kidney measured 6.9 cm in length. The right kidney measured 6.1 cm in length.

The area of the aortic trifurcation was free of pathology.

Adrenal Glands

The left adrenal gland was uniform in size and contour with a uniformly hypoechoic parenchyma. The left adrenal gland measured 0.73 cm width at the caudal pole and 0.70 cm width at the cranial pole. The right adrenal gland was uniform in size and contour with a uniformly hypoechoic parenchyma. The right adrenal gland measured 0.67 cm width at the caudal pole.

Spleen

The spleen exhibited a finely textured and homogenous parenchyma which was hyperechoic to the liver and renal cortical parenchyma. The capsule was smooth and regular without apparent expansion. The splenic vasculature at the hilus was normal in volume with no evidence of congestion or thrombosis. Acute to chronic inflammatory, neoplastic, or benign parenchyma changes were not noted.

Liver

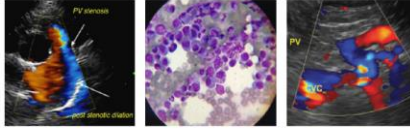
The liver was subjectively normal in size, structure, and contour. The liver parenchyma was uniform and hypoechoic to the spleen with a mild coarse echotexture. The hepatic and portal vasculature were normal in appearance without signs of congestion. The gallbladder was non-distended in size with thin walls and primarily anechoic luminal content. The cystic and common bile ducts were normal.

Gastrointestinal

The stomach presented intact wall layering with a normal wall layer ratio. The lumen of the stomach was empty with no signs of ileus, obstruction or foreign material.

The small intestine presented intact wall layering with 1:3 muscularis/mucosa ratio. The lumen of the small intestine was empty with no signs of ileus, obstruction or foreign material.

Normal visible colon wall layers were present with apparent formed feces in lumen.

IMAGING PERFORMED BYSVS Mobile Imaging KC 816-401-5010
svsimagingkc@gmail.com**PATIENT**

Xena Reinert

SPECIES

Canine

BREED

German Shepherd

SEX

FS

AGE

9 yr

WEIGHT

65 lb

INTERPRETED BYR. McKenzie Daniel,
DVM, DABVP
(Canine and Feline)**IMAGING
PERFORMED BY**

Rachel Runnells RVT

HOSPITAL NAME

SVS Imaging KC

REFERRING VET

Dr. John Lyle

INVOICE

10955ag

DATE

06/24/2022

Pancreas

The parenchyma of the left limb, body and right limb of the pancreas presented isoechoic to the adjacent omental fat. A normal curvilinear capsule contour of the pancreas was present. The visible pancreatic duct was normal. No signs of active inflammation or neoplastic disease was evident.

Free Abdomen

No overt lymphadenopathy or peritoneal effusion was present.

ULTRASONOGRAPHIC FINDINGS

- Overtly normal GI tract and colon

INTERPRETATION OF THE FINDINGS & FURTHER RECOMMENDATIONS

No evidence of structural abdominal pathology. At times the sonographic presentation of the GI tract does not always correlate with present GI signs. In a patient with potential chronic GI signs, considerations may include dysbiosis/antibiotic responsive diarrhea, (potentially a top differential given the breed), dietary intolerance, mild pancreatitis, structurally insignificant IBD or infectious enterocolitis. If not done, a fresh fecal analysis to rule out parasitic ova/giardia is suggested. A GI panel to include PLI/TLI/Cobalamin/Folate is recommended. Empirically, a limited antigen or hydrolyzed diet trial with potential long term dietary therapy, prophylactic deworming (Panacur 50 mg/kg SID x 5 consecutive days with repeat protocol in 3 weeks even if fecal testing is negative), high colony count probiotic (Provable or Visbiome), antibiotic trial and as needed gastrointestinal support with assessment of clinical response may prove beneficial. Intestinal biopsies may be indicated if GI signs continue despite empirical therapy. Although considered unlikely, a resting cortisol level to rule out occult Addison's disease could be considered. No evidence of intra-abdominal neoplastic criteria, masses or lymphadenopathy.

IMAGING PERFORMED BY

SVS Mobile Imaging KC 816-401-5010
svsimagingkc@gmail.com



Clinical Sonography & Telectology

EDUCATIONAL TELECONSULTATION SERVICES™

1-800-838-4268 info@sonopath.com SonoPath.com

PATIENT

Xena Reinert

SPECIES

Canine

BREED

German Shepherd

SEX

FS

AGE

9 yr

WEIGHT

65 lb

INTERPRETED BY

R. McKenzie Daniel,
DVM, DABVP
(Canine and Feline)

IMAGING PERFORMED BY

Rachel Runnells RVT

HOSPITAL NAME

SVS Imaging KC

REFERRING VET

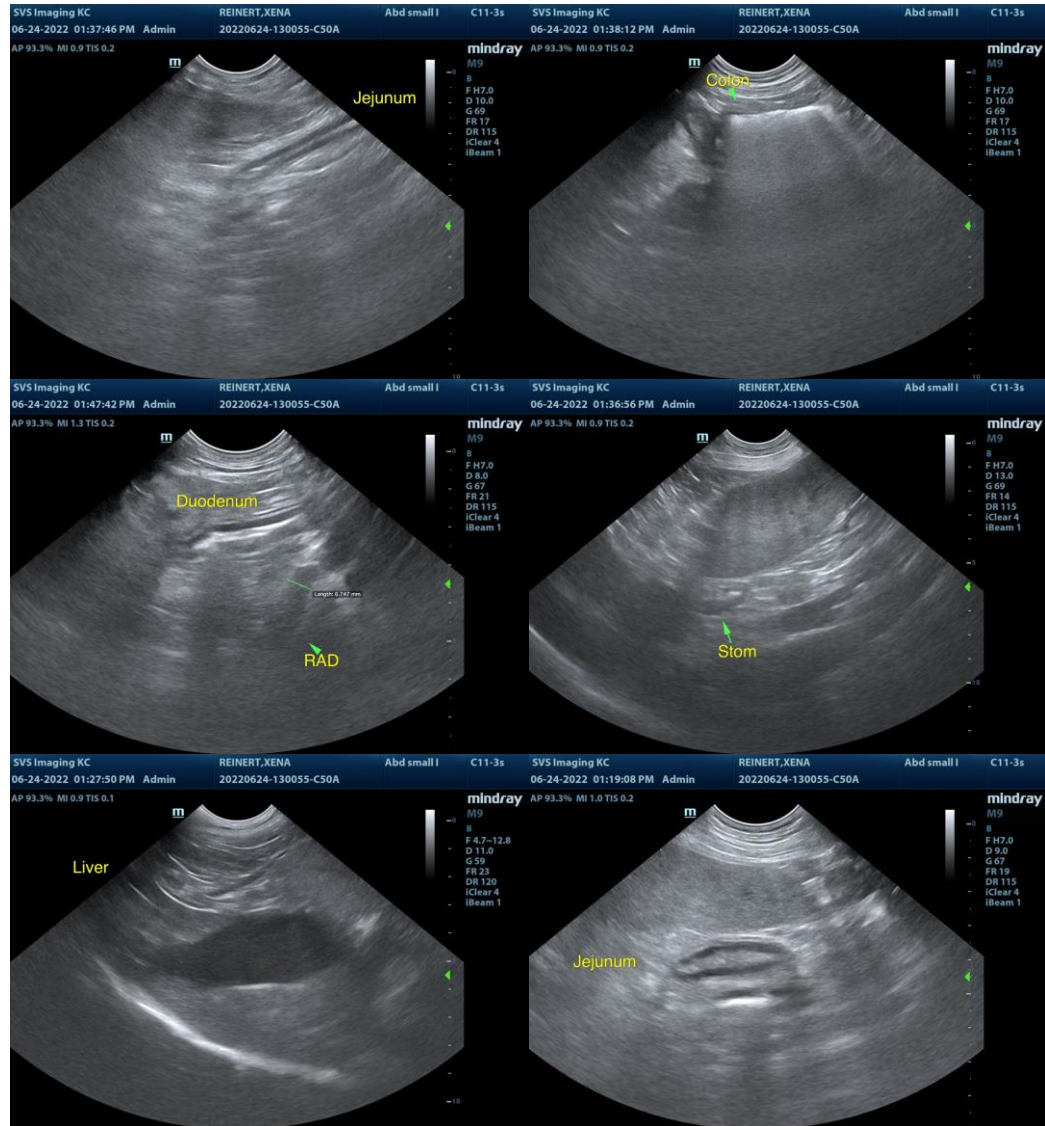
Dr. John Lyle

INVOICE

10955ag

DATE

06/24/2022



IMAGING PERFORMED BY

SVS Mobile Imaging KC 816-401-5010
svsimagingkc@gmail.com



Clinical Sonography & Telectology

EDUCATIONAL TELECONSULTATION SERVICES™

1-800-838-4268 info@sonopath.com SonoPath.com

PATIENT

Xena Reinert

SPECIES

Canine

BREED

German Shepherd

SEX

FS

AGE

9 yr

WEIGHT

65 lb

INTERPRETED BY

R. McKenzie Daniel,
DVM, DABVP
(Canine and Feline)

IMAGING PERFORMED BY

Rachel Runnells RVT

HOSPITAL NAME

SVS Imaging KC

REFERRING VET

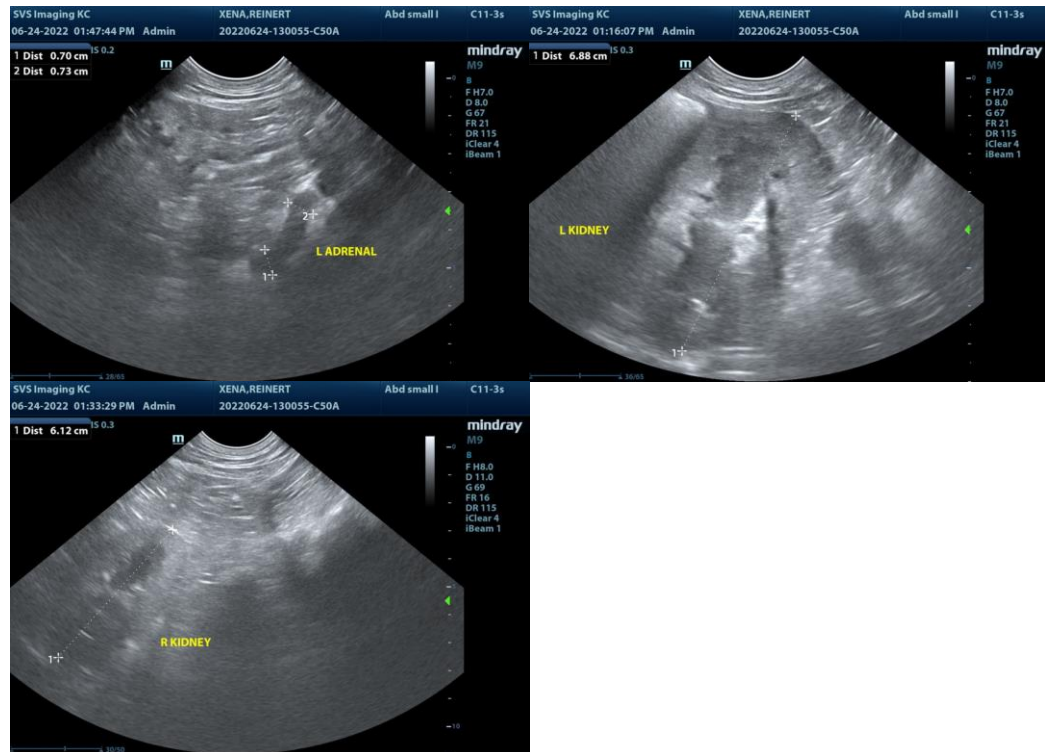
Dr. John Lyle

INVOICE

10955ag

DATE

06/24/2022



The information and recommendations provided are based on the images presented by the referring veterinarian/sonographer. No evaluation can be communicated regarding pathology that was not visible in the image/video clips provided.

Thank you for this referral. If the clinical or image interpretation does not parallel your findings or if I can be of any further assistance please contact me.

R. McKenzie Daniel, DVM, DABVP (Canine / Feline Practice)

info@SonoPath.com