



PATIENT PRESENTING CLINICAL SIGNS

Raven Goodman History: Blood noted in urinalysis, clinically normal USG 1.019 PH 8.0 1+ occult blood 11-20 RBCs

ULTRASONOGRAPHIC EXAMINATION OF THE ABDOMEN

SPECIES

Canine

Urinary System

The urinary bladder, trigone, cystourethral junction, and visible pelvic urethra to a depth of 3 cm exhibited normal thickness and tone. Anechoic urine was present in the lumen with no uroliths or sediment. The ureteral papillae were normal. The ureters were not visible which is normal. No evidence of inflammatory or neoplastic changes were noted.

BREED

Lab

Normal size was present in the kidneys with subtle nonspecific asymmetric left kidney margination. A normal 1:3 cortex / medulla ratio and normal corticomedullary definition were maintained. The echogenicity of the cortex was similar to or slightly less than normal liver parenchyma while the medulla echogenicity was hypoechoic to the cortex with no evidence of pelvic dilation. The left kidney measured 6.3 cm in length. The right kidney measured 6.7 cm in length.

SEX

FS

AGE

5 yr

The area of the aortic trifurcation was free of pathology.

No evidence of pathology in the area of the uterine remnant.

Adrenal Glands

WEIGHT

80lb

The left adrenal gland was uniform in size and contour with a uniformly hypoechoic parenchyma. The left adrenal gland measured 0.66 cm width at the caudal pole and 2.7 cm. The right adrenal gland was uniform in size and contour with a uniformly hypoechoic parenchyma. The right adrenal gland measured 0.81 cm width at the caudal pole and 3.2 cm.

INTERPRETED BY

R. McKenzie Daniel,
DVM, DABVP
(Canine and Feline)

Spleen

The spleen exhibited a finely textured and homogenous parenchyma which was hyperechoic to the liver and renal cortical parenchyma. The capsule was smooth and regular without apparent expansion. The splenic vasculature at the hilus was normal in volume with no evidence of congestion or thrombosis. Acute to chronic inflammatory, neoplastic, or benign parenchyma changes were not noted.

IMAGING PERFORMED BY

Rebekah Jakum, CVT
ARDMS/RVT

Liver

The liver was subjectively normal in size, structure, and contour. The liver parenchyma was uniform and hypoechoic to the spleen with a mild coarse echotexture. The hepatic and portal vasculature were normal in appearance without signs of congestion. The gallbladder was non-distended in size with thin walls and primarily anechoic luminal content. The cystic and common bile ducts were normal.

HOSPITAL NAME

Bean Acres MVC

REFERRING VET

Dr. Mirabile

Gastrointestinal

The stomach presented intact wall layering with a normal wall layer ratio. The lumen of the stomach was empty with no signs of ileus, obstruction or foreign material.

INVOICE

10938ag

The small intestine presented intact wall layering with 1:3 muscularis/mucosa ratio. The lumen of the small intestine was empty with no signs of ileus, obstruction or foreign material.

Normal visible colon wall layers were present with apparent formed feces in lumen.

DATE

06/24/2022

Pancreas



PATIENT

Raven Goodman

The parenchyma of the left limb, body and right limb of the pancreas presented isoechoic to the adjacent omental fat. A normal curvilinear capsule contour of the pancreas was present. The visible pancreatic duct was normal. No signs of active inflammation or neoplastic disease was evident.

SPECIES

Canine

Free Abdomen

No overt lymphadenopathy or peritoneal effusion was present.

BREED

Lab

ULTRASONOGRAPHIC FINDINGS

- Sonographically unremarkable bladder and visible proximal urethra
- Overtly normal bilateral kidneys

SEX

FS

INTERPRETATION OF THE FINDINGS & FURTHER RECOMMENDATIONS

No evidence of overt upper or lower urinary tract pathology i.e. pyelonephritis, cystitis, bladder calculi or cystic neoplastic criteria was observed. A urine C/S on sterile urine sample to rule out underlying infection could be considered. Assessment of the vulva and potential vaginal vault scope if persistent hematuria could be considered to rule out contributing factors.

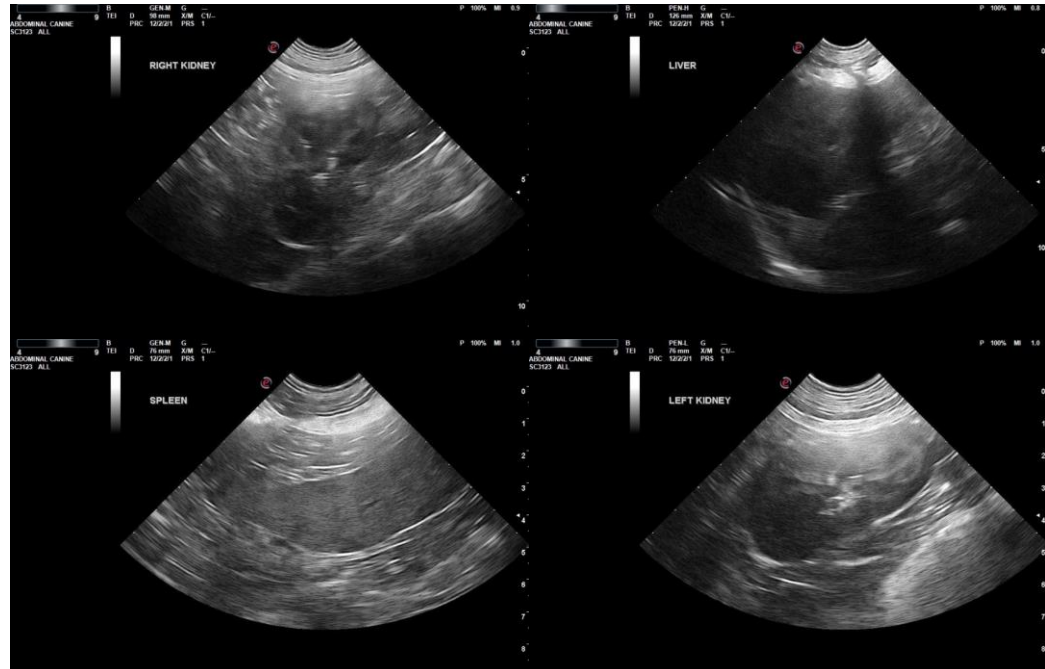
5 yr

WEIGHT

80lb

INTERPRETED BY

R. McKenzie Daniel,
DVM, DABVP
(Canine and Feline)



IMAGING PERFORMED BY

Rebekah Jakum, CVT
ARDMS/RVT

HOSPITAL NAME

Bean Acres MVC

REFERRING VET

Dr. Mirabile

INVOICE

10938ag

DATE

06/24/2022



PATIENT

Raven Goodman

SPECIES

Canine

BREED

Lab

SEX

FS

AGE

5 yr

WEIGHT

80lb

INTERPRETED BY

R. McKenzie Daniel,
DVM, DABVP
(Canine and Feline)

IMAGING PERFORMED BY

Rebekah Jakum, CVT
ARDMS/RVT

HOSPITAL NAME

Bean Acres MVC

REFERRING VET

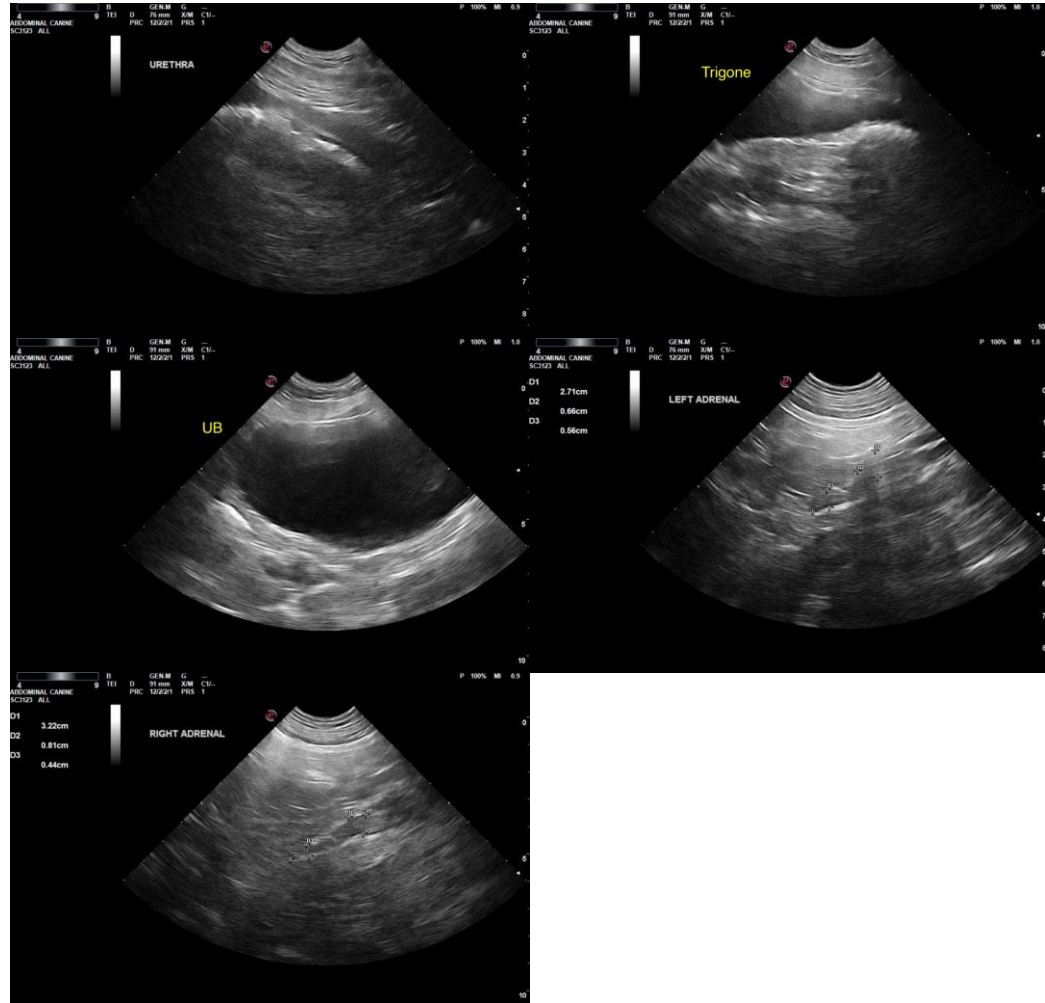
Dr. Mirabile

INVOICE

10938ag

DATE

06/24/2022



The information and recommendations provided are based on the images presented by the referring veterinarian/sonographer. No evaluation can be communicated regarding pathology that was not visible in the image/video clips provided.

Thank you for this referral. If the clinical or image interpretation does not parallel your findings or if I can be of any further assistance, please contact me.

R. McKenzie Daniel, DVM, DABVP (Canine/Feline Practice)
mac.daniel@sonopath.com