



PATIENT PRESENTING CLINICAL SIGNS

Brady Gallant History: Chronic vomiting improved on RDVD Ultamino but recently has returned. Vomits clear liquid daily. Eating and drinking normally - no weight loss noted. PE: WNL. BW normal other than cholesterol high 330. ? pancreatitis or underlying GI disease

SPECIES

Feline

ULTRASONOGRAPHIC EXAMINATION OF THE ABDOMEN

Urinary System

BREED

DSH

SEX

MN

AGE

5 yr

WEIGHT

10.3 lb

The urinary bladder was subnormal in size owing to lack of urine distention. The trigone, cystourethral junction, and visible pelvic urethra exhibited normal thickness and tone. Anechoic urine was present in the lumen with subjective moderate echogenic to pinpoint hyperechoic sediment to sand. Potential adherence of a small amount of sand to the ventral and dorsal bladder wall is possible. A minor amount of non obstructive sand was noted in the proximal urethra. The ureteral papillae were normal. The ureters were not visible which is normal. No evidence of inflammatory or neoplastic changes were noted.

Normal size and margination was present in the kidneys. A normal 1:3 cortex / medulla ratio and normal corticomedullary definition were maintained. The echogenicity of the cortex was similar to or slightly less than normal liver parenchyma while the medulla echogenicity was hypoechoic to the cortex with no evidence of pelvic dilation. The left kidney measured 4.1 cm in length. The right kidney measured 4.2 cm in length.

The area of the aortic trifurcation was free of pathology.

Adrenal Glands

The left adrenal gland was uniform in size and contour with a uniformly hypoechoic parenchyma. The left adrenal gland measured 0.30 cm. The right adrenal gland was uniform in size and contour with a uniformly hypoechoic parenchyma. The right adrenal gland measured 0.34 cm.

Spleen

The spleen exhibited a finely textured and homogenous parenchyma which was hyperechoic to the liver and renal cortical parenchyma. The capsule was smooth and regular without apparent expansion. The splenic vasculature at the hilus was normal in volume with no evidence of congestion or thrombosis. Acute to chronic inflammatory, neoplastic, or benign parenchyma changes were not noted.

Liver

The liver was subjectively normal in size, structure, and contour. The liver parenchyma was uniform and hypoechoic to the spleen with a mild coarse echotexture. The hepatic and portal vasculature were normal in appearance without signs of congestion. The gallbladder was non-distended in size with thin walls and primarily anechoic luminal content. The cystic and common bile ducts were normal.

Gastrointestinal

The stomach presented intact wall layering with a normal wall layer ratio. Nonspecific pinpoint hyperechoic mural foci were present in the ventral gastric body and fundus. The lumen of the stomach was empty with no signs of ileus, obstruction or foreign material.

The small intestine presented intact wall layering with 1:3 muscularis/mucosa ratio. The lumen of the small intestine was empty with no signs of ileus, obstruction or foreign material. The duodenum wall measured 0.24 cm in width. The jejunum wall measured 0.20 cm in width. The ileocolic wall measured 0.29 cm in width.

INTERPRETED BY

R. McKenzie Daniel, DVM,
DABVP (Canine and Feline)

IMAGING PERFORMED BY

Pamela Harrigan, RDCS

HOSPITAL NAME

Wood River Animal Hospital

REFERRING VET

Dr. Schuelke

INVOICE

10929ag

DATE

06/24/2022



PATIENT Normal visible colon wall layers were present with apparent formed feces in lumen.

Brady Gallant **Pancreas**

SPECIES The pancreas was normal in size and contour. Isoechoic to mildly nonhomogeneous parenchyma compared to the adjacent omental fat was noted. The visible pancreatic duct was normal. No signs of active inflammation or neoplastic disease was evident.

Feline **Free Abdomen**

BREED No omental masses, overt lymphadenopathy or peritoneal free fluid.

DSH ULTRASONOGRAPHIC FINDINGS

- Moderate urinary bladder sediment/sand
- Overtly normal GI tract, possible low grade chronic gastritis
- Subtle non homogeneous pancreas

MN INTERPRETATION OF THE FINDINGS & FURTHER RECOMMENDATIONS

AGE The urinary bladder sediment may suggest cellular / crystalline debris or mucus. Cystocentesis for UA +/- C/S if evidence of inflammatory cells is recommended.

5 yr Overall no overt evidence of significant abdominal visceral pancreatic or GI pathology as an overt cause of the patient's chronic vomiting was noted. The possibility of structurally insignificant inflammatory GI disease or low grade to chronic pancreatitis could be present yet appear sonographically normal.

WEIGHT 10.3 lb Further assessment may include a spec fPL or a full GI panel to rule out occult or nonobvious GI or pancreatic disease. Given the lack of reported weight loss, dietary intolerance even with current diet could be a contributing factor. Potential alternative novel protein or hydrolyzed diet with GI protectant protocol with assessment of clinical response may prove beneficial. Three view chest radiographs are suggested to rule out occult thoracic or esophageal pathology.

INTERPRETED BY R. McKenzie Daniel, DVM, DABVP (Canine and Feline)

Heartworm AG/AB test as well as empirical deworming could be considered.

IMAGING PERFORMED BY

Pamela Harrigan, RDCS

HOSPITAL NAME

Wood River Animal Hospital

REFERRING VET

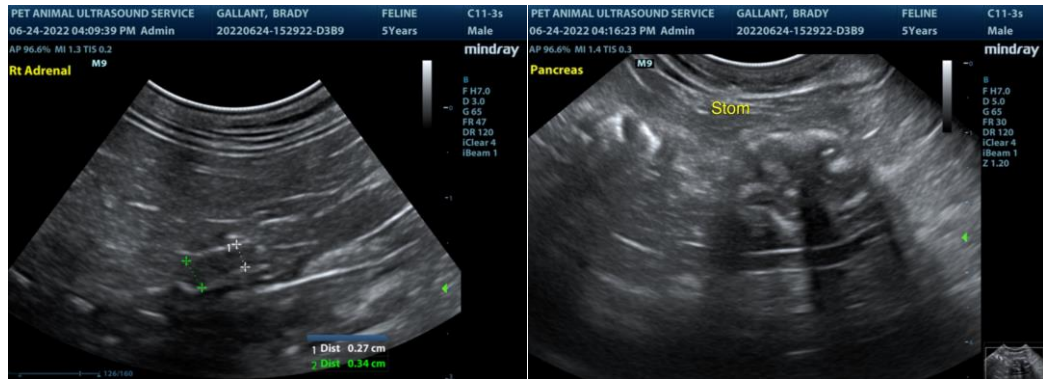
Dr. Schuelke

INVOICE

10929ag

DATE

06/24/2022





PATIENT

Brady Gallant

SPECIES

Feline

BREED

DSH

SEX

MN

AGE

5 yr

WEIGHT

10.3 lb

INTERPRETED BY

R. McKenzie Daniel, DVM,
 DABVP (Canine and Feline)

IMAGING PERFORMED BY

Pamela Harrigan, RDCS

HOSPITAL NAME

Wood River Animal
 Hospital

REFERRING VET

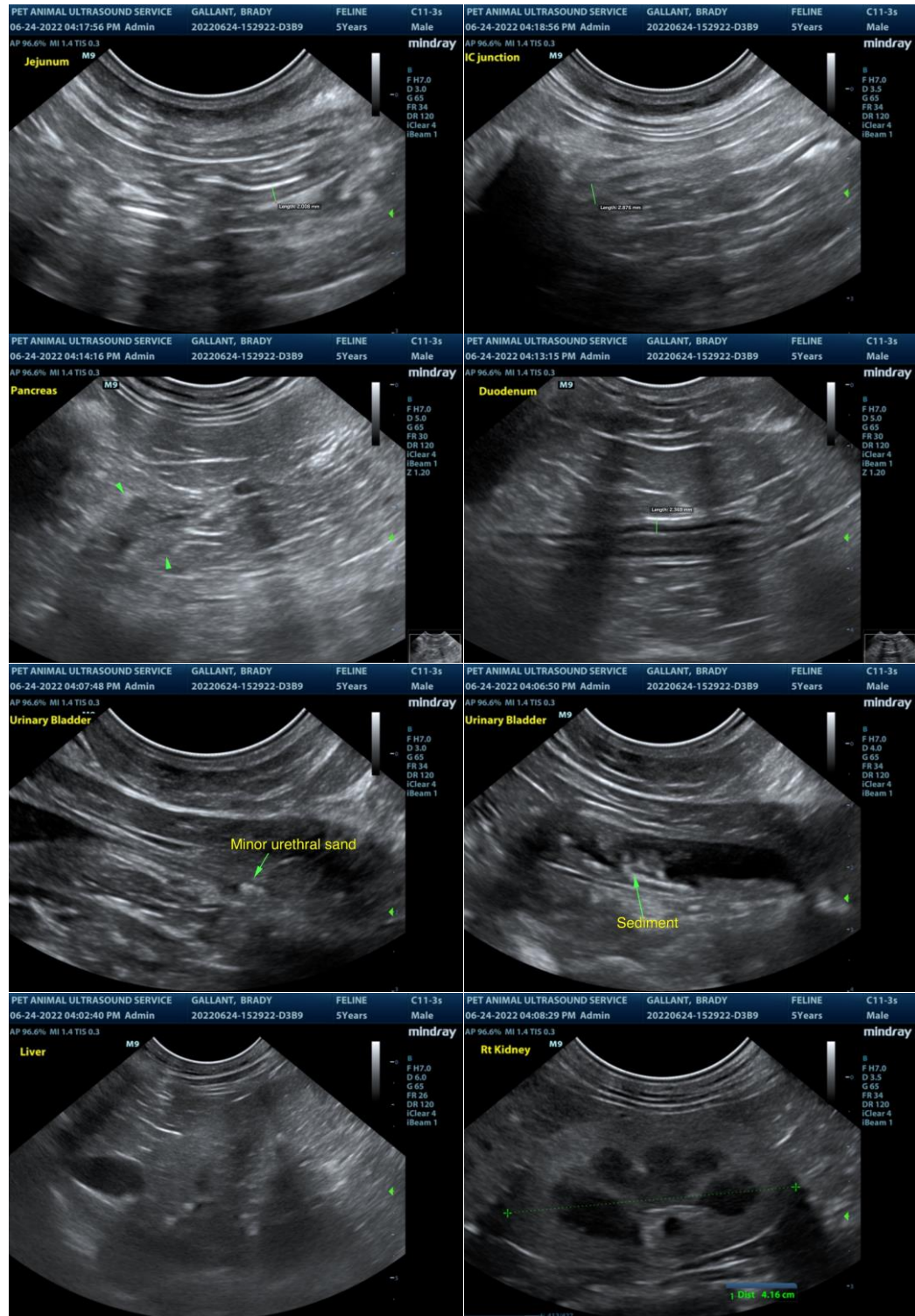
Dr. Schuelke

INVOICE

10929ag

DATE

06/24/2022





PATIENT

Brady Gallant

SPECIES

Feline

BREED

DSH

SEX

MN

AGE

5 yr

WEIGHT

10.3 lb

INTERPRETED BY

R. McKenzie Daniel, DVM,
 DABVP (Canine and Feline)

IMAGING PERFORMED BY

Pamela Harrigan, RDCS

HOSPITAL NAME

Wood River Animal
 Hospital

REFERRING VET

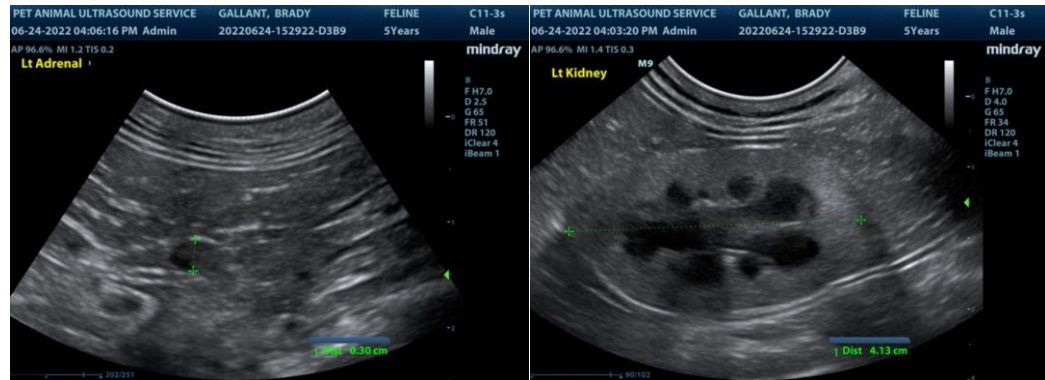
Dr. Schuelke

INVOICE

10929ag

DATE

06/24/2022



The information and recommendations provided are based on the images presented by the referring veterinarian. No evaluation can be communicated regarding pathology that was not visible in the image/video clips provided.

Thank you for this referral. If the clinical or image interpretation does not parallel your findings or if I can be of any further assistance please contact me.

R. McKenzie Daniel, DVM, DABVP (Canine / Feline Practice)
 info@SonoPath.com