



**PATIENT PRESENTING CLINICAL SIGNS**

Luca Barry Intermittent urinary issues including polyuria. No bacteria or crystalluria on UA. On Purina UR diet. Low USG (1.014); ALP 134. \*Urinary system only

**SPECIES LIMITED ULTRASONOGRAPHIC EXAMINATION OF THE ABDOMEN**

Canine **Urinary System**

**BREED** Pug  
 The urinary bladder was normal in size and tone with normal appearing walls. The trigone, cystourethral junction, and visible pelvic urethra to a depth of 4 cm exhibited normal thickness and tone. Anechoic urine was present in the lumen with mild dependent lumen sand/mineral. Mild non-obstructive proximal urethral lumen mineral was present.

**SEX** Normal size and margination were present in the kidneys. A normal 1:3 cortex / medulla ratio and normal corticomedullary definition were maintained. Non-obstructive medullary mineral was present bilaterally around the pelvis and lateral diverticuli. The echogenicity of the cortex was similar to or slightly less than normal liver parenchyma while the medulla echogenicity was hypoechoic to the cortex with no evidence of pelvic dilation or pyelonephritis. The left kidney measured 4.2 cm in length. The right kidney measured 4.1 cm in length.

**AGE ULTRASONOGRAPHIC FINDINGS**

- 6yr
- Bilateral non-obstructive renal medullary mineralization.
  - Normal urinary bladder with mild dependent lumen sand/mineral.
  - Mild non-obstructive proximal urethra lumen mineral.

**WEIGHT**  
 28.3lb

**INTERPRETATION OF THE FINDINGS & FURTHER RECOMMENDATIONS**

**INTERPRETED BY**

R. McKenzie Daniel, DVM,  
 DABVP (Canine and Feline)

This patient may be passing small amounts of mineral from the kidneys into the urinary bladder. Cystocentesis for UA +/- C/S is suggested even without evidence of bacteriuria. Continued urinary diet with monitoring of progressive renal or cystic mineral would be reasonable.

**IMAGING PERFORMED BY**

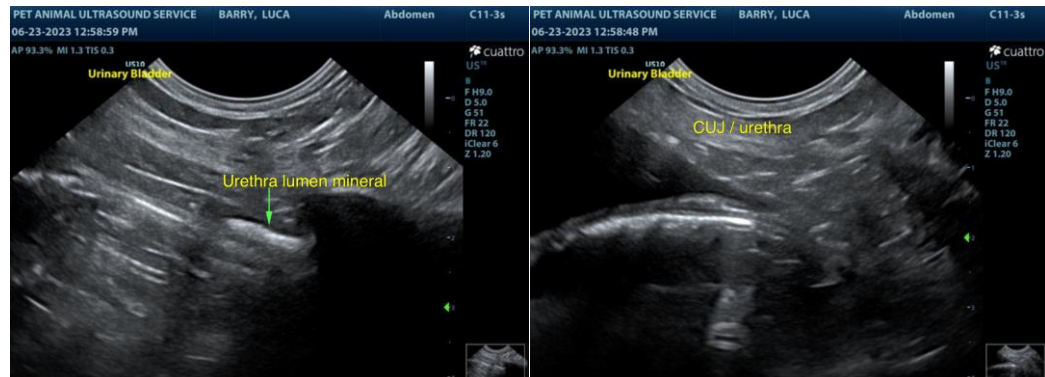Pamela Harrigan, RDCS

**HOSPITAL NAME**

Airport Animal Hospital

**REFERRING VET**

Asha Gudluru, DVM



**INVOICE**

14189

**DATE**

06/23/2023



**PATIENT**

Luca Barry

**SPECIES**

Canine

**BREED**

Pug

**SEX**

MN

**AGE**

6yr

**WEIGHT**

28.3lb

**INTERPRETED BY**

R. McKenzie Daniel, DVM,  
 DABVP (Canine and Feline)

**IMAGING PERFORMED BY**

Pamela Harrigan, RDCS

**HOSPITAL NAME**

Airport Animal  
 Hospital

**REFERRING VET**

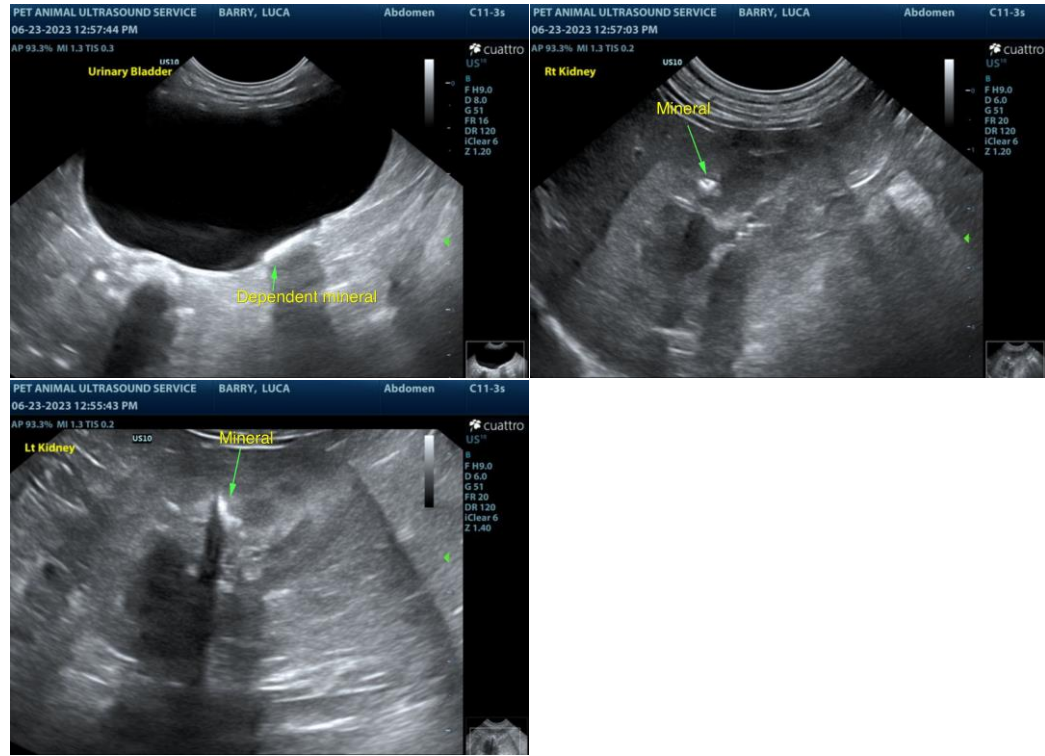
Asha Gudluru, DVM

**INVOICE**

14189

**DATE**

06/23/2023



The information and recommendations provided are based on the images presented by the referring veterinarian/sonographer. No evaluation can be communicated regarding pathology that was not visible in the image/video clips provided.

Thank you for this referral. If the clinical or image interpretation does not parallel your findings or if I can be of any further assistance please contact me.

R. McKenzie Daniel, DVM, DABVP (Canine / Feline Practice)

info@SonoPath.com