

PATIENT PRESENTING CLINICAL SIGNS

Cooper Vasquez P having lifelong vomiting/diarrhea. Seems to be on and off Unremarkable on exam. BW: very unremarkable other than high cholesterol (likely due to weight gain)

SPECIES

Canine

BREED

Doodle

SEX

Neutered Male

AGE

2y

WEIGHT

96lbs

INTERPRETED BY

R. McKenzie Daniel,
DVM, DABVP (Canine
and Feline)

IMAGING PERFORMED BY

Jenna Walsh, CVT

HOSPITAL NAME

The Ark Veterinary
Clinic

REFERRING VET

Dr. Hillberg

INVOICE

10274

DATE

6/23/2023

ULTRASONOGRAPHIC EXAMINATION OF THE ABDOMEN

Urinary System

The urinary bladder, trigone, cystourethral junction, and visible pelvic urethra to a depth of 3 cm exhibited normal thickness and tone. Anechoic urine was present in the lumen with no uroliths or sediment. The ureteral papillae were normal. The ureters were not visible which is normal. No evidence of inflammatory or neoplastic changes was noted.

The residual prostate was free of pathology.

The area of the aortic trifurcation was free of pathology.

Normal size and margination were present in the kidneys. A normal 1:3 cortex/medulla ratio and normal corticomedullary definition were maintained. The echogenicity of the cortex was similar to or slightly less than normal liver parenchyma while the medulla echogenicity was hypoechoic to the cortex with no evidence of pelvic dilation. The left kidney measured 7.2 cm in length. The right kidney measured 7.1 cm in length.

Adrenal Glands

The left adrenal gland was uniform in size and contour with a uniformly hypoechoic parenchyma. The left adrenal gland measured 2.2 cm length x 0.66 cm caudal pole width. The right adrenal gland was uniform in size and contour with a uniformly hypoechoic parenchyma. The right adrenal gland measured 2.4 cm length x 0.66 cm caudal pole width.

Spleen

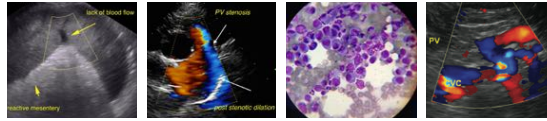
The spleen exhibited a finely textured and homogenous parenchyma which was hyperechoic to the liver and renal cortical parenchyma. The capsule was smooth and regular without apparent expansion. The splenic vasculature at the hilus was normal in volume with no evidence of congestion or thrombosis. Acute to chronic inflammatory, neoplastic, or benign parenchyma changes were not noted.

Liver/ Gallbladder

The liver was subjectively normal in size, structure, and contour. The liver parenchyma was uniform and hypoechoic to the spleen with a mild coarse echotexture. The hepatic and portal vasculature were normal in appearance without signs of congestion. The gallbladder was non-distended in size with thin walls and primarily anechoic luminal content. The cystic and common bile ducts were normal.

Gastrointestinal

The stomach presented intact wall layering with a normal wall layer ratio. The lumen of the stomach contained minor retained anechoic fluid with no signs of ileus, obstruction, or foreign material. The gastric body wall measured 0.50 cm.



PATIENT

Cooper Vasquez

The small intestine presented intact wall layering with 1:3 muscularis/mucosa ratio. The lumen of the small intestine was empty with no signs of ileus, obstruction, or foreign material. The duodenum wall measured 0.45 cm width. The jejunum wall measured 0.41 cm width.

SPECIES

Canine

Normal visible colon wall layers were present with apparent formed feces in lumen.

Pancreas

BREED

Doodle

The parenchyma of the left limb, body, and right limb of the pancreas presented isoechoic to the adjacent omental fat. A normal curvilinear capsule contour of the pancreas was present. The visible pancreatic duct was normal. No signs of active inflammation or neoplastic disease were evident.

Free Abdomen

SEX

Neutered Male

No overt lymphadenopathy or peritoneal effusion was present.

ULTRASONOGRAPHIC FINDINGS

AGE

2y

Primary Findings

- Sonographically unremarkable gastrointestinal tract with minor retained gastric fluid.
- Formed fecal matter in colon.

WEIGHT

96lbs

INTERPRETATION OF THE FINDINGS & FURTHER RECOMMENDATIONS

INTERPRETED BY

R. McKenzie Daniel, DVM, DABVP (Canine and Feline)

No sonographic evidence of visceral specifically gastroenterocolic pathology as an obvious cause or contributing factor to the patient's intermittent gastrointestinal signs. At times the gastroenterocolic sonographic appearance may not correlate with a history of intermittent or chronic gastrointestinal signs. Considerations may include dietary intolerance/food hypersensitivity, dysbiosis, structurally insignificant inflammatory gastrointestinal disease, occult parasitism, and chronic pancreatitis both of which may present sonographically normal. Less likely occult Addison's disease given normal adrenal appearance or other gastroenterocolopathy. A GI panel to include PLI/TLI/Cobalamin/Folate may be considered.

IMAGING PERFORMED BY

Jenna Walsh, CVT

Empirically, novel protein or hydrolyzed diet trial with potential long-term dietary therapy. High colony count probiotics such as Provable or Visbiome and prophylactic deworming i.e., Panacur 50 milligram per kilogram POSID for 5 consecutive days, even if fecal testing is negative may prove beneficial.

HOSPITAL NAME

The Ark Veterinary Clinic

REFERRING VET

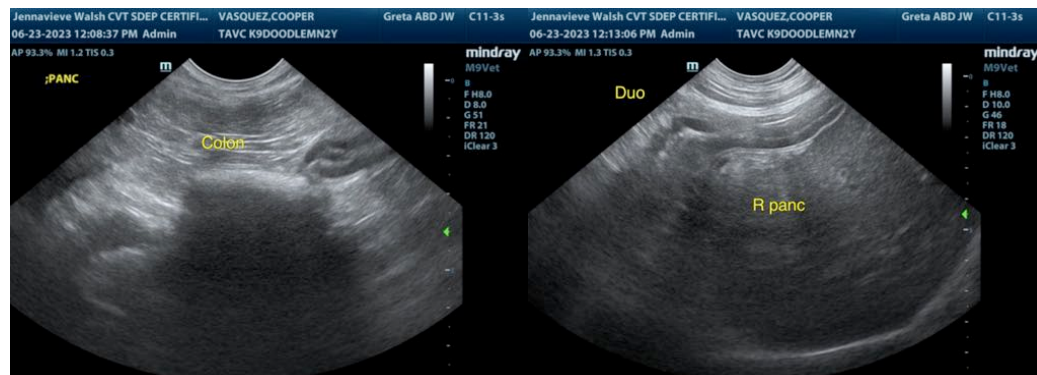
Dr. Hillberg

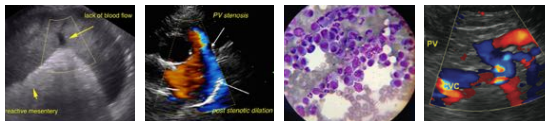
INVOICE

10274

DATE

6/23/2023





PATIENT

Cooper Vasquez

SPECIES

Canine

BREED

Doodle

SEX

Neutered Male

AGE

2y

WEIGHT

96lbs

INTERPRETED BY

R. McKenzie Daniel,
DVM, DABVP (Canine
and Feline)

**IMAGING
PERFORMED BY**

Jenna Walsh, CVT

HOSPITAL NAME

The Ark Veterinary
Clinic

REFERRING VET

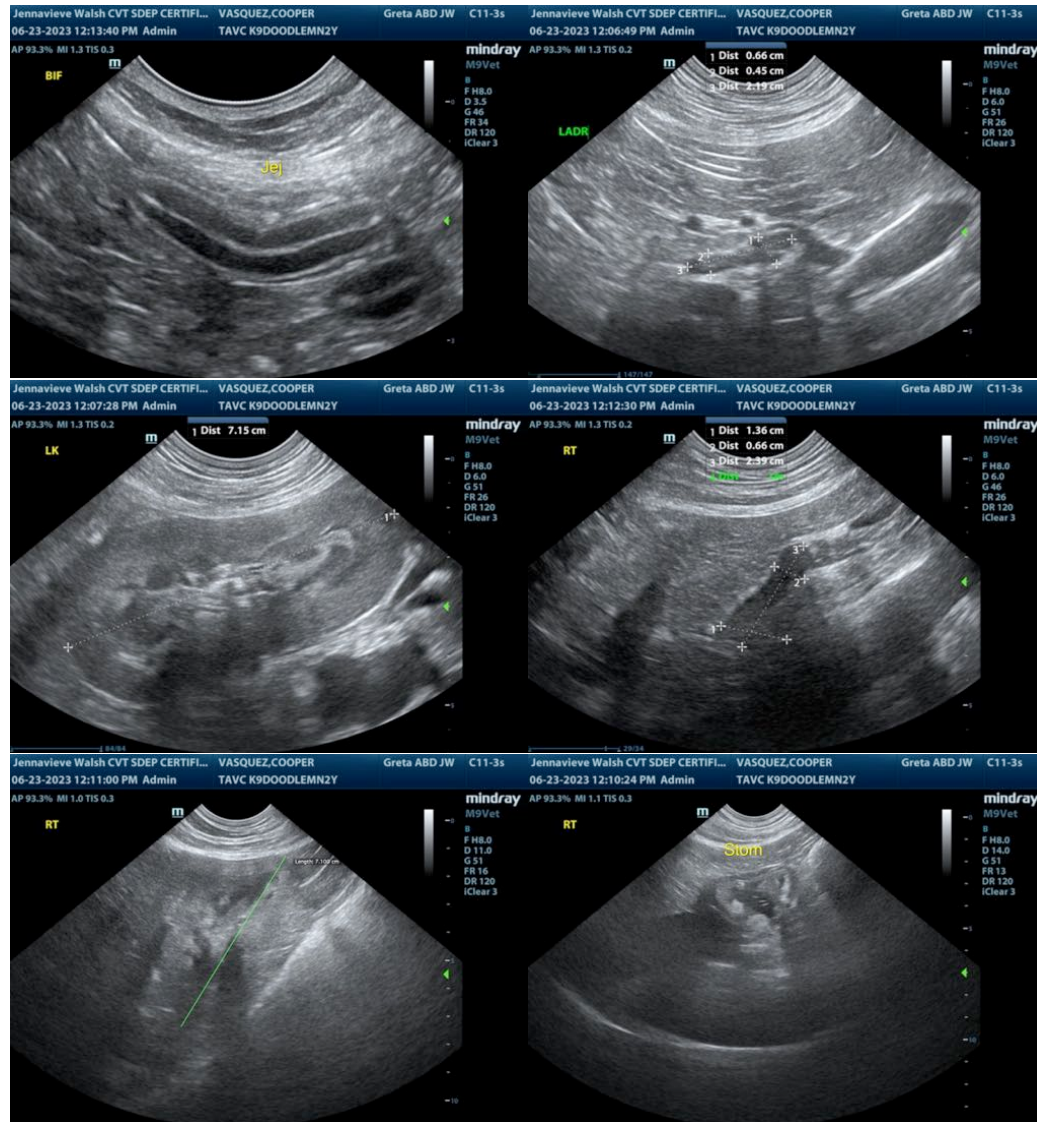
Dr. Hillberg

INVOICE

10274

DATE

6/23/2023



The information and recommendations provided are based on the images presented by the referring veterinarian/sonographer. No evaluation can be communicated regarding pathology that was not visible in the image/video clips provided.

Thank you for this referral. If the clinical or image interpretation does not parallel your findings or if I can be of any further assistance, please contact me.

R. McKenzie Daniel, DVM, DABVP (Canine / Feline Practice)
info@SonoPath.com