



**PATIENT**

Tessa Hernandez

**PRESENTING CLINICAL SIGNS**

History: History UTI and hematuria. On Clavamox drops

**SPECIES**

Canine

**ULTRASONOGRAPHIC EXAMINATION OF THE ABDOMEN**

**Urinary System**

The urinary bladder presented mild uniformly thickened urinary bladder wall isoechoic to the adjacent normal urinary bladder wall. The luminal margin of the thickened urinary bladder wall was mildly asymmetrical in contour. The apical urinary bladder wall thickness measured 0.24 cm. Pinpoint areas of minor dependent luminal mineral were present. The urinary bladder, trigone, cystourethral junction, and visible pelvic urethra exhibited normal tone to a depth of 3.0 cm. Anechoic urine was present in the lumen. The ureteral papillae were normal. The ureters were not visible which is normal.

**BREED**

Shih Tzu

**SEX**

Spayed Female

The right kidney was mildly subnormal in size compared to the left. A normal 1:3 cortex / medulla ratio was maintained. The kidneys exhibited mild nonuniform cortex echogenicity, increased medullary echogenicity and moderate loss of corticomedullary border demarcation. A small medial left kidney cortical cyst was present. No evidence of pelvic dilation was present. The left kidney measured 4.0 cm in length. The right kidney measured 3.0 cm in length.

**AGE**

10 Years

**Adrenal Glands**

**WEIGHT**

11 Pounds

The left adrenal gland was uniform in size and contour with a uniformly hypoechoic parenchyma. The overall left adrenal gland measured 1.9 cm in length x 0.69 cm width at the cranial pole and 0.44 cm width at the caudal pole. A well-defined, hyperechoic non-expansive nonhomogeneous nodule was present in the cranial pole of the left adrenal gland. The nodule exhibited potential for pinpoint parenchymal mineralization. The left adrenal nodule measured 0.8 cm x 0.62 cm.

**INTERPRETED BY**

R. McKenzie Daniel, DVM,  
DABVP (Canine and  
Feline)

The right adrenal gland was uniform in size and contour with a uniformly hypoechoic parenchyma. The overall right adrenal gland measured 1.8 cm in length x 1.3 cm width. A well-defined, hyperechoic nodule was present involving the majority of the right adrenal parenchyma. The nodule was mildly expansive, resulting in mild distortion of the adrenal capsule yet without evidence of parenchymal escape or overt vascular invasion. The nodule revealed nonhomogeneous parenchyma with no overt pinpoint mineralization. The right adrenal nodule measured 1.5 cm x 1.0 cm.

**IMAGING PERFORMED BY**

Pamela Harrigan, RDCS

**Spleen**

**HOSPITAL NAME**

Norfolk County VS

The spleen exhibited a finely textured and homogenous parenchyma which was hyperechoic to the liver and renal cortical parenchyma. The capsule was smooth and regular without apparent expansion. The splenic vasculature at the hilus was normal in volume with no evidence of congestion or thrombosis. Acute to chronic inflammatory, neoplastic, or benign parenchyma changes were not noted.

**REFERRING VET**

Amelia Ragon, DVM

**Liver**

**INVOICE**

16264

The liver was subjectively normal in size, structure, and contour. The liver parenchyma was mildly nonuniform and hypoechoic to the spleen with a moderate coarse echotexture and subjective mild to benign parenchymal remodeling. The hepatic and portal vasculature were normal in appearance without signs of congestion.

**DATE**

6/23/22



**PATIENT**

Tessa Hernandez

The gallbladder was non distended in size with mild nondependent yet nonorganized mildly hyperechoic gallbladder debris. The cystic duct and common bile ducts were normal without evidence of dilation.

**SPECIES**

Canine

***Gastrointestinal***

The lumen of the stomach exhibited moderate retained anechoic to echogenic fluid and chyme. Mild areas of thickened pyloric mucosa, exhibiting uniform mucosal echogenicity were present. The pylorus wall thickness, including the mucosa measured 1.0 cm in diameter.

**BREED**

Shih Tzu

The small intestine presented intact wall layering with 1:3 muscularis/mucosa ratio. The lumen of the small intestine was empty with no signs of ileus, obstruction or foreign material.

**SEX**

Spayed Female

Normal visible colon wall layers were present with apparent formed feces in lumen.

***Pancreas***

The parenchyma of the left limb, body and right limb of the pancreas presented isoechoic to the adjacent omental fat. A normal curvilinear capsule contour of the pancreas was present. The visible pancreatic duct was normal. No signs of active inflammation or neoplastic disease was evident.

**AGE**

10 Years

***Free Abdomen***

No overt lymphadenopathy or peritoneal effusion was present.

**WEIGHT**

11 Pounds

**ULTRASONOGRAPHIC FINDINGS**

- Mild cystitis pattern
- Moderate chronic renal changes with left kidney cortical cyst
- Bilateral nodular adrenal glands- functional versus nonfunctional adenoma, benign hyperplasia, potential for emerging neoplastic criteria, i.e., pheochromocytoma, adenocarcinoma or other possible
- Mild gallbladder debris (non-mucocele)
- Mild gastric fluid/chyme retention, mild pyloric mucosal hyperplasia

**INTERPRETED BY**

R. McKenzie Daniel, DVM,  
 DABVP (Canine and  
 Feline)

**INTERPRETATION OF THE FINDINGS & FURTHER RECOMMENDATIONS**

Urine culture and sensitivity on sterile urine sample, if not recently done, is suggested to assess for recurring UTI. Antibiotic therapy, if documented UTI and based on urine culture and sensitivity results +/- supportive care for mild cystitis would be reasonable. Screening blood pressure to assess for evidence of hypertension, which may allude to a left or right pheochromocytoma, is suggested. Functional adrenal nodules are considered less likely, if no clinical signs consistent with adrenal hyperfunctionality. Sonographic monitoring of the bilateral adrenal glands for evidence of progression, with initial recheck in 4-6 weeks, is suggested.

**IMAGING PERFORMED BY**

Pamela Harrigan, RDMS

**HOSPITAL NAME**

Norfolk County VS

**REFERRING VET**

Amelia Ragon, DVM

**INVOICE**

16264

**DATE**

6/23/22

The retained gastric fluid is of unclear clinical significance. The mild pyloric mucosal hyperplasia does not appear to be obstructive yet potentially, if evidence of inappetence, vomiting or similar, some degree of delayed gastric emptying could be a possibility. Gastric protectant protocol, and likewise sonographic monitoring of the pylorus walls, for evidence of progressive mucosal hyperplasia, may be considered.



**PATIENT**

Tessa Hernandez

**SPECIES**

Canine

**BREED**

Shih Tzu

**SEX**

Spayed Female

**AGE**

10 Years

**WEIGHT**

11 Pounds

**INTERPRETED BY**

R. McKenzie Daniel, DVM,  
 DABVP (Canine and Feline)

**IMAGING PERFORMED BY**

Pamela Harrigan, RDCS

**HOSPITAL NAME**

Norfolk County VS

**REFERRING VET**

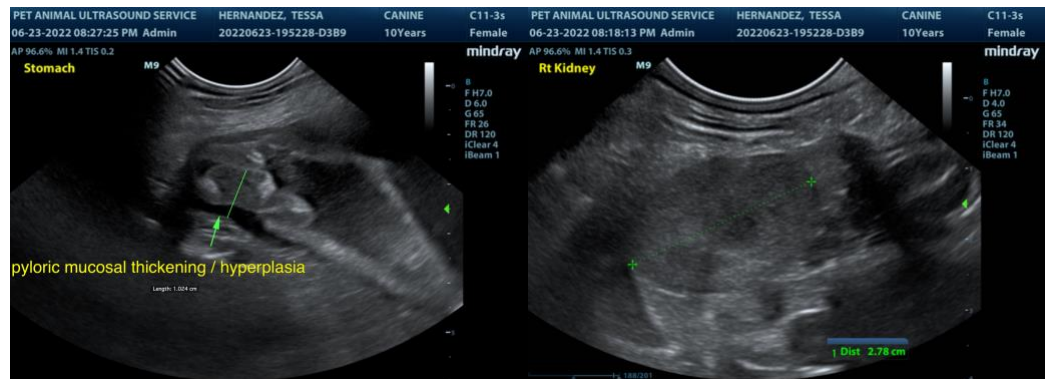
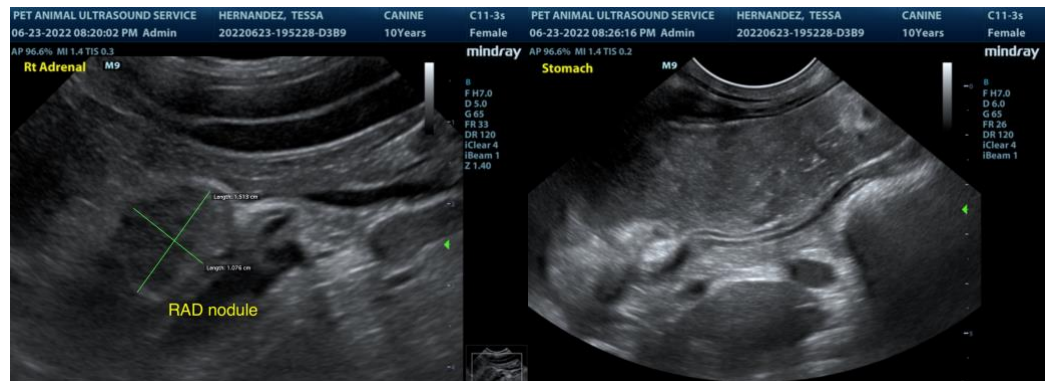
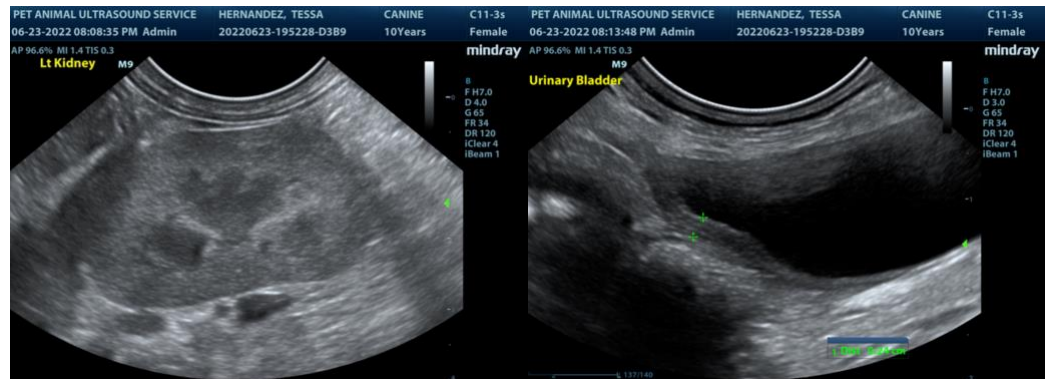
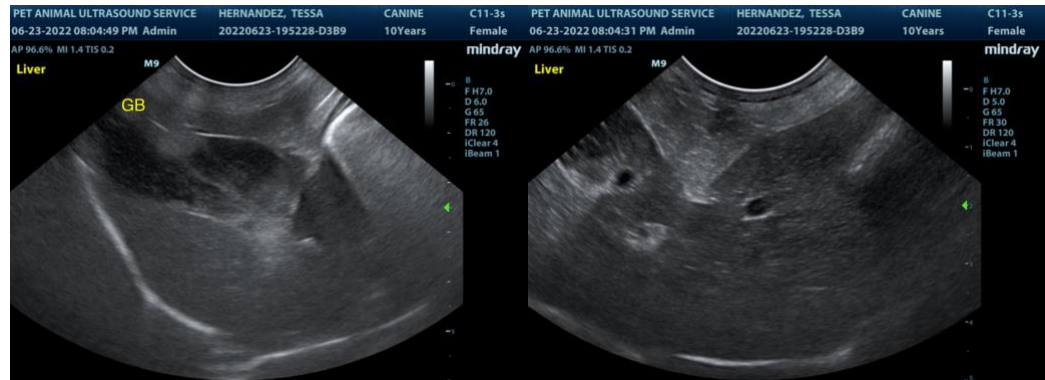
Amelia Ragon, DVM

**INVOICE**

16264

**DATE**

6/23/22





**PATIENT**

Tessa Hernandez

**SPECIES**

Canine

**BREED**

Shih Tzu

**SEX**

Spayed Female

**AGE**

10 Years

**WEIGHT**

11 Pounds

**INTERPRETED BY**

R. McKenzie Daniel, DVM,  
 DABVP (Canine and  
 Feline)

**IMAGING PERFORMED BY**

Pamela Harrigan, RDCS

**HOSPITAL NAME**

Norfolk County VS

**REFERRING VET**

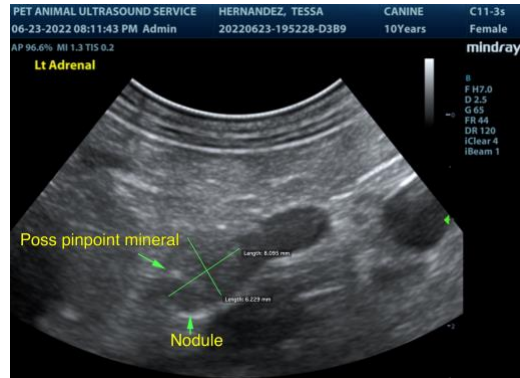
Amelia Ragon, DVM

**INVOICE**

16264

**DATE**

6/23/22



The information and recommendations provided are based on the images presented by the referring veterinarian. No evaluation can be communicated regarding pathology that was not visible in the image/video clips provided.

Thank you for this referral. If the clinical or image interpretation does not parallel your findings or if I can be of any further assistance please contact me.

**R. McKenzie Daniel, DVM, DABVP (Canine / Feline Practice)**  
 info@SonoPath.com