


PATIENT

Hamish Hamidbasha

PRESENTING CLINICAL SIGNS

Difficulty emptying bladder, ongoing. Has been on Prazosin. Would like to assess kidneys.

SPECIES

Canine

Abnormal PE/Chem/CBC/UA Results: USG 1.019, Urine pH 9.0, UPCR normal. SDMA slightly elevated at 16(0-14).

BREED

Border Collie

ULTRASONOGRAPHIC EXAMINATION OF THE ABDOMEN
Urinary System
SEX

MN

The urinary bladder, trigone, and cystourethral junction exhibited normal thickness and tone. The visible urethra exhibited normal structure and tone to a depth of 4.0 cm. Anechoic urine was present in the lumen with no uroliths or sediment. The ureteral papillae were normal. The ureters were not visible which is normal. No evidence of inflammatory or neoplastic changes was noted.

AGE

2 years

The residual prostate was symmetrically normal in size with uniform parenchyma and slight coarse echotexture measuring 1.0 cm in diameter.

The area of the aortic trifurcation was free of pathology.

WEIGHT

54.8 lbs.

Normal size and margination were present in the kidneys. A normal 1:3 cortex / medulla ratio and normal corticomedullary definition were maintained. The echogenicity of the cortex was similar to or slightly less than normal liver parenchyma while the medulla echogenicity was hypoechoic to the cortex with no evidence of pelvic dilation. The left kidney measured 5.7 cm in length. The right kidney measured 6.0 cm in length.

INTERPRETED BY

 R. McKenzie Daniel,
 DVM, DABVP

Adrenal Glands

The left adrenal gland was uniform in size and contour with a uniformly hypoechoic parenchyma. The left adrenal gland measured 0.49 cm width at the caudal pole and 0.58 cm width at the cranial pole. The right adrenal gland was uniform in size and contour with a uniformly hypoechoic parenchyma. The right adrenal gland measured 0.56 cm width at the caudal pole.

IMAGING PERFORMED BY

Crystal Hill

Spleen

The spleen exhibited a finely textured and homogenous parenchyma which was hyperechoic to the liver and renal cortical parenchyma. The capsule was smooth and regular without apparent expansion. The splenic vasculature at the hilus was normal in volume with no evidence of congestion or thrombosis. Acute to chronic inflammatory, neoplastic, or benign parenchyma changes were not noted.

HOSPITAL NAME

Southside Pet Hospital

REFERRING VET

Dr. Honda

Liver/ Gallbladder

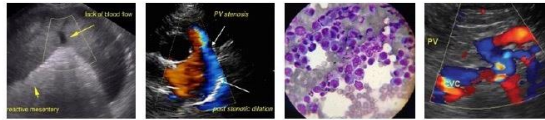
The liver was subjectively normal in size, structure, and contour. The liver parenchyma was uniform and hypoechoic to the spleen with a mild coarse echotexture. The hepatic and portal vasculature were normal in appearance without signs of congestion. The gallbladder was non-distended in size with thin walls and primarily anechoic luminal content. The cystic and common bile ducts were normal.

INVOICE

17124

DATE

6/21/23



PATIENT

Hamish Hamidbasha

SPECIES

Canine

BREED

Border Collie

SEX

MN

AGE

2 years

WEIGHT

54.8 lbs.

INTERPRETED BY

R. McKenzie Daniel,
DVM, DABVP

IMAGING PERFORMED BY

Crystal Hill

HOSPITAL NAME

Southside Pet Hospital

REFERRING VET

Dr. Honda

INVOICE

17124

DATE

6/21/23

Gastrointestinal

The stomach presented intact wall layering with a normal wall layer ratio. The lumen of the stomach was empty with no signs of ileus, obstruction, or foreign material.

The small intestine presented intact wall layering with 1:3 muscularis/mucosa ratio. The lumen of the small intestine was empty with no signs of ileus, obstruction, or foreign material.

Normal visible colon wall layers were present with apparent formed feces in lumen.

Pancreas

The parenchyma of the left limb, body, and right limb of the pancreas presented isoechoic to the adjacent omental fat. A normal curvilinear capsule contour of the pancreas was present. The visible pancreatic duct was normal. No signs of active inflammation or neoplastic disease were evident.

Free Abdomen

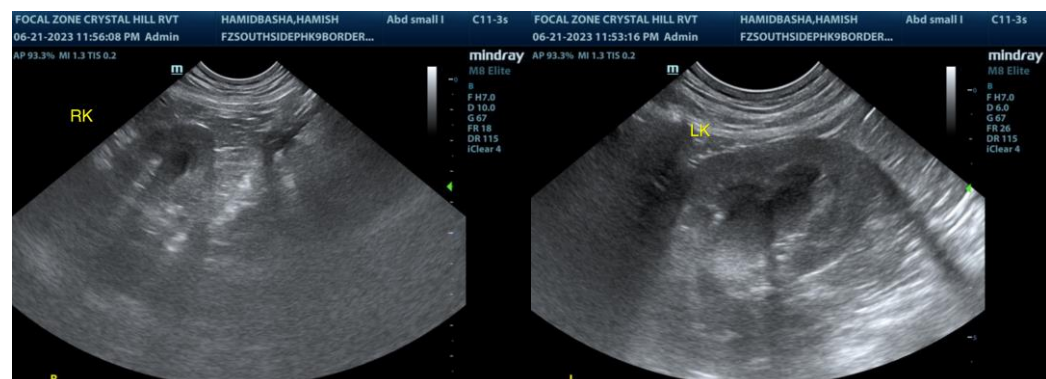
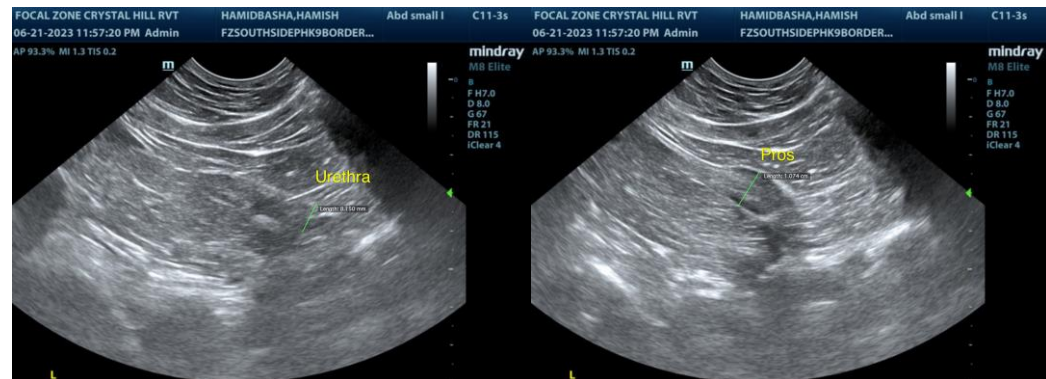
No overt lymphadenopathy or peritoneal effusion was present.

ULTRASONOGRAPHIC FINDINGS

- Sonographically unremarkable abdomen

INTERPRETATION OF THE FINDINGS & FURTHER RECOMMENDATIONS

There is no evidence of visceral pathology, specifically no evidence of upper or lower urinary tract, residual prostate, or proximal urethral pathology.





PATIENT

Hamish Hamidbasha

SPECIES

Canine

BREED

Border Collie

SEX

MN

AGE

2 years

WEIGHT

54.8 lbs.

INTERPRETED BY

R. McKenzie Daniel,
DVM, DABVP

**IMAGING
PERFORMED BY**

Crystal Hill

HOSPITAL NAME

Southside Pet Hospital

REFERRING VET

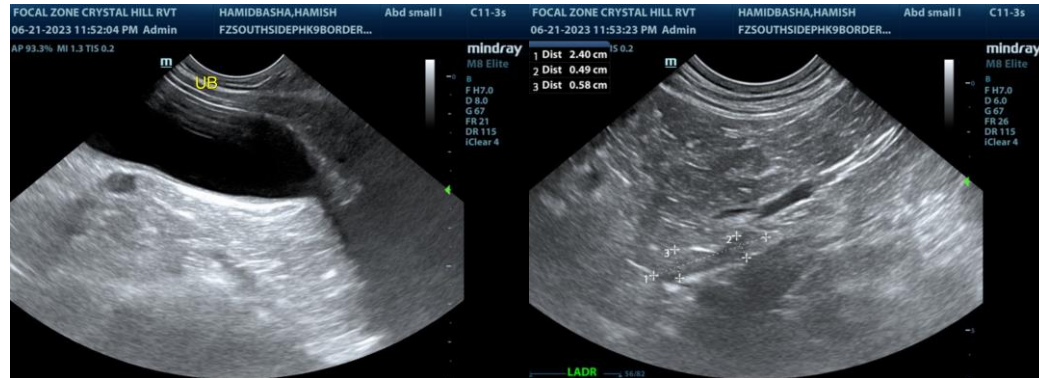
Dr. Honda

INVOICE

17124

DATE

6/21/23



The information and recommendations provided are based on the images presented by the referring veterinarian/sonographer. No evaluation can be communicated regarding pathology that was not visible in the image/video clips provided.

Thank you for this referral. If the clinical or image interpretation does not parallel your findings or if I can be of any further assistance please contact me.

R. McKenzie Daniel, DVM, DABVP (Canine / Feline Practice)
info@SonoPath.com