


**PATIENT PRESENTING CLINICAL SIGNS**

Ellie Hartzell History: O notes occasional panting when playing, no murmur ausculted, concern for potential underlying HCM. No current meds

**SPECIES ULTRASONOGRAPHIC EXAMINATION OF THE HEART**

Feline

BREED

DSH

SEX

FS

AGE

9 months

WEIGHT

11 lb

FELINE CARDIAC PARAMETERS	BODY WEIGHT (kg)	HR (BPM)	IVSd (cm)	LVIDd (cm)	LVWd (cm)	FS (%)	EF (%)
NORMAL PARAMETER	-----	150-240	0.3-0.6	1.0-2.1	0.25-0.6	35-67	80-100
PATIENT		134	0.33	1.56	0.36	37.7	71.5
FELINE CARDIAC PARAMETERS	LA/AO (Boon)	LA/AO HEART BASE (Sisson)	LA 2D 4-chamber long axis AS to FW (Sisson) (cm)	LVOT VEL. (m/s)	RVOT VEL. (m/s)	IVRT (m/)	
NORMAL PARAMETER	<1.5	0.88-1.79	0.7-1.7	<1.6	<1.3	40-60	
PATIENT	1.1	1.1	1.2	0.8	0.1	NM	
Adapted from June Boon, Veterinary Echocardiography, 1998							
Sisson D et al. JVIM 1991; 5: 232, Jacobs et al. Am J Vet Res 1985; 46:1705							

**Cardiac Presentation**

The echocardiogram in this patient demonstrated normal left atrial size based on 3 separate LA measurements. The cranial and caudal mitral valve leaflets presented normal linear structure and kinetics. The left ventricle presented normal thicknesses with linear contour and was not dilated nor restricted. The myocardium presented normal echogenicity without subjective evidence of significant fibrotic or ischemic disease. Contractility of the ventricular walls was adequate and in normal range for this patient evidenced by the fractional shortening measurement and subjective evaluation of the different regions and angles of the myocardium. The left ventricular outflow tract demonstrated normal laminar flow and subjective structural integrity. The right atrium and auricle revealed normal size, structure and content. No evidence of masses was noted or chamber overload. Tricuspid valvular assessment demonstrated adequate linear morphology and kinetics. The right ventricle was of normal size (1/3 diameter of LV), chordae structure, myocardial echogenicity and thickness. Pulmonic tract assessment revealed normal valve structure, laminar flow, and diameter (approx. 1:1 pa/ao ratio). No visible pericardial or free pleura fluid was noted or extra cardiac pathology in the visible planes. The cranial mediastinum and pericardial regions were free of masses in the visible window.

**INTERPRETED BY**

R. McKenzie Daniel,  
DVM, DABVP  
(Canine and Feline)

**IMAGING PERFORMED BY**

Jessica Miller

**HOSPITAL NAME**

Warren Animal Hospital

**REFERRING VET**

Dr. Nicole

**ULTRASONOGRAPHIC FINDINGS**

- Normal echocardiogram

**INVOICE**

10882ag

**INTERPRETATION OF THE FINDINGS & FURTHER RECOMMENDATIONS**

Overtly normal structure and function without clinical issues such as left or right heart chamber enlargement, overt congenital abnormality or evidence of clinical pulmonary hypertension. No

**DATE**

06/21/2022



**PATIENT**

Ellie Hartzell

evidence of HCM criteria was observed. Three view chest radiographs recommended to assess for pulmonary abnormalities which may be contributing to the patient's panting during activity. No indication for cardiac medications.

**SPECIES**

Feline

**BREED**

DSH

**SEX**

FS

**AGE**

9 months

**WEIGHT**

11 lb

**INTERPRETED BY**

R. McKenzie Daniel,  
DVM, DABVP  
(Canine and Feline)

**IMAGING PERFORMED BY**  
Jessica Miller

**HOSPITAL NAME**

Warren Animal Hospital

**REFERRING VET**

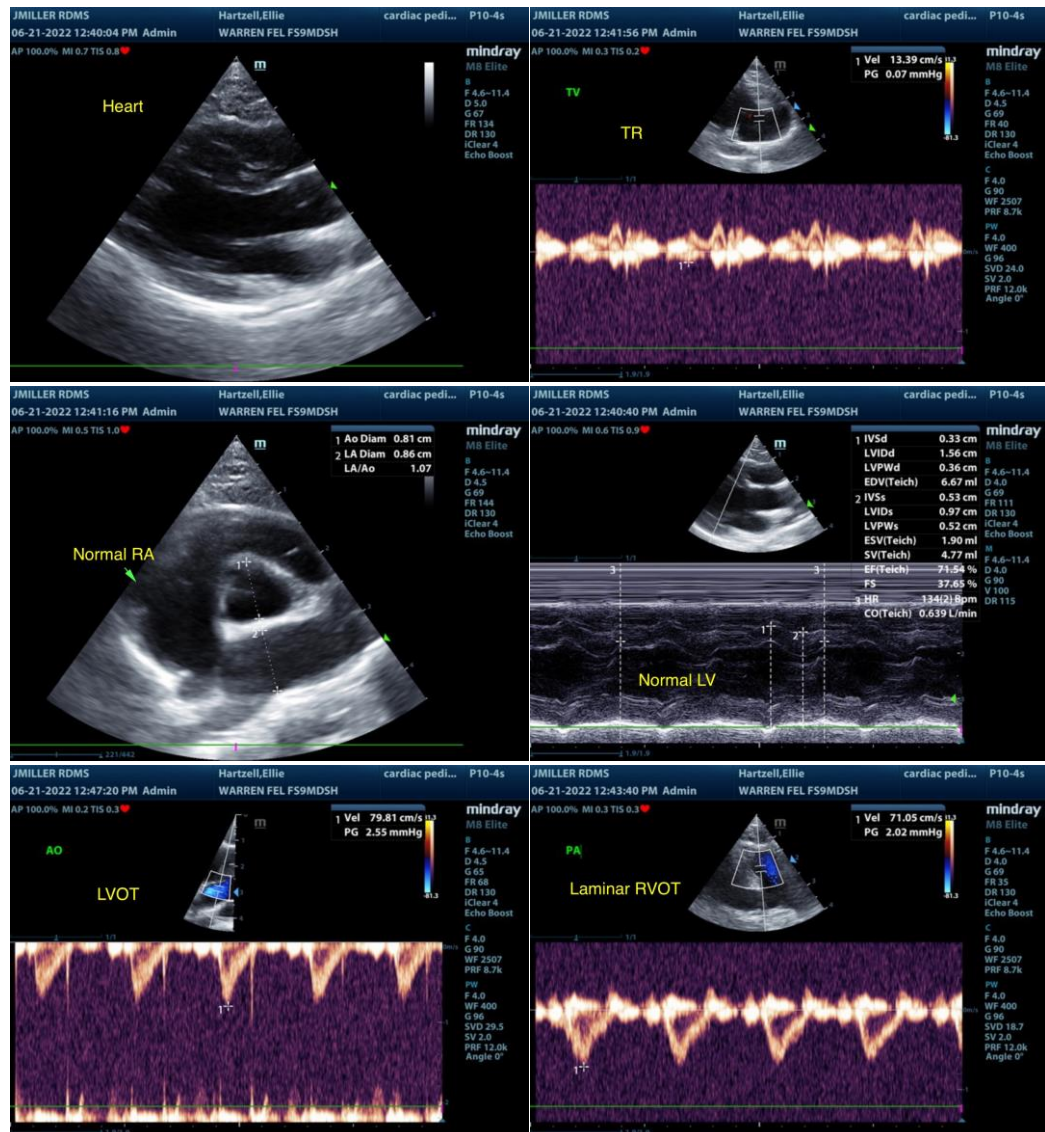
Dr. Nicole

**INVOICE**

10882ag

**DATE**

06/21/2022



The information and recommendations provided are based on the images presented by the referring veterinarian/sonographer. No evaluation can be communicated regarding pathology that was not visible in the image/video clips provided.

Thank you for this referral. If the clinical or image interpretation does not parallel your findings or if I can be of any further assistance please contact me.



**PATIENT**

R. McKenzie Daniel, DVM, DABVP (Canine / Feline Practice)

Ellie Hartzell

info@SonoPath.com

**SPECIES**

Feline

**BREED**

DSH

**SEX**

FS

**AGE**

9 months

**WEIGHT**

11 lb

**INTERPRETED BY**

R. McKenzie Daniel,  
DVM, DABVP  
(Canine and Feline)

**IMAGING  
PERFORMED BY**

Jessica Miller

**HOSPITAL NAME**

Warren Animal Hospital

**REFERRING VET**

Dr. Nicole

**INVOICE**

10882ag

**DATE**

06/21/2022