
PATIENT PRESENTING CLINICAL SIGNS

Dolly Doran History: Previously heart worm positive, treated prior to adoption last year. Lately "out of breath" quickly when playing. Heart mildly enlarged on recent chest rads. No current meds.

SPECIES Abnormal PE/Chem/CBC/UA Results: WNL

Canine ULTRASONOGRAPHIC EXAMINATION OF THE HEART
BREED

Terrier Mix

SEX

FS

AGE

3 yr

WEIGHT

45 lb

CANINE CARDIAC PARAMETERS	MR VMAX (m/s)	TR VMAX (m/s)	LA/AO (Boon method)	LA/AO (Heart Base; Swe)	FS (%)	EF (%)	EPSS (cm)
NORMAL PARAMETER	4.5-5.5	<2.7	1.3	<1.3	28-40	40-100	<0.6
PATIENT			1.1	1.1	37.3	68.3	0.3
CANINE CARDIAC PARAMETERS	HR (BPM)	AV VMAX (m/s)	PV MAX (m/s)	BODY WEIGHT (kg)	LA 2D short axis Base view (cm)	LVIDd Avg; 2D and m-mode short axis (cm)	LVIDs Avg; 2D and m-mode short axis (cm)
NORMAL PARAMETER	50-100	0.7-1.7	0.7-1.6				
PATIENT	97	1.5	1.1		3.4	3.5	

INTERPRETED BY

R. McKenzie Daniel,
DVM, DABVP
(Canine and Feline)

IMAGING PERFORMED BY

Jessica Miller

HOSPITAL NAME

Warren Animal Hospital

REFERRING VET

Dr. Nicole

INVOICE

10881ag

DATE

06/21/2022

Cardiac Presentation

The echocardiogram in this patient demonstrated normal left atrial size based on 3 separate methods of LA evaluation. The cranial and caudal mitral valve leaflets presented normal linear structure, extension in systole, and union in diastole with normal kinesis. The left ventricle presented thicknesses with linear contour and was not dilated nor restricted. The myocardium presented normal echogenicity without subjective evidence of significant fibrotic or ischemic disease. Contractility of the ventricular walls was adequate and in normal range for this patient evidenced by the fractional shortening measurement and subjective evaluation of the different regions of the myocardium. The left ventricular outflow tract demonstrated normal laminar flow and subjective structural integrity. The right atrium and auricle revealed normal size, structure and content. No evidence of masses was noted. Tricuspid valvular assessment demonstrated adequate linear morphology and kinesis. The right ventricle was of normal size (1/3 diameter of LV), chordae structure, myocardial echogenicity and thickness. Pulmonary outflow tract assessment revealed normal valve structure, laminar flow, and diameter (approx.1:1 pa/ao ratio). No visible pericardial or free pleura fluid was noted. The cranial mediastinum and pericardial and extra-cardiac regions were free of masses in the visible window. No visible heartworms in the main pulmonary artery or right heart chambers.

ULTRASONOGRAPHIC FINDINGS

- Normal echocardiogram



PATIENT

Dolly Doran

INTERPRETATION OF THE FINDINGS & FURTHER RECOMMENDATIONS

SPECIES

Canine

Overtly normal structure and function without evidence of clinical issues such as left or right heart chamber enlargement, LV systolic dysfunction or clinical pulmonary hypertension. The cardiac presentation is not consistent with a cardiogenic cause of the patient's exercise intolerance or respiratory abnormalities. No indication for cardiac medications.

BREED

Terrier Mix

SEX

FS

AGE

3 yr

WEIGHT

45 lb

INTERPRETED BY

R. McKenzie Daniel,
DVM, DABVP
(Canine and Feline)

IMAGING PERFORMED BY

Jessica Miller

HOSPITAL NAME

Warren Animal Hospital

REFERRING VET

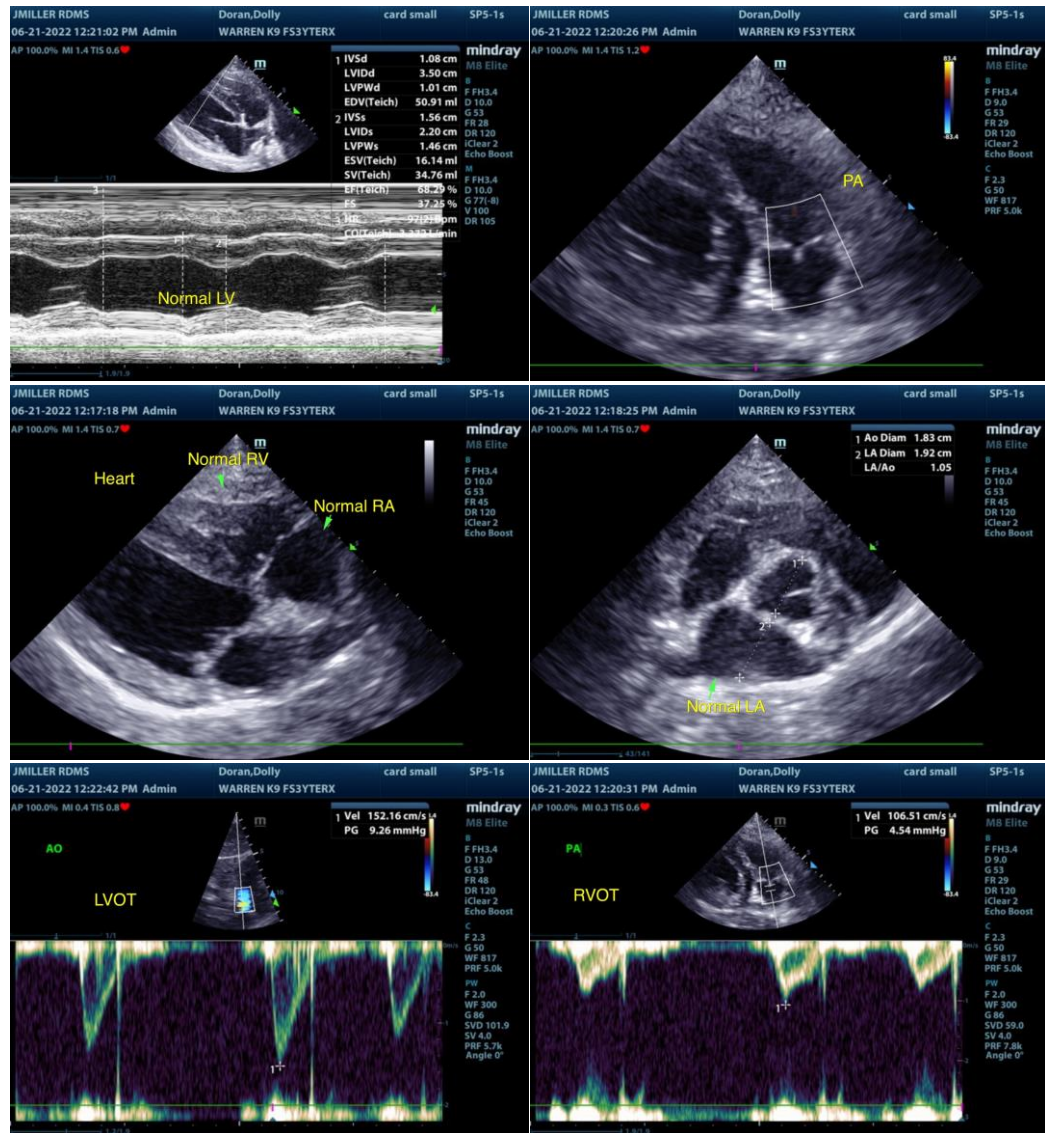
Dr. Nicole

INVOICE

10881ag

DATE

06/21/2022



The information and recommendations provided are based on the images presented by the referring veterinarian/sonographer. No evaluation can be communicated regarding pathology that was not visible in the image/video clips provided.

Thank you for this referral. If the clinical or image interpretation does not parallel your findings or if I can be of any further assistance please contact me.

R. McKenzie Daniel, DVM, DABVP (Canine / Feline Practice)



PATIENT

info@SonoPath.com

Dolly Doran

SPECIES

Canine

BREED

Terrier Mix

SEX

FS

AGE

3 yr

WEIGHT

45 lb

INTERPRETED BY

R. McKenzie Daniel,
DVM, DABVP
(Canine and Feline)

**IMAGING
PERFORMED BY**

Jessica Miller

HOSPITAL NAME

Warren Animal Hospital

REFERRING VET

Dr. Nicole

INVOICE

10881ag

DATE

06/21/2022