

**PATIENT**

Baby Cat Loudon

**SPECIES**

Feline

**BREED**

DSH

**SEX**

FS

**AGE**

12

**WEIGHT**

10

**INTERPRETED BY**R. McKenzie Daniel,  
DVM, DABVP  
(Canine and Feline)**IMAGING  
PERFORMED BY**

Rachel Runnells RVT

**HOSPITAL NAME**

SVS Imaging KC

**REFERRING VET**

Dr. Kristine Mulloy

**INVOICE**

10872ag

**DATE**

06/21/2022

**PRESENTING CLINICAL SIGNS**

History: Have been seeing this patient since June 6th for not wanting to eat on her own, not drinking well, and being lethargic.

Abnormal PE/Chem/CBC/UA Results: CBC= high WBC's. Chem= high BUN, Creatinine, Amylase, and Phosphorus. Decreased K+. Constipation in distal colon on rads.

**ULTRASONOGRAPHIC EXAMINATION OF THE ABDOMEN****Urinary System**

The urinary bladder, trigone, cystourethral junction, and visible pelvic urethra to a depth of 2 cm exhibited normal thickness and tone. Anechoic urine was present in the lumen with no uroliths or sediment. The ureteral papillae were normal. The ureters were not visible which is normal. No evidence of inflammatory or neoplastic changes were noted.

Normal size and margination were present in the kidneys. A normal 1:3 cortex / medulla ratio and normal corticomedullary definition were maintained. Subtly nonuniform increased cortex echogenicity with mild loss of corticomedullary border demarcation was present. A very subtle hyperechoic corticomedullary band consistent with medullary rim sign was present bilaterally. This is a nonspecific finding yet may be associated with interstitial renal disease, hypercalcemia, tubular necrosis or less likely lymphoma/FIP. Minor pyelectasia was present bilaterally. The left kidney measured 4.4 cm in length. The right kidney measured 4.7 cm in length.

The area of the aortic trifurcation was free of pathology.

**Adrenal Glands**

The left adrenal gland was uniform in size and contour with a uniformly hypoechoic parenchyma. The left adrenal gland measured 0.40 cm. The right adrenal gland was uniform in size and contour with a uniformly hypoechoic parenchyma. The right adrenal gland measured 0.45 cm. No evidence of neoplastic criteria was observed.

**Spleen**

The spleen exhibited a finely textured and homogenous parenchyma which was hyperechoic to the liver and renal cortical parenchyma. The capsule was smooth and regular without apparent expansion. The splenic vasculature at the hilus was normal in volume with no evidence of congestion or thrombosis. Acute to chronic inflammatory, neoplastic, or benign parenchyma changes were not noted.

**Liver**

The liver was subjectively normal in size, structure, and contour. The liver parenchyma was mildly nonuniform and hypoechoic to the spleen with a moderate coarse echotexture and subjective mild to benign parenchymal remodeling. The hepatic and portal vasculature were normal in appearance without signs of congestion.

The gallbladder was subtly distended with thin walls and primarily anechoic luminal content including mild nondependent hyperechoic luminal debris. The cystic and common bile ducts were normal.

**Gastrointestinal**

The stomach presented intact wall layering with a normal wall layer ratio. The lumen of the stomach contained minor nonspecific ingesta/chyme with no signs of ileus, obstruction or foreign material. The gastric body wall measured 0.25 cm in width.

**PATIENT**

Baby Cat Loudon

The small intestine presented intact wall layering with 1:3 muscularis/mucosa ratio. Mild segmental non obstructive ileus pattern was present. The lumen of the small intestine was empty with no signs of obstruction, foreign material or masses. The duodenum wall measured 0.24 cm in width. The jejunum wall measured 0.20 cm in width. The ileocolic wall measured 0.46 cm in width.

**SPECIES**

Feline

Normal visible colon wall layers were present with apparent formed feces in lumen.

**Pancreas****BREED**

DSH

The left limb, right limb, and base of the pancreas presented subtly hypoechoic to nonhomogeneous echogenicity compared to adjacent omental fat. Mild asymmetrical capsule margination was present with mild variable parenchymal swelling and subjective mild peripancreatic reactivity / inflammation. No overt evidence of neoplasia.

**SEX**

FS

**Free Abdomen**

No overt lymphadenopathy or peritoneal effusion was present.

**AGE**

12

**ULTRASONOGRAPHIC FINDINGS**

- Nonspecific chronic renal changes with minor pyelectasia and subtle medullary rim sign-chronic renal disease, non-specific nephritis such as interstitial nephritis or other nephropathy possible. No overt evidence of renal neoplastic criteria.
- Low grade pancreatitis pattern
- Structurally normal GI tract with mild retained gastric ingesta and minor nonobstructive SI ileus
- Minor gallbladder debris-non-specific, potentially secondary to fasting or non-clinical cholestasis

**WEIGHT**

10

**INTERPRETATION OF THE FINDINGS & FURTHER RECOMMENDATIONS****INTERPRETED BY**R. McKenzie Daniel,  
DVM, DABVP  
(Canine and Feline)

Further renal staging to include UA, urine C/S and protein: creatinine ratio on sterile urine sample may be considered.

**IMAGING PERFORMED BY**

Rachel Runnells RVT

Low grade pancreatitis may be a primary contributing factor to the patient's inappetence and lethargy and may be suspected if evidence of cranial abdominal or subxiphoid discomfort on palpation. Potential for structurally insignificant concurrent GI disease cannot be excluded. A GI panel to include PLI/TLI/Cobalamin/Folate is recommended.

**HOSPITAL NAME**

SVS Imaging KC

Depending on the degree of azotemia hospitalization with 48-72 hour IVF therapy and GI support protocol may prove beneficial. Assessment for possible acute on chronic renal injury may be considered if no previous documentation of azotemia.

**REFERRING VET**

Dr. Kristine Mulloy

A CBC pathology review could be considered given the elevated WBC.

**INVOICE**

10872ag

**DATE**

06/21/2022

IMAGING PERFORMED BY

SVS Mobile Imaging KC 816-401-5010  
svsimagingkc@gmail.com



Clinical Sonography & Telectology

EDUCATIONAL TELECONSULTATION SERVICES™

1-800-838-4268 info@sonopath.com SonoPath.com

PATIENT

Baby Cat Loudon

SPECIES

Feline

BREED

DSH

SEX

FS

AGE

12

WEIGHT

10

INTERPRETED BY

R. McKenzie Daniel,  
DVM, DABVP  
(Canine and Feline)

IMAGING PERFORMED BY

Rachel Runnells RVT

HOSPITAL NAME

SVS Imaging KC

REFERRING VET

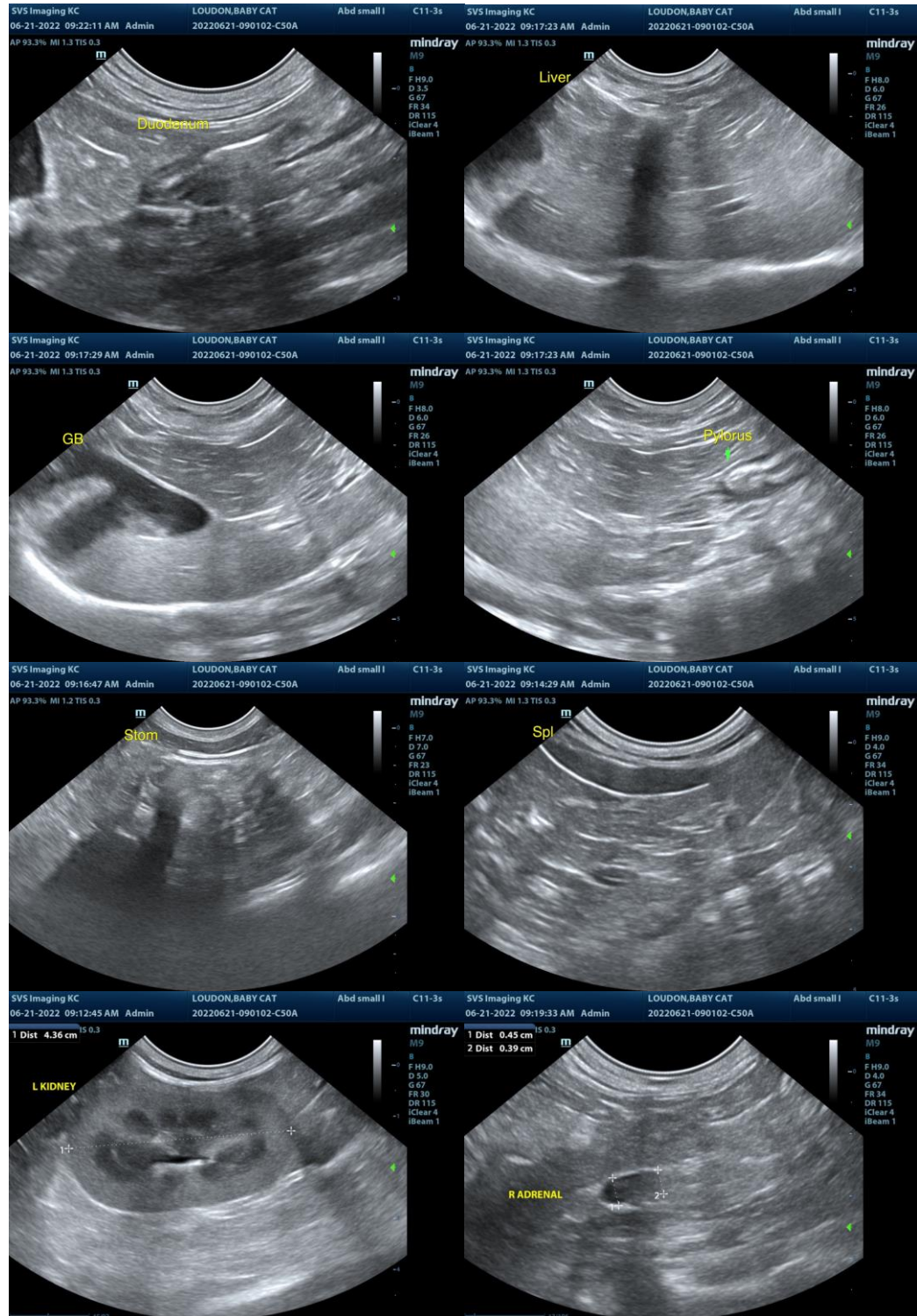
Dr. Kristine Mulloy

INVOICE

10872ag

DATE

06/21/2022





**PATIENT**

Baby Cat Loudon

**SPECIES**

Feline

**BREED**

DSH

**SEX**

FS

**AGE**

12

**WEIGHT**

10

**INTERPRETED BY**

R. McKenzie Daniel,  
DVM, DABVP  
(Canine and Feline)

**IMAGING PERFORMED BY**

Rachel Runnells RVT

**HOSPITAL NAME**

SVS Imaging KC

**REFERRING VET**

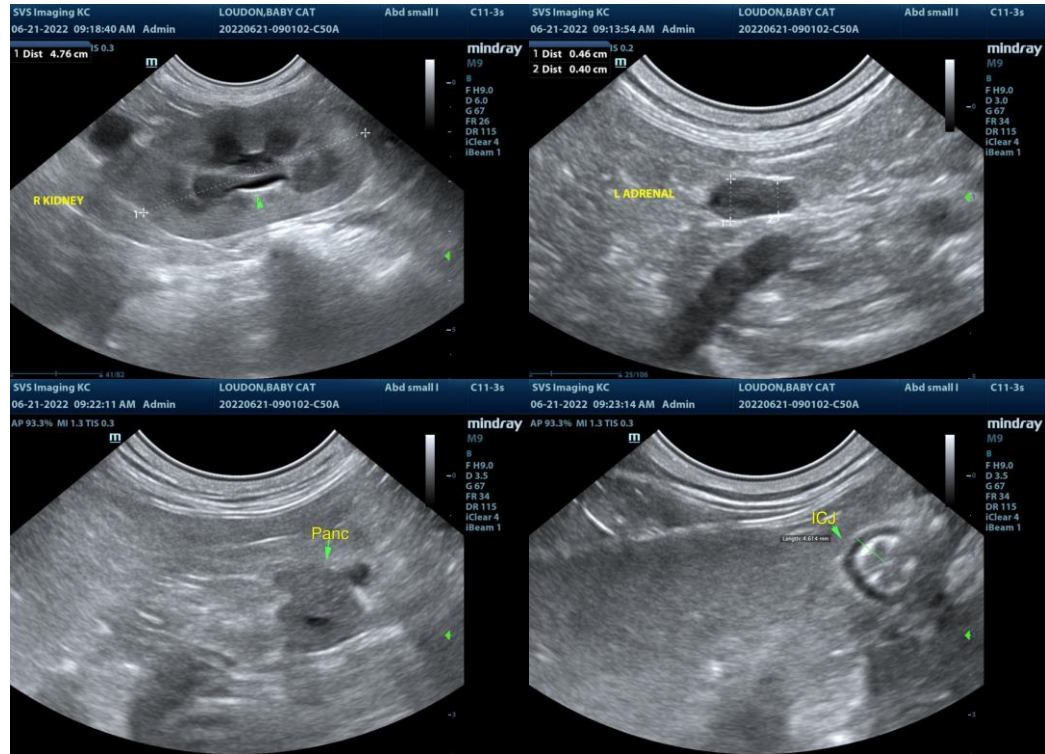
Dr. Kristine Mulloy

**INVOICE**

10872ag

**DATE**

06/21/2022



The information and recommendations provided are based on the images presented by the referring veterinarian/sonographer. No evaluation can be communicated regarding pathology that was not visible in the image/video clips provided.

Thank you for this referral. If the clinical or image interpretation does not parallel your findings or if I can be of any further assistance please contact me.

R. McKenzie Daniel, DVM, DABVP (Canine / Feline Practice)

info@SonoPath.com