


PATIENT

Sarga Orbeck

SPECIES

Canine

BREED

Vizsla

SEX

Spayed Female

AGE

11 Years

WEIGHT

53 Pounds

PRESENTING CLINICAL SIGNS

Lethargic, decreased appetite for the past 3 days, Heavy breathing and coughing the past month. Has progressively gotten worse. Dribbles urine while laying down. No vomiting. Temp 102.6
 Abnormal PE/Chem/CBC/UA Results: CBC=34.7, Lipase=1801, UA= WBC 1+, Protein 1+

ULTRASONOGRAPHIC EXAMINATION OF THE HEART & ABDOMEN

CANINE CARDIAC PARAMETERS	MR VMAX (m/s)	TR VMAX (m/s)	LA/AO (Boon method)	LA/AO (Heart Base; Swe)	FS (%)	EF (%)	EPSS (cm)
NORMAL PARAMETER	4.5-5.5	<2.7	1.3	<1.6	28-40	40-100	<0.6
PATIENT	5.0		NM	1.35	25	54.8	0.22
CANINE CARDIAC PARAMETERS	HR (BPM)	AV VMAX (m/s)	PV MAX (m/s)	BODY WEIGHT (kg)	LA 2D short axis Base view (cm)	LVIDd Avg; 2D and m-mode short axis (cm)	LVIDs Avg; 2D and m-mode short axis (cm)
NORMAL PARAMETER	50-100	0.7-1.7	0.7-1.6	BELOW	BELOW	BELOW	BELOW
PATIENT	--	1.0	0.75		4.2	4.4	

INTERPRETED BY

 R. McKenzie Daniel,
 DVM, DABVP
 (Canine and Feline)

IMAGING PERFORMED BY

Nicole Gotfredson

HOSPITAL NAME

Buffalo Vet Center

REFERRING VET

Dr. Teresa Bessler

Cardiac Presentation

The echocardiogram in this patient demonstrated normal **left atrial** size based on 3 different LA measurement methods. Chamber volumes and echogenicity were normal. The mitral valve was mildly thickened. No evidence of chordae tendineae rupture or valvular prolapse. Doppler indicated measurable, subjective mild eccentric insufficiency. The **left ventricle** presented thicknesses with linear contour and was not dilated nor restricted. The **myocardium** presented normal echogenicity without subjective evidence of significant fibrotic or ischemic disease. **Contractility** of the ventricular walls was mildly subnormal as evidenced by the fractional shortening measurement and subjective evaluation of the different regions of the myocardium. The **left ventricular outflow** tract demonstrated normal laminar flow and subjective structural integrity. The **right atrium** and auricle revealed normal size, structure and content. No evidence of masses was noted or chamber overload. **Tricuspid** valvular assessment demonstrated adequate linear morphology. The **right ventricle** was of normal size (1/3 diameter of LV), chordae structure, myocardial echogenicity and thickness. **Pulmonic** tract assessment revealed normal valve structure, laminar flow, and diameter (approx.1:1 pa/ao ratio). No visible **pericardial** or free pleura fluid was noted. No echographically detectable evidence of infiltrative disease was visible. The cranial **mediastinum** and **pericardial regions** were free of masses in the visible window.

Urinary System
INVOICE

38911

DATE

6/20/22

The urinary bladder, trigone, cystourethral junction, and visible pelvic urethra to a depth of 3.0 cm exhibited normal thickness and tone. Anechoic urine was present in the lumen with no uroliths or sediment. The ureteral papillae were normal. The ureters were not visible which is normal. No evidence of inflammatory or neoplastic changes were noted.

The area of the aortic trifurcation was free of pathology. No evidence of medial iliac or sublumbar lymphadenopathy.



PATIENT

Sarga Orbeck

Normal size and margination were present in the kidneys. A normal 1:3 cortex / medulla ratio and normal corticomedullary definition were maintained. The echogenicity of the cortex was similar to or slightly less than normal liver parenchyma while the medulla echogenicity was hypoechoic to the cortex with no evidence of pelvic dilation. The left kidney measured 6.5 cm. The right kidney measured 6.4 cm.

SPECIES

Canine

Adrenal Glands

The left adrenal gland was indistinctly visualized, yet overtly normal in size, position and shape. The caudal pole measured 0.62 cm.

BREED

Vizsla

The right adrenal gland was not definitively visualized.

SEX

Spayed Female

Spleen

The spleen exhibited a finely textured and homogenous parenchyma which was hyperechoic to the liver and renal cortical parenchyma. The capsule was smooth and regular without apparent expansion. The splenic vasculature at the hilus was normal in volume with no evidence of congestion or thrombosis. Acute to chronic inflammatory, neoplastic, or benign parenchyma changes were not noted.

AGE

11 Years

Liver

The liver exhibited potential mild enlargement. The parenchyma of the liver was subjectively normal in echogenicity compared to the spleen and renal cortices. The liver parenchyma was uniform with a mildly coarse echotexture. The capsule of the liver was symmetrically rounded to mildly swollen in margination. The hepatic and portal vasculature were normal in appearance without signs of congestion. The gallbladder was non-distended in size with primarily anechoic luminal content. The cystic and common bile ducts were normal

WEIGHT

53 Pounds

Gastrointestinal

INTERPRETED BY

R. McKenzie Daniel,
DVM, DABVP
(Canine and Feline)

The stomach presented intact wall layering with a normal wall layer ratio. The lumen of the stomach was empty with no signs of ileus, obstruction or foreign material.

The small intestine presented intact wall layering with 1:3 muscularis/mucosa ratio. The lumen of the small intestine was empty with no signs of ileus, obstruction or foreign material.

IMAGING PERFORMED BY

Nicole Gotfredson

Normal visible colon wall layers were present with apparent formed feces in lumen.

HOSPITAL NAME

Buffalo Vet Center

Pancreas

The parenchyma of the left limb, body and right limb of the pancreas presented isoechoic to the adjacent omental fat. A normal curvilinear capsule contour of the pancreas was present. The visible pancreatic duct was normal. No signs of active inflammation or neoplastic disease was evident.

REFERRING VET

Dr. Teresa Bessler

Free Abdomen

No omental masses, lymphadenopathy or peritoneal free fluid.

ULTRASONOGRAPHIC FINDINGS

INVOICE

38911

- Chronic mitral valve disease (ACVIM B1)
- Mild subnormal LV contractility – non-specific, patient/age related variant, athletic state, hypothyroidism, or non-specific systemic disease possible.
- Mild vacuolar hepatopathy pattern – subjectively benign.

DATE

6/20/22



PATIENT

Sarga Orbeck

- Overtly normal gastrointestinal tract
- Overtly normal pancreas – no sonographic evidence of active pancreatic inflammation, potential for low-grade to chronic pancreatitis, which may present sonographically normal.

SPECIES

Canine

- Mild chronic renal changes.
- Normal urinary bladder and visible proximal urethra.

BREED

Vizsla

INTERPRETATION OF THE FINDINGS & FURTHER RECOMMENDATIONS

Overall, the cardiac presentation was not overtly consistent with cardiogenic respiratory abnormalities, and without clinical issues such as overt clinical pulmonary hypertension. Assessment for potential primary upper versus lower airway disease indicated. Given the lack of left or right heart chamber enlargement, no overt indication for cardiac medications.

SEX

Spayed Female

Overall, mild geriatric abdomen without evidence of significant visceral pathology as a primary or contributing factor to the patient’s clinical signs. Assessment of T4 levels recommended if not done. As needed gastrointestinal support recommended. A spec cPL could be considered for further assessment of the pancreas.

AGE

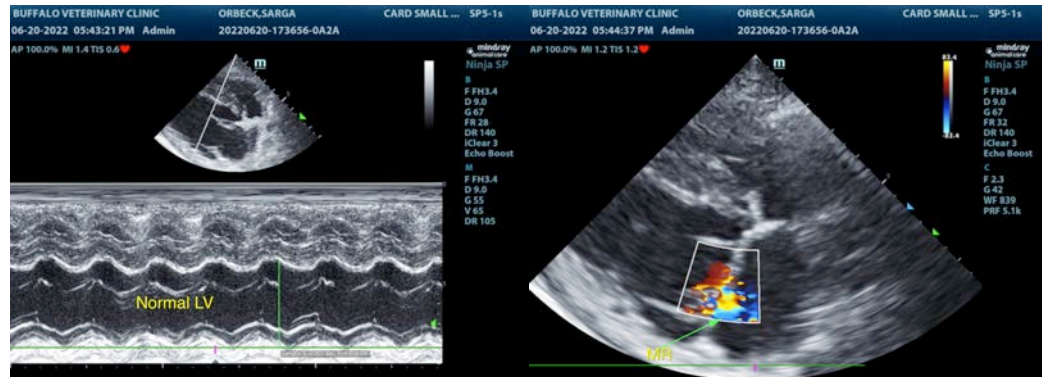
11 Years

WEIGHT

53 Pounds

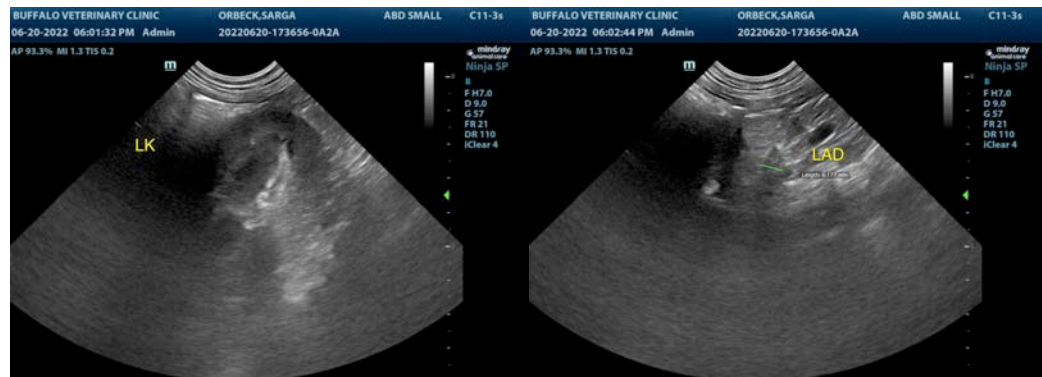
INTERPRETED BY

R. McKenzie Daniel,
DVM, DABVP
(Canine and Feline)



IMAGING PERFORMED BY

Nicole Gotfredson



HOSPITAL NAME

Buffalo Vet Center

REFERRING VET

Dr. Teresa Bessler

INVOICE

38911

DATE

6/20/22



PATIENT

Sarga Orbeck

SPECIES

Canine

BREED

Vizsla

SEX

Spayed Female

AGE

11 Years

WEIGHT

53 Pounds

INTERPRETED BY

R. McKenzie Daniel,
DVM, DABVP
(Canine and Feline)

IMAGING PERFORMED BY

Nicole Gotfredson

HOSPITAL NAME

Buffalo Vet Center

REFERRING VET

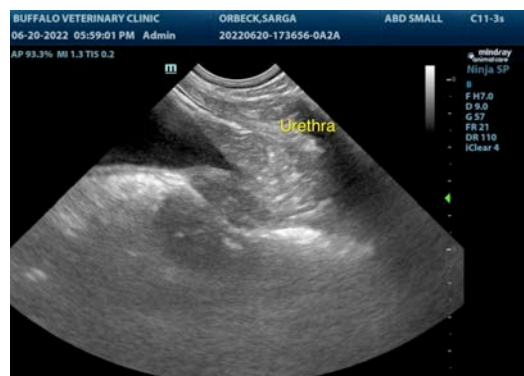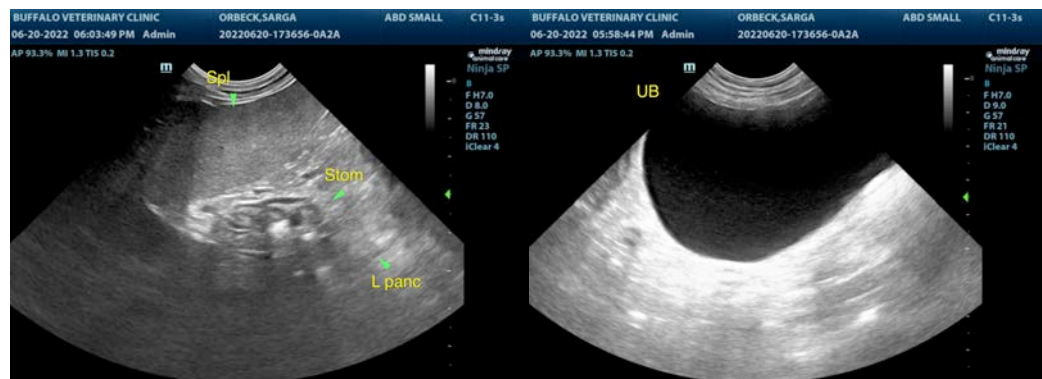
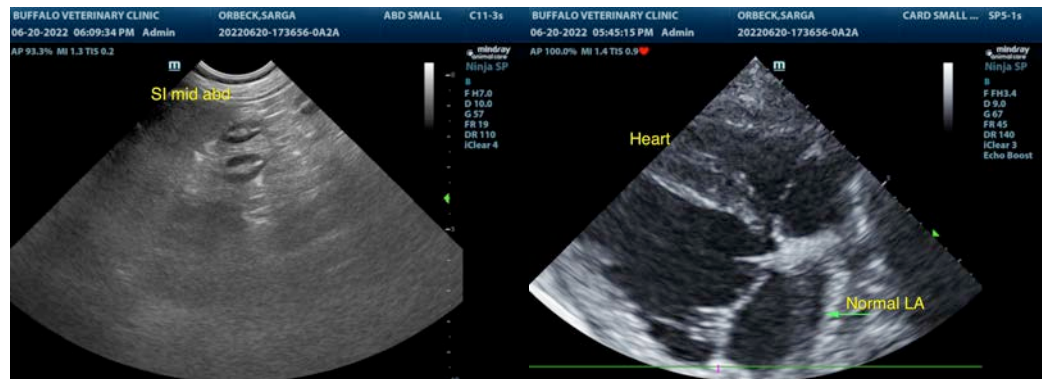
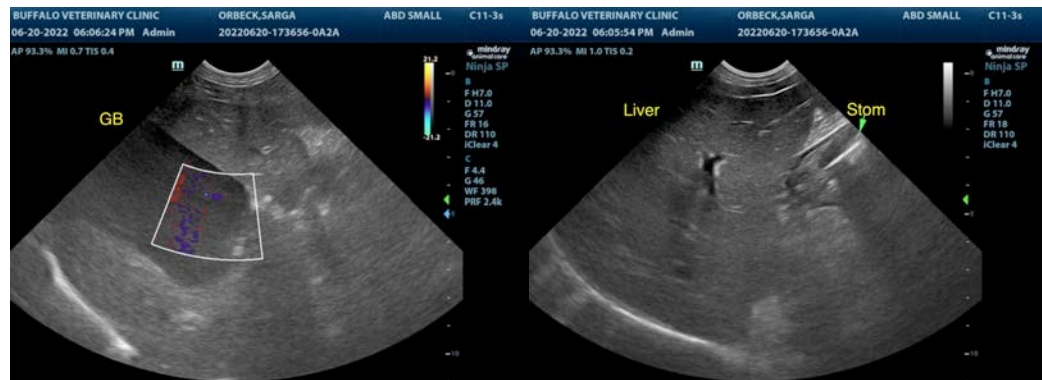
Dr. Teresa Bessler

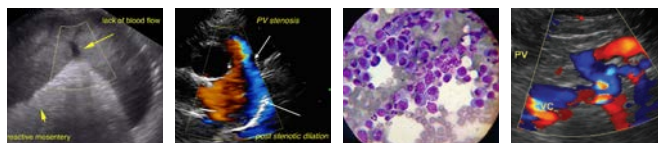
INVOICE

38911

DATE

6/20/22





PATIENT

Sarga Orbeck

SPECIES

Canine

BREED

Vizsla

SEX

Spayed Female

AGE

11 Years

WEIGHT

53 Pounds

INTERPRETED BY

R. McKenzie Daniel,
DVM, DABVP
(Canine and Feline)

**IMAGING
PERFORMED BY**

Nicole Gotfredson

HOSPITAL NAME

Buffalo Vet Center

REFERRING VET

Dr. Teresa Bessler

INVOICE

38911

DATE

6/20/22

The information and recommendations provided are based on the images presented by the referring veterinarian/sonographer. No evaluation can be communicated regarding pathology that was not visible in the image/video clips provided.

Thank you for this referral. If the clinical or image interpretation does not parallel your findings or if I can be of any further assistance please contact me.

R. McKenzie Daniel, DVM, DABVP (Canine / Feline Practice)

info@SonoPath.com