



PATIENT

George Will

SPECIES

Canine

BREED

Goldendoodle

SEX

Male

AGE

7Y, 5M

WEIGHT

73.4lbs

INTERPRETED BY

R. McKenzie Daniel,
DVM, DABVP
(Canine and Feline)

IMAGING PERFORMED BY

Ashley Whitesell

HOSPITAL NAME

Dickson Animal
Clinic

REFERRING VET

Peyton Bramlett

INVOICE

75270

DATE

6-2-26

PRESENTING CLINICAL SIGNS

Pt grunts, lurches, and whines when palpated between the caudal end of the penis, but cranial to the testicles

X-rays suspicious for prostatic inflammation vs mass vs other
Rectal exam WNL

ULTRASONOGRAPHIC EXAMINATION OF THE ABDOMEN

Urinary System

The urinary bladder, trigone, cystourethral junction, and visible pelvic urethra to a depth of 3.0 cm exhibited normal thickness and tone. Anechoic urine was present in the lumen with no uroliths or sediment. The ureteral papillae were normal. The ureters were not visible, which is normal. No evidence of inflammatory or neoplastic changes was noted.

The prostate was mildly enlarged in size with intact, symmetrical capsule contour. The margins of the gland were intact and able to be differentiated from the surrounding tissue. The prostatic parenchyma was mildly echogenic to heteroechoic without parenchymal mineralization. The prostate measured 3.5 cm in diameter. Intermittent small parenchymal cysts were present.

The left and right testicle presented sonographically normal.

No evidence of pathology in the area of the aortic trifurcation.

Normal size and margination were present in the kidneys. A normal 1:3 cortex / medulla ratio and normal corticomedullary definition were maintained. The echogenicity of the cortex was similar to or slightly less than normal liver parenchyma while the medulla echogenicity was hypoechoic to the cortex with no evidence of pelvic dilation. The left kidney measured 7.7 cm in length. The right kidney measured 7.3 cm in length.

Adrenal Glands

The left adrenal gland was uniform in size and contour with a uniformly hypoechoic parenchyma. The left adrenal gland measured 0.54 cm width at the caudal pole. The right adrenal gland was uniform in size and contour with a uniformly hypoechoic parenchyma. The right adrenal gland measured 0.81 cm width at the caudal pole.

Spleen

The spleen exhibited a finely textured and homogenous parenchyma which was hyperechoic to the liver and renal cortical parenchyma. The capsule was smooth and regular without apparent expansion. The splenic vasculature at the hilus was normal in volume with no evidence of congestion or thrombosis. Acute to chronic inflammatory, neoplastic, or benign parenchyma changes were not noted.

Liver/ Gallbladder

The liver was subjectively normal in size, structure, and contour. Normal hepatic vascular volume was present. The liver parenchyma was uniform and hypoechoic to the spleen with a mild coarse echotexture. The hepatic and portal vasculature were normal in appearance without signs of congestion. The gallbladder was non-distended in size with thin walls and primarily anechoic luminal content. The cystic and common bile ducts were normal.



PATIENT

George Will

SPECIES

Canine

BREED

Goldendoodle

SEX

Male

AGE

7Y, 5M

WEIGHT

73.4lbs

INTERPRETED BY

R. McKenzie Daniel,
DVM, DABVP
(Canine and Feline)

IMAGING PERFORMED BY

Ashley Whitesell

HOSPITAL NAME

Dickson Animal
Clinic

REFERRING VET

Peyton Bramlett

INVOICE

75270

DATE

6-2-26

Gastrointestinal

The stomach presented intact wall layering with a normal wall layer ratio. The lumen of the stomach was empty without evidence of retained ingesta, fluid, or foreign material.

The small intestine presented intact wall layering with 1:3 muscularis/mucosa ratio. The lumen of the small intestine was empty with no signs of ileus, obstruction, or foreign material.

Normal visible colon wall layers were present with formed feces in lumen.

Pancreas

The parenchyma of the left limb, body and right limb of the pancreas presented isoechoic to the adjacent omental fat. A normal curvilinear capsule contour of the pancreas was present. The visible pancreatic duct was normal. No signs of active inflammation or neoplastic disease were evident.

Free Abdomen

No overt lymphadenopathy or peritoneal effusion was present.

ULTRASONOGRAPHIC FINDINGS

Primary Findings

- Mildly enlarged nonhomogeneous cystic prostate – suggestive of benign prostatic hyperplasia with benign parenchymal cysts. Potential for prostatitis thought less likely yet not excluded. No evidence of prostatic neoplastic criteria.
- Sonographically normal urinary bladder and visible proximal urethra.

Secondary Findings

-

INTERPRETATION OF THE FINDINGS & FURTHER RECOMMENDATIONS

No evidence of prostatic or abdominal neoplastic criteria. Further assessment of the prostate may include prostatic sampling either via ultrasound guided FNA or prostatic wash for cytology +/- C/S, if clinically indicated. Aside from the prostate, no evidence of pathology as an obvious cause of the patient's clinical signs.



PATIENT

George Will

SPECIES

Canine

BREED

Goldendoodle

SEX

Male

AGE

7Y, 5M

WEIGHT

73.4lbs

INTERPRETED BY

R. McKenzie Daniel,
DVM, DABVP
(Canine and Feline)

IMAGING PERFORMED BY

Ashley Whitesell

HOSPITAL NAME

Dickson Animal
Clinic

REFERRING VET

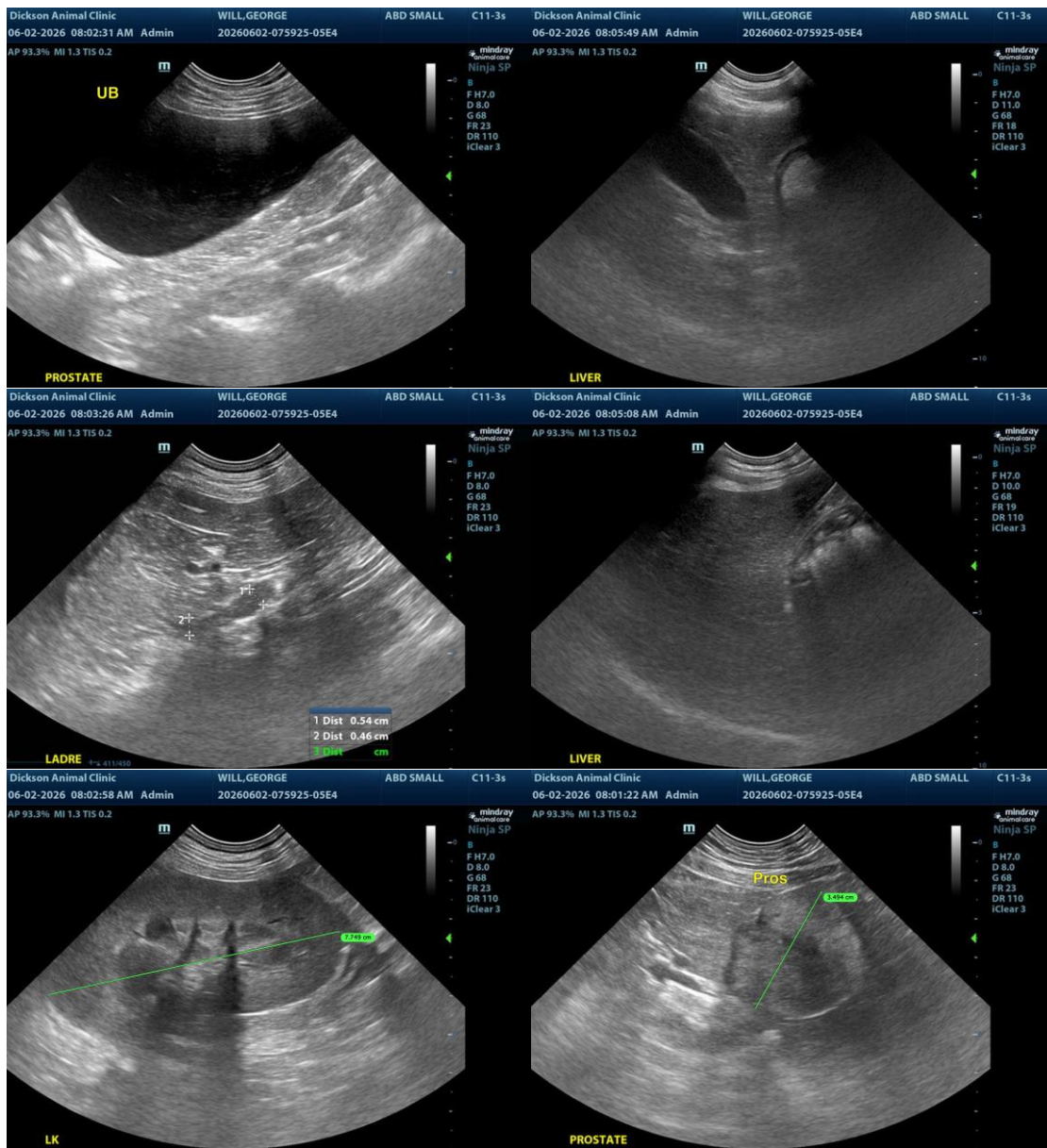
Peyton Bramlett

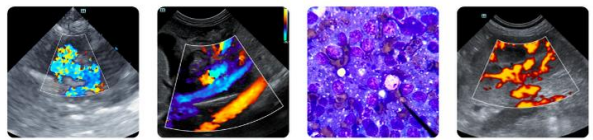
INVOICE

75270

DATE

6-2-26





PATIENT

George Will

SPECIES

Canine

BREED

Goldendoodle

SEX

Male

AGE

7Y, 5M

WEIGHT

73.4lbs

INTERPRETED BY

R. McKenzie Daniel,
DVM, DABVP
(Canine and Feline)

IMAGING PERFORMED BY

Ashley Whitesell

HOSPITAL NAME

Dickson Animal
Clinic

REFERRING VET

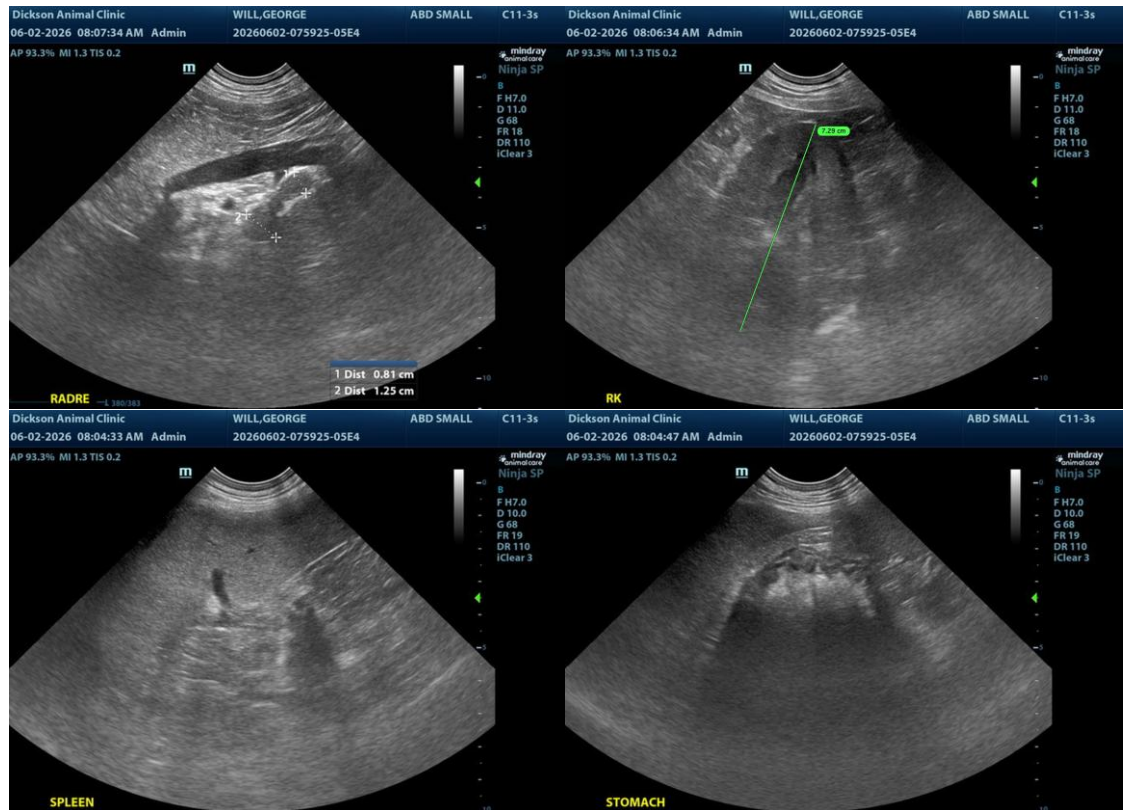
Peyton Bramlett

INVOICE

75270

DATE

6-2-26



The information and recommendations provided are based on the images presented by the referring veterinarian/sonographer. No evaluation can be communicated regarding pathology that was not visible in the image/video clips provided.

Thank you for this referral. If the clinical or image interpretation does not parallel your findings or if I can be of any further assistance, please contact me.

R. McKenzie Daniel, DVM, DABVP (Canine/Feline Practice)

info@sonopath.com