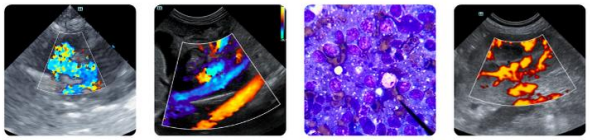

PATIENT
Coco Yamonaco

SPECIES
Canine

BREED
Boxer

SEX
Female Spayed

AGE
6Y, 9M

WEIGHT
64lbs

INTERPRETED BY
R. McKenzie Daniel, DVM, DABVP (Canine and Feline)

IMAGING PERFORMED BY
Brandi Kurzowski

HOSPITAL NAME
Corfu Veterinary Clinic

REFERRING VET
Dr. Nicole Kelver

INVOICE
75266

DATE
6-2-26

PRESENTING CLINICAL SIGNS

P presented 5/21/26 for vomiting approx 3 times/week - white foamy w undigested, food, and grass. P is eating/drinking well. P is on pepcid BID prior to meals, ondansetron was added on at this visit. P also takes carprofen and proin. Stools are softer than normal, but no diarrhea. P not acting like herself. O notes that p did vomit this morning prior to ultrasound. TLI/PLI/Folate/Cobalamin sent out to Texas A&M today.
Abnormal PE/Chem/CBC/UA Results: 5/22/26 CBC: Lymph 0.906 (0.98-4.2), rest WNL Chem: Glob 4.2 (2.4-4.0), Chol 382 (131-345), rest WNL T4: 1.3 (1-4) 4DX neg x 4 Fecal- NPS 6/2/26 GI panel pending

ULTRASONOGRAPHIC EXAMINATION OF THE ABDOMEN

Urinary System

The urinary bladder, trigone, cystourethral junction, and visible pelvic urethra exhibited normal thickness and tone. Anechoic urine was present in the lumen with no uroliths or sediment. The ureteral papillae were normal. The ureters were not visible, which is normal. No evidence of inflammatory or neoplastic changes was noted.

No evidence of pathology in the area of the aortic trifurcation.

Normal size and margination were present in the kidneys. A normal 1:3 cortex / medulla ratio and normal corticomedullary definition were maintained. The echogenicity of the cortex was similar to or slightly less than normal liver parenchyma while the medulla echogenicity was hypoechoic to the cortex with no evidence of pelvic dilation. The left kidney measured 5.9 cm in length. The right kidney measured 6.1 cm in length.

Adrenal Glands

The left and right adrenal glands were not definitively visualized. No overt pathology in the area of the right and left adrenal glands.

Spleen

The spleen exhibited a finely textured and homogenous parenchyma which was hyperechoic to the liver and renal cortical parenchyma. The capsule was smooth and regular without apparent expansion. The splenic vasculature at the hilus was normal in volume with no evidence of congestion or thrombosis. Acute to chronic inflammatory, neoplastic, or benign parenchyma changes were not noted.

Liver/ Gallbladder

The liver was subjectively normal in size, structure, and contour. Normal hepatic vascular volume was present. The liver parenchyma was uniform and hypoechoic to the spleen with a mild coarse echotexture. The hepatic and portal vasculature were normal in appearance without signs of congestion.

The gallbladder was not definitively visualized. No obvious pathology in the area of the gallbladder or area of the common bile duct.

Gastrointestinal

The stomach presented intact wall layering with a normal wall layer ratio. The lumen of the stomach was empty without evidence of retained ingesta, fluid, or foreign material.

PATIENT
Coco Yamonaco

SPECIES
Canine

BREED
Boxer

SEX
Female Spayed

AGE
6Y, 9M

WEIGHT
64lbs

INTERPRETED BY
R. McKenzie Daniel, DVM, DABVP (Canine and Feline)

IMAGING PERFORMED BY
Brandi Kurzowski

HOSPITAL NAME
Corfu Veterinary Clinic

REFERRING VET
Dr. Nicole Kelver

INVOICE
75266

DATE
6-2-26

The small intestine presented intact wall layering with 1:3 muscularis/mucosa ratio. The lumen of the small intestine was empty with no signs of ileus, obstruction, or foreign material.

Normal visible colon wall layers were present with semi-formed fecal matter in lumen.

Pancreas

The parenchyma of the left limb, body and right limb of the pancreas presented isoechoic to the adjacent omental fat. A normal curvilinear capsule contour of the pancreas was present. The visible pancreatic duct was normal. No signs of active inflammation or neoplastic disease were evident.

Free Abdomen

No overt lymphadenopathy or peritoneal effusion was present.

ULTRASONOGRAPHIC FINDINGS

- Sonographically normal empty gastrointestinal tract.
- Normal area of the pancreas.
- Semi-formed fecal matter in colon.

INTERPRETATION OF THE FINDINGS & FURTHER RECOMMENDATIONS

No evidence of visceral, specifically gastroenterocolic or pancreatic, pathology. Correlation with pending GI panel to assess for nonstructural microscopic gastrointestinal disease or mild pancreatitis which may present sonographically normal.

Given non-visualized adrenal glands, concurrent screening cortisol level is suggested.

Supportive care including bland or hydrolyzed diet trial, continued as needed gastroprotectants, and cobalamin supplementation, pending assessment of cobalamin level, may prove beneficial. Empirical deworming panacur 50mg/kg SID for 5 days with repeat protocol in 3 weeks suggested despite negative fecal testing.

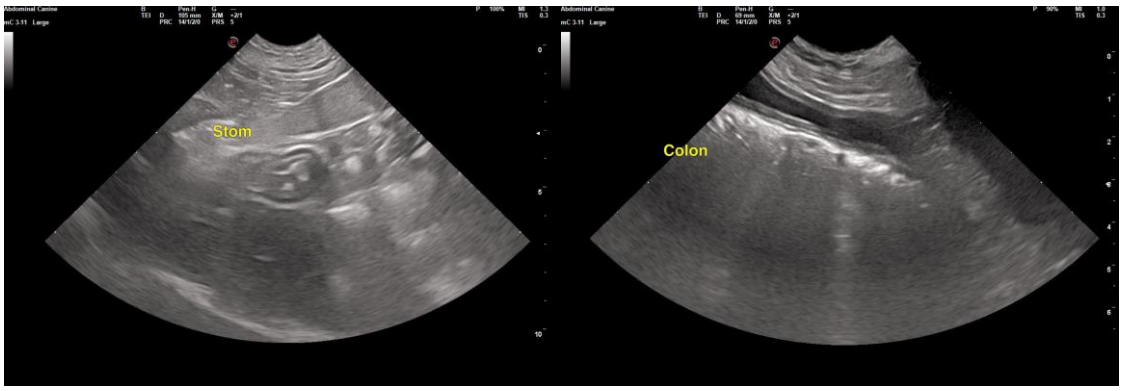

SonoPath
FOSTERING THE ART OF VETERINARY MEDICINE™

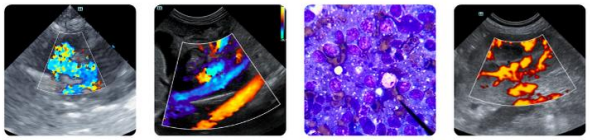

Clinical Sonography & Telecytology
Educational Teleconsultation Services™

SonoPath.com info@sonopath.com 1.800.838.4268

PATIENT

Coco Yamonaco

SPECIES

Canine

BREED

Boxer

SEX

Female Spayed

AGE

6Y, 9M

WEIGHT

64lbs

INTERPRETED BY

R. McKenzie Daniel, DVM, DABVP (Canine and Feline)

IMAGING PERFORMED BY

Brandi Kurzowski

HOSPITAL NAME

Corfu Veterinary Clinic

REFERRING VET

Dr. Nicole Kelver

INVOICE

75266

DATE

6-2-26

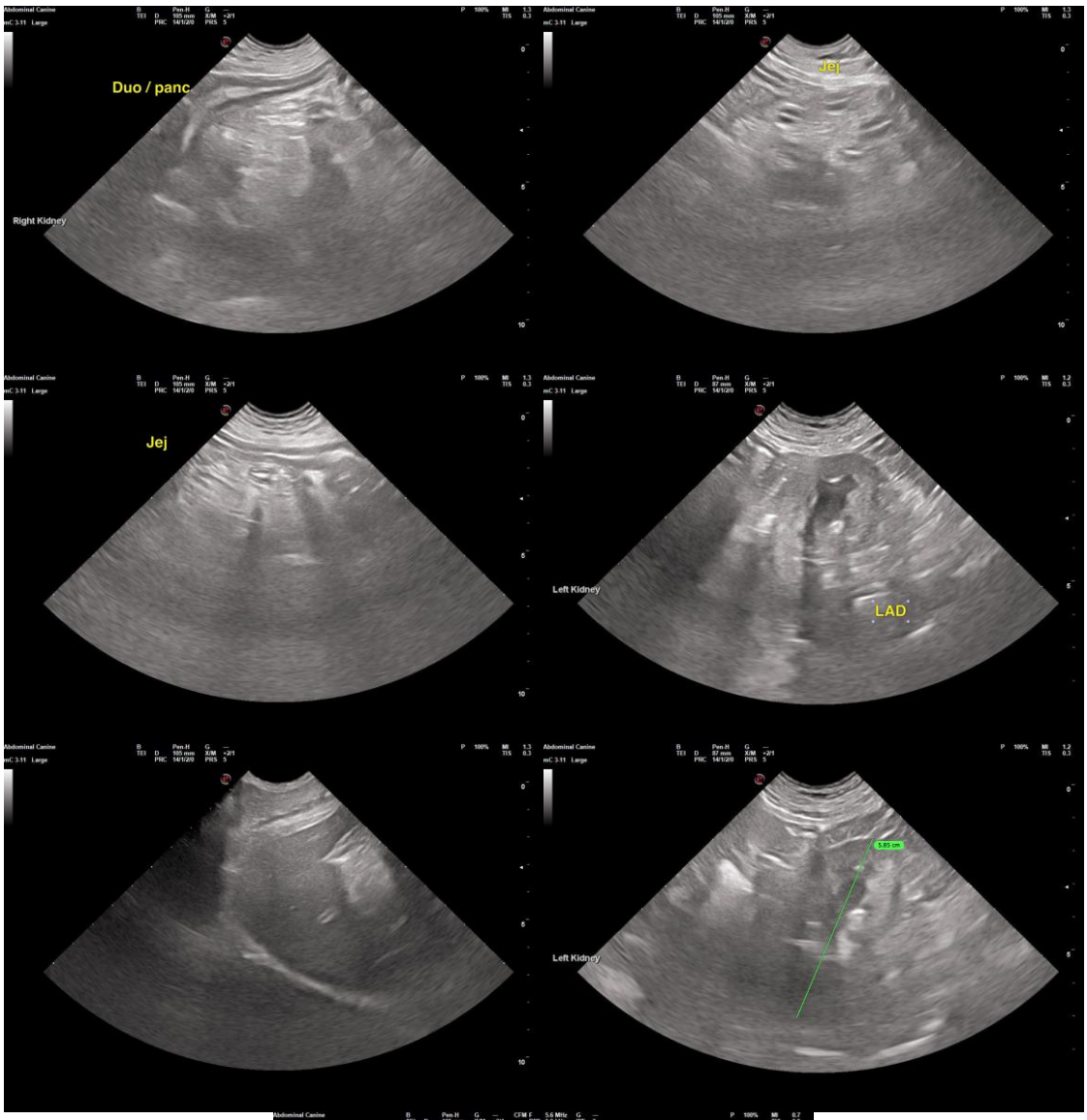

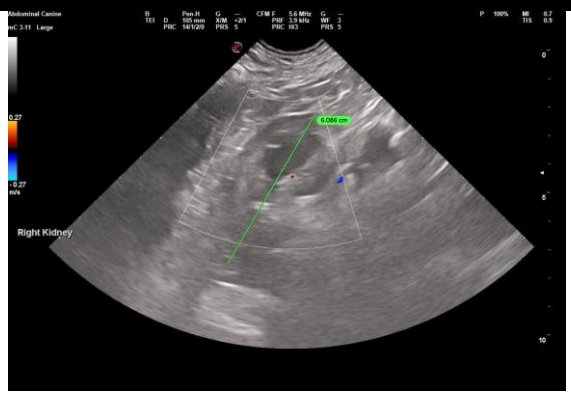

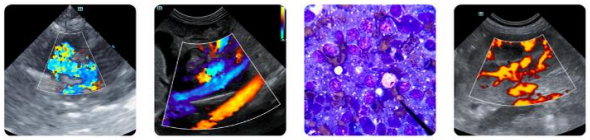

PATIENT

Coco Yamonaco

SPECIES

Canine

BREED

Boxer

SEX

Female Spayed

AGE

6Y, 9M

WEIGHT

64lbs

INTERPRETED BY

R. McKenzie Daniel, DVM, DABVP (Canine and Feline)

IMAGING PERFORMED BY

Brandi Kurzowski

HOSPITAL NAME

Corfu Veterinary Clinic

REFERRING VET

Dr. Nicole Kelver

INVOICE

75266

DATE

6-2-26

The information and recommendations provided are based on the images presented by the referring veterinarian/sonographer. No evaluation can be communicated regarding pathology that was not visible in the image/video clips provided.

Thank you for this referral. If the clinical or image interpretation does not parallel your findings or if I can be of any further assistance, please contact me.

R. McKenzie Daniel, DVM, DABVP (Canine/Feline Practice)
info@sonopath.com