



PATIENT

Frida Fulton

SPECIES

Canine

BREED

Cockapoo

SEX

Female Spay

AGE

13

WEIGHT

10 kg

INTERPRETED BY

R. McKenzie Daniel,
DVM, DABVP
(Canine and Feline)

IMAGING PERFORMED BY

Dr. Belan

HOSPITAL NAME

Calgary Holistic VC

REFERRING VET

Dr. Qi

INVOICE

15864

DATE

6/2/22

PRESENTING CLINICAL SIGNS

Severe elevation liver enzymes abdominal mass palpated
Abnormal PE/Chem/CBC/UA Results: Marked elevation of liver enzymes mild elevation renal enzymes

ULTRASONOGRAPHIC EXAMINATION OF THE ABDOMEN

Urinary System

The urinary bladder, trigone, cystourethral junction, and visible pelvic urethra exhibited normal thickness and tone. Mild asymmetrical luminal surface to micropolypoid changes were present likely associated with age related mural changes. Anechoic urine was present in the lumen with no uroliths or sediment. The ureteral papillae were normal. The ureters were not visible which is normal. No evidence of inflammatory or neoplastic changes were noted. An example of micropolypoid change in the apical wall measured 0.45 cm in diameter.

The area of the aortic trifurcation was free of pathology.

Normal size and margination were present in the kidneys. A normal 1:3 cortex / medulla ratio was maintained. The medulla and cortices were uniform in texture with some increased echogenicity and moderate loss of corticomedullary symmetry and definition expected for the age of the patient. No evidence of pelvic dilation was present. The left kidney measured 4.7 cm in length. The right kidney measured 4.9 cm in length. Pinpoint to focal areas of medullary to pelvic mineral were present.

Adrenal Glands

The bilateral adrenal glands were normal in size. Mild parenchyma heterogeneity and mild capsule asymmetry was present without suspicion for overt neoplasia. The left adrenal gland measured 0.46 cm width in the cranial pole and 0.49 cm width in the caudal pole. The right adrenal gland measured 0.63 cm width in the cranial pole and 0.54 cm width in the caudal pole.

Spleen

The spleen exhibited primarily finely textured parenchyma which was hyperechoic to the liver and renal cortical parenchyma. Mild generalized parenchyma heterogeneity was present without evidence of nodular changes. The capsule was smooth and regular without apparent expansion. The splenic vasculature at the hilus was normal in volume with no evidence of congestion or thrombosis. The parenchymal heterogeneity is likely consistent with benign changes such as extramedullary hematopoiesis or age-related remodeling with minor potential for inflammatory or neoplastic disease.

Liver/ Gallbladder

The discernable liver exhibited subjective mild generalized enlargement. The liver parenchyma was mildly nonuniform and hypoechoic to the spleen with a moderate coarse echotexture and subjective mild to benign parenchymal remodeling. In addition to the parenchymal remodeling, intermittent nondisruptive subtly hypoechoic to intermittently cystic intraparenchymal nodules were present. An example measured 1.0 cm in diameter.

The gallbladder was non distended in size with mild gallbladder debris. The cystic duct and common bile ducts were normal without evidence of dilation.

Gastrointestinal



PATIENT	The stomach presented intact wall layering with a normal wall layer ratio. Mild nonshadowing ingesta/chyme was present in the gastric lumen.
Frida Fulton	
SPECIES	The small intestine presented intact wall layering with 1:3 muscularis/mucosa ratio. The lumen of the small intestine was empty with no signs of ileus, obstruction, or foreign material.
Canine	Normal visible colon wall layers were present with apparent formed feces in lumen.
BREED	<i>Pancreas</i>
Cockapoo	The pancreas was normal in size and contour with isoechoic to heterogeneous parenchyma compared to adjacent omentum. No signs of active inflammation or neoplasia.
SEX	<i>Free Abdomen</i>
Female Spay	A large asymmetrical mixed echogenic mass was present in the subjective mid to cranial abdomen, which appeared to directly efface the caudal aspect of the liver. The mass measured approximately 9.0 cm x 6.0 cm. The mass exhibited overall similar echogenicity, compared to the discernable liver. Suspect regional gastrointestinal displacement, secondary to the mass was noted.
AGE	
13	
WEIGHT	Intermittent, mildly prominent to enlarged mesenteric lymph nodes were present. The lymph nodes were essentially isoechoic to adjacent omentum without evidence of peripheral inflammation and maintaining a normal width: length ratio (<0.5). An example of lymph node size measured 2.2 cm x 0.57 cm.
10 kg	
INTERPRETED BY	No peritoneal free fluid was present. Mild reactive mesentery was noted around the abdominal mass.
R. McKenzie Daniel, DVM, DABVP (Canine and Feline)	
IMAGING PERFORMED BY	ULTRASONOGRAPHIC FINDINGS
Dr. Belan	Primary Findings
	<ul style="list-style-type: none"> • Large nonhomogeneous mid to cranial abdominal mass • Chronic hepatopathy, exhibiting parenchymal remodeling and intermittent nonspecific parenchymal nodules • Mild gallbladder debris • Moderate chronic renal changes • Sonographically normal spleen • Intermittent benign/reactive mesenteric lymph nodes
HOSPITAL NAME	Secondary Findings
Calgary Holistic VC	<ul style="list-style-type: none"> • Micropolypoid urinary bladder changes- incidental, associated with age.
REFERRING VET	
Dr. Qi	
INVOICE	INTERPRETATION OF THE FINDINGS & FURTHER RECOMMENDATIONS
15864	Although not definitive, with sampling required for further assessment, the mid to cranial abdominal mass is suspected to be hepatic in origin, given its location and similar echogenicity to the discernable liver and concurrent hepatic enzyme elevations. The mass did not appear to derive from the spleen, kidneys or adrenal glands with less likely potential for omental or lymphatic origin. Assuming normal clotting status, ultrasound guided FNA of the abdominal mass could be considered for screening cytology.
DATE	
6/2/22	



PATIENT

Frida Fulton

The concurrent subtle variably echogenic to cystic hepatic nodules may indicate areas of nodular/regenerative hyperplasia, lipogranulomas, hematopoiesis, while the possibility of concurrent primary versus metastatic intrahepatic nodules cannot be excluded.

SPECIES

Canine

Abdominal CT, if possible, could be considered for further clarification, as well as assessment of surgical resectability of the mass. Three-view chest radiographs are suggested, if not done. Further renal staging to include urine C/S and protein: creatinine ratio on sterile urine sample may be considered.

BREED

Cockapoo

SEX

Female Spay

AGE

13

WEIGHT

10 kg

INTERPRETED BY

R. McKenzie Daniel,
DVM, DABVP
(Canine and Feline)

IMAGING PERFORMED BY

Dr. Belan

HOSPITAL NAME

Calgary Holistic VC

REFERRING VET

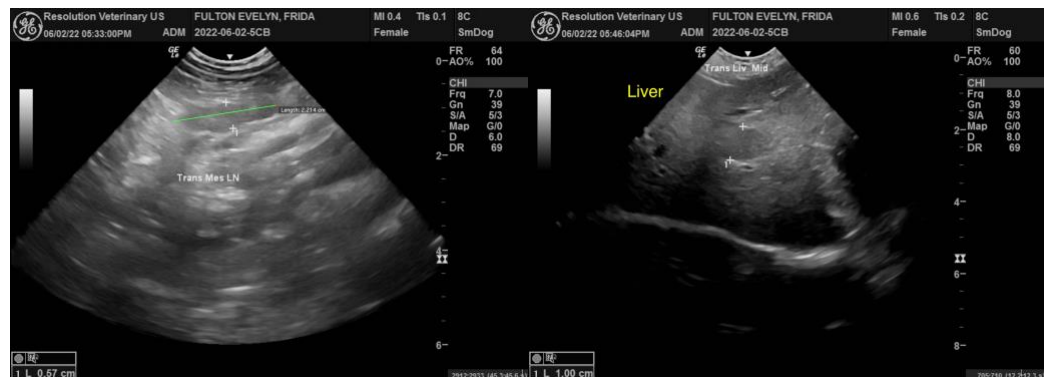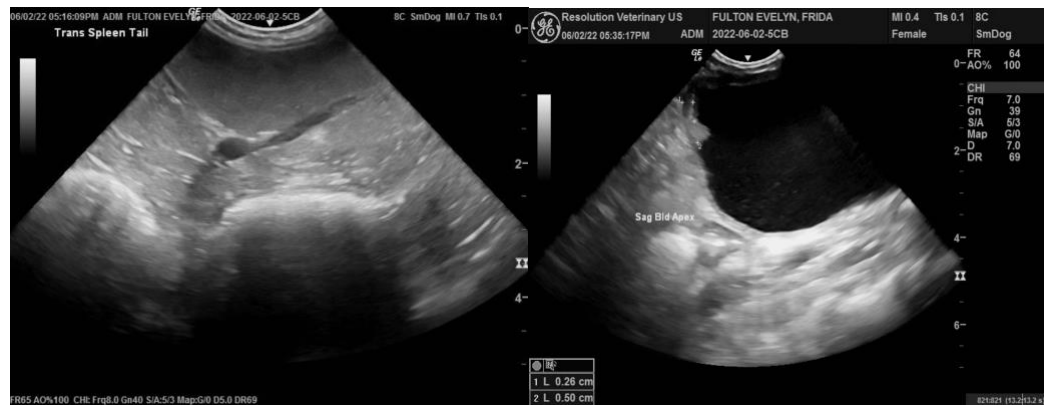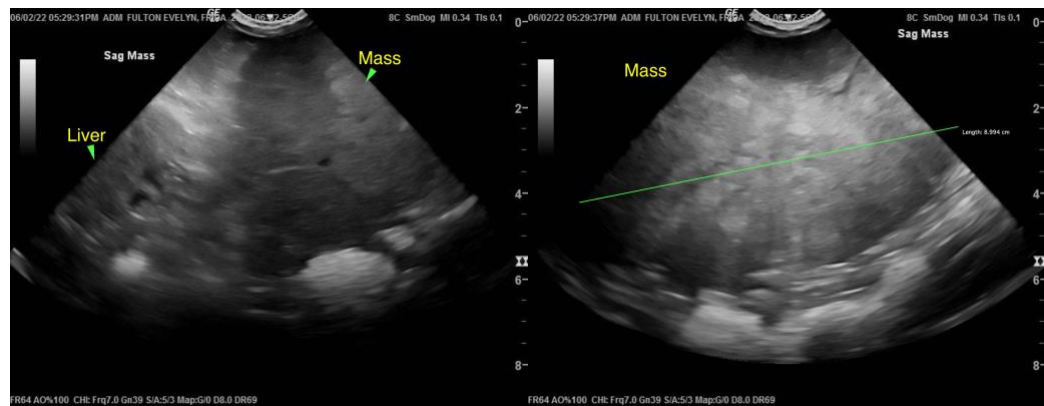
Dr. Qi

INVOICE

15864

DATE

6/2/22





PATIENT

Frida Fulton

SPECIES

Canine

BREED

Cockapoo

SEX

Female Spay

AGE

13

WEIGHT

10 kg

INTERPRETED BY

R. McKenzie Daniel,
DVM, DABVP
(Canine and Feline)

IMAGING PERFORMED BY

Dr. Belan

HOSPITAL NAME

Calgary Holistic VC

REFERRING VET

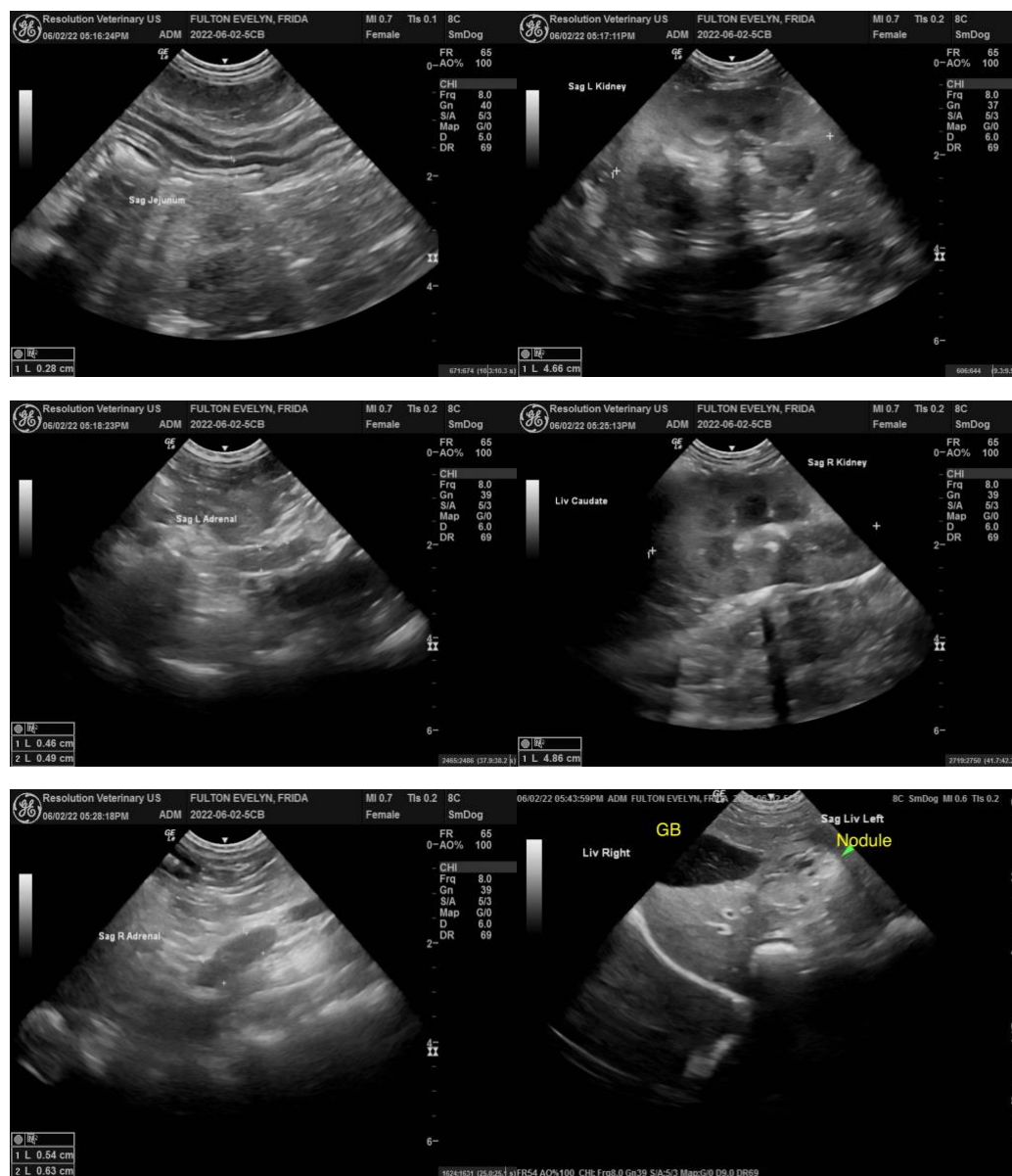
Dr. Qi

INVOICE

15864

DATE

6/2/22



The information and recommendations provided are based on the images presented by the referring veterinarian/sonographer. No evaluation can be communicated regarding pathology that was not visible in the image/video clips provided.

Thank you for this referral. If the clinical or image interpretation does not parallel your findings or if I can be of any further assistance please contact me.

R. McKenzie Daniel, DVM, DABVP (Canine / Feline Practice)
info@SonoPath.com