



PATIENT

Hugo Corson

SPECIES

Canine

BREED

Dachshund

SEX

Neutered Male

AGE

13 Years

WEIGHT

Not Provided

PRESENTING CLINICAL SIGNS

Pre dental echo HM 3/6. Enalapril 5mg SID

ULTRASONOGRAPHIC EXAMINATION OF THE HEART

CANINE CARDIAC PARAMETERS	MR VMAX (m/s)	TR VMAX (m/s)	LA/AO (M-Mode)	LA/AO (Heart Base; Swe)	FS (%)	EF (%)	EPSS (cm)
NORMAL PARAMETER	4.5-5.5	<2.7	1.3	Up to 1.6	28-40	40-100	<0.6
PATIENT	5.4	--	NM	1.36	42	75	0.3
CANINE CARDIAC PARAMETERS	HR (BPM)	AV VMAX (m/s)	PV MAX (m/s)	BODY WEIGHT	LAD LA MAX 4 Chamber	LVIDd Avg; 2D and m-mode short axis (cm)	LVIDs Avg; 2D and m-mode short axis (cm)
NORMAL PARAMETER	50-100	0.7-1.7	0.7-1.6				
PATIENT	112	1.3	1.0	NM	3.2	3.0	--

INTERPRETED BY

R. McKenzie Daniel, DVM, DABVP (Canine / Feline Practice)

IMAGING PERFORMED BY

Kerri Becker

HOSPITAL NAME

All Creatures Great and Small Denville

REFERRING VET

Dr. Silas Ashmore

INVOICE

16772

DATE

06/18/26

Cardiac Presentation

The echocardiogram in this patient demonstrated normal **left atrial** size based on 2 LA measurement methods. The cranial and caudal **mitral valve** leaflets presented thickening consistent with endocardiosis. Mild valvular prolapse. Doppler indicated measurable moderate eccentric MR. The **left ventricle** presented thicknesses with linear contour and was not dilated nor restricted. The **myocardium** presented normal echogenicity without subjective evidence of significant fibrotic or ischemic disease. **Contractility** of the ventricular walls was adequate and in normal range for this patient evidenced by the fractional shortening measurement and subjective evaluation of the different regions of the myocardium. The **left ventricular outflow** tract demonstrated normal laminar flow and subjective structural integrity. The **right atrium** and auricle revealed normal size, structure and content. No evidence of masses was noted or chamber overload. **Tricuspid** valvular assessment demonstrated adequate linear morphology. The **right ventricle** was of normal size (1/3 diameter of LV), chordae structure, myocardial echogenicity and thickness. **Pulmonic** tract assessment revealed normal valve structure, laminar flow, and diameter (approx.1:1 pa/ao ratio). No visible **pericardial** or free pleura fluid was noted. No echographically detectable evidence of cardiac / pericardial tumors was visible.

ULTRASONOGRAPHIC FINDINGS

- Chronic mitral valve disease (ACVIM stage B1).

INTERPRETATION OF THE FINDINGS & FURTHER RECOMMENDATIONS

The cause of the murmur is chronic degenerative valvular changes with secondary eccentric mitral valve insufficiency. The lack of left atrial enlargement implies that the risk of complication secondary



PATIENT

Hugo Corson

SPECIES

Canine

BREED

Dachshund

SEX

Neutered Male

AGE

13 Years

WEIGHT

Not Provided

INTERPRETED BY

R. McKenzie Daniel,
DVM, DABVP (Canine
/ Feline Practice)

IMAGING PERFORMED BY

Kerri Becker

HOSPITAL NAME

All Creatures Great
and Small Denville

REFERRING VET

Dr. Silas Ashmore

INVOICE

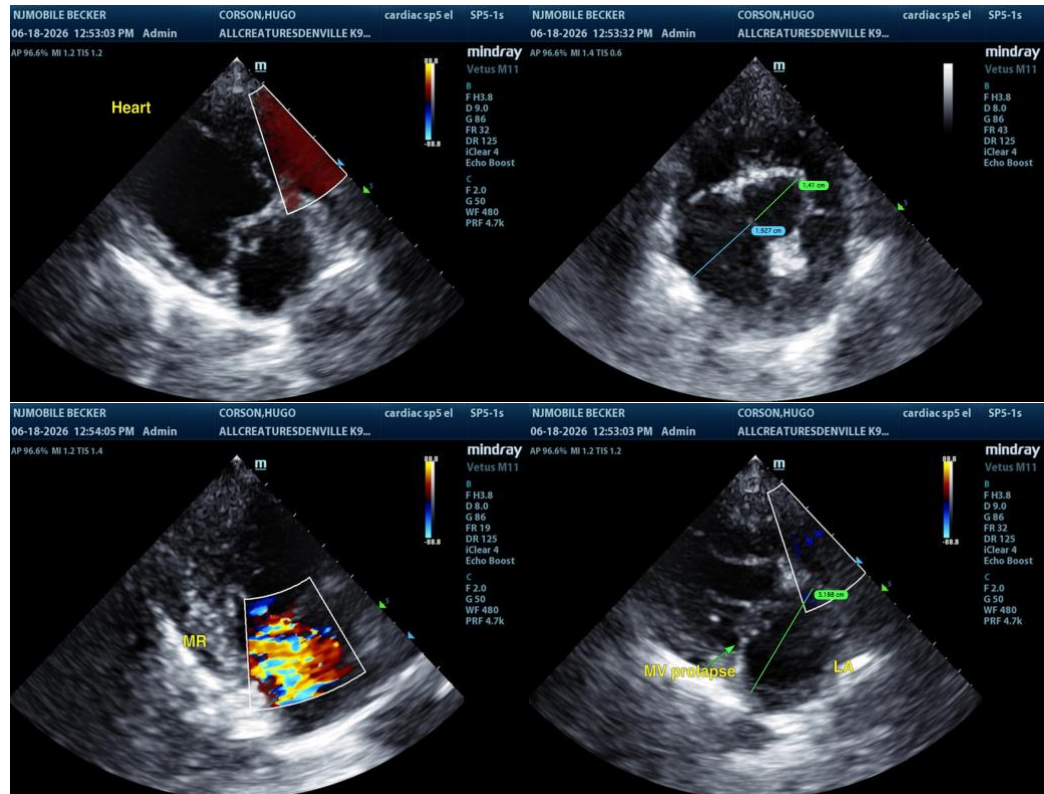
16772

DATE

06/18/26

to mitral valve insufficiency is low at this time and, without current clinical signs, indicates that medical therapy is not required. Prognosis is considered variable and sonographic monitoring is recommended. Recheck echo cardiogram is suggested in 6 months, sooner if clinical signs arise.

Anesthetic risk is considered mild. The following protocol is recommended with clinical monitoring and appropriate IV fluids. Suggested anesthetic protocol may include opioid or Benzodiazepine pre-med, induction with Propofol or Alfaxalone, and appropriate gas anesthesia with avoidance of alpha 2 agonists.



The information and recommendations provided are based on the images presented by the referring veterinarian/sonographer. No evaluation can be communicated regarding pathology that was not visible in the image/video clips provided.

Thank you for this referral. If the clinical or image interpretation does not parallel your findings or if I can be of any further assistance, please contact me.

R. McKenzie Daniel, DVM, DABVP (Canine / Feline Practice)

info@SonoPath.com