



PATIENT

Minnie Dinh

SPECIES

Canine

BREED

Terrier X

SEX

FS

AGE

14Y

WEIGHT

4.2kg

INTERPRETED BY

R. McKenzie Daniel,
DVM, DABVP
(Canine and Feline)

IMAGING PERFORMED BY

Kelly Reschny

HOSPITAL NAME

Vet for Life AH

REFERRING VET

Bajaj

INVOICE

75546

DATE

6-17-26

PRESENTING CLINICAL SIGNS

Grade 5/6 heart murmur. Increased bronchovesicular sounds bilaterally at caudodorsal lungs field.
B.P- WNL
Current Medications
Furosemide 10.5 mg IV in clinic at 1:30 pm . Echocardiography was done before the furosemide injection.

ULTRASONOGRAPHIC EXAMINATION OF THE HEART

CANINE CARDIAC PARAMETERS	MR VMAX (m/s)	TR VMAX (m/s)	LA/AO (M-mode)	LA/AO (Heart Base; Swe)	FS (%)	EF (%)	EPSS (cm)
NORMAL PARAMETER	4.5-5.5	<2.7	1.3	Up to 1.6	28-40	40-100	<0.6
PATIENT			--	1.9	46	78	0.3
CANINE CARDIAC PARAMETERS	HR (BPM)	AV VMAX (m/s)	PV MAX (m/s)	BODY WEIGHT (kg)	LAD LA MAX 4 Chamber	LVIDd Avg; 2D and m-mode short axis (cm)	LVIDs Avg; 2D and m-mode short axis (cm)
NORMAL PARAMETER	50-100	0.7-1.7	0.7-1.6				
PATIENT	157	1.0	0.9	4.2	2.9	3.2	

Cardiac Presentation

The echocardiogram in this patient demonstrated moderate increased **left atrial** dimension based on 2 different LA measurement methods. The cranial and caudal **mitral** valve leaflets presented thickening consistent with endocardiosis with septal leaflet prolapse. Definitive chordae tendineae rupture was not obvious. Doppler indicated moderate to significant eccentric MR. MR velocity 5.0 m/s, possibly mildly underestimated. The **left ventricle** presented thicknesses with linear contour and moderate increased LV dimension. The **myocardium** presented normal echogenicity without subjective evidence of significant fibrotic or ischemic disease. **Contractility** of the ventricular walls was adequate and in normal range for this patient evidenced by the fractional shortening measurement and subjective evaluation of the different regions of the myocardium. The **left ventricular outflow** tract demonstrated normal laminar flow and subjective structural integrity. The **right atrium** and auricle revealed normal size, structure and content. No evidence of masses was noted or chamber overload. **Tricuspid** valvular assessment demonstrated adequate linear morphology. The **right ventricle** was of normal size (1/3 diameter of LV), chordae structure, myocardial echogenicity and thickness. **Pulmonic** tract assessment revealed normal valve structure, laminar flow, and diameter (approx.1:1 pa/ao ratio). No visible **pericardial** or free pleura fluid was noted. No echographically detectable evidence of cardiac / pericardial tumors was visible. No evidence of arrhythmia.

ULTRASONOGRAPHIC FINDINGS

- Chronic mitral valve disease with valve prolapse (ACVIM B2-possible emerging C)



PATIENT

Minnie Dinh

SPECIES

Canine

BREED

Terrier X

SEX

FS

AGE

14Y

WEIGHT

4.2kg

INTERPRETED BY

R. McKenzie Daniel,
 DVM, DABVP
 (Canine and Feline)

IMAGING PERFORMED BY

Kelly Reschny

HOSPITAL NAME

Vet for Life AH

REFERRING VET

Bajaj

INVOICE

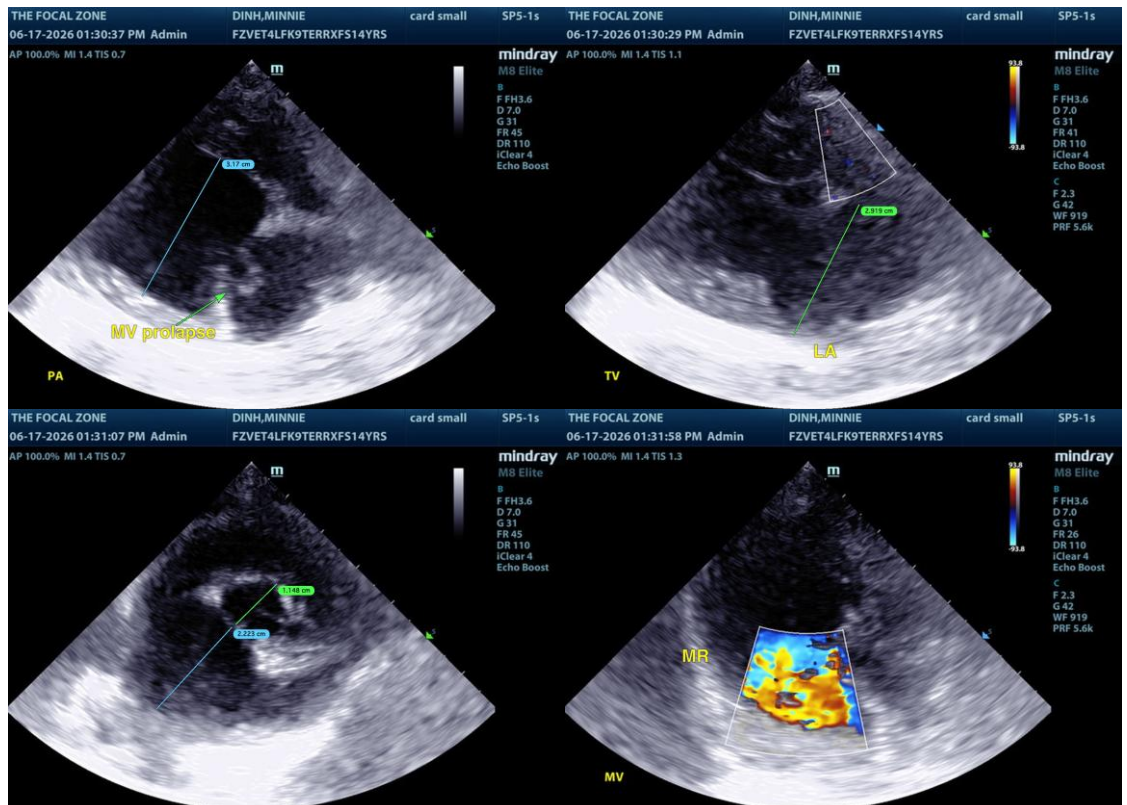
75546

DATE

6-17-26

INTERPRETATION OF THE FINDINGS & FURTHER RECOMMENDATIONS

The degree of LA/LV enlargement with at least moderate hemodynamic effect of the MR indicates that the current and future risk of complication is at least moderately elevated. Clinical signs owing to emerging left sided congestion not excluded. No evidence of additional issues such as clinical pulmonary hypertension. Pimobendan 0.3mg/kg PO BID and lowest effective dose Lasix trial 1-2mg/kg PO BID with clinical and radiographic monitoring if evidence of pulmonary edema is recommended. ACEI 0.5mg/kg SID/BID recommended if systemic BP >130. Mild salt restriction and omega fatty acid supplementation may prove beneficial. Concurrent potential lower airway disease not excluded with as needed respiratory support recommended. Echocardiographic monitoring required for further assessment and prognosis. Recheck echo suggested in 4-6 weeks, sooner if clinically indicated. Elective anesthesia is not advised pending further assessment.



The information and recommendations provided are based on the images presented by the referring veterinarian/sonographer. No evaluation can be communicated regarding pathology that was not visible in the image/video clips provided.

Thank you for this referral. If the clinical or image interpretation does not parallel your findings or if I can be of any further assistance, please contact me.

R. McKenzie Daniel, DVM, DABVP (Canine/Feline Practice)
info@sonopath.com