



PATIENT

Lexus Cullember

SPECIES

Canine

BREED

Shih Tzu

SEX

Female spayed

AGE

14Y

WEIGHT

14.4lbs

INTERPRETED BY

R. McKenzie Daniel,
DVM, DABVP
(Canine and Feline)

IMAGING PERFORMED BY

Dr. Wasserman

HOSPITAL NAME

Highlands Animal
Hospital

REFERRING VET

Dr. Frankenberger

INVOICE

75553

DATE

6-17-26

PRESENTING CLINICAL SIGNS

Pre-anesthetic bloodwork for COHAT revealed elevated ALP at 1036. No history of PU/PD/Panting per referring vet/owners. Cystocentesis performed at END of sonogram. Patient not sedated. Moderate abdominal tension cranial right abdomen. No current medications reported. Purpose of sonogram: evaluate for causes of elevated ALP.

Abnormal PE/Chem/CBC/UA Results: Preliminary URSG 1.052. ALP 1036. No other abnormalities on CBC/Chem/Lytes. Full urinalysis pending.

ULTRASONOGRAPHIC EXAMINATION OF THE ABDOMEN

Urinary System

The urinary bladder, trigone, cystourethral junction, and visible pelvic urethra to a depth of 3.0 cm exhibited normal thickness and tone. Anechoic urine was present in the lumen with no uroliths or sediment. The ureteral papillae were normal. The ureters were not visible, which is normal. No evidence of inflammatory or neoplastic changes was noted.

No evidence of pathology in the area of the aortic trifurcation.

Normal size and margination were present in the kidneys. A normal 1:3 cortex / medulla ratio was maintained. The medulla and cortices were uniform in texture with some increased echogenicity and mild loss of corticomedullary symmetry and definition expected for the age of the patient. No evidence of pelvic dilation was present. The left kidney measured 3.7 cm in length. The right kidney measured 4.1 cm in length.

Adrenal Glands

The left adrenal gland presented a mildly enlarged caudal pole with symmetrical contour and homogeneous parenchyma. The left adrenal gland measured 0.51 cm width at the cranial pole and 0.76 cm width at the caudal pole.

The right adrenal gland was uniform in size and contour with a uniformly hypoechoic parenchyma. The right adrenal gland measured 0.79 cm width at the cranial pole and 0.46 cm width at the caudal pole.

Spleen

Subtle areas of nonhomogeneous splenic parenchyma were present and likely consistent with differentiation between red/white pulp. No mass or nodules were present. The capsule was smooth and regular without apparent expansion. The splenic vasculature at the hilus was normal in volume with no evidence of congestion or thrombosis. Acute to chronic inflammatory, neoplastic, or benign parenchyma changes were not noted.

Liver/ Gallbladder

The liver presented mildly enlarged in size. The parenchyma of the liver was subjectively normal in echogenicity compared to the spleen and renal cortices. The liver parenchyma was uniform with a mildly coarse echotexture. The capsule of the liver was symmetrically rounded to mildly swollen in margination. The hepatic and portal vasculature were normal in appearance without signs of congestion.

The gallbladder was non-distended in size with thin walls and mild nonorganized gallbladder debris. The cystic and common bile ducts were normal.



PATIENT

Lexus Cullember

SPECIES

Canine

BREED

Shih Tzu

SEX

Female spayed

AGE

14Y

WEIGHT

14.4lbs

INTERPRETED BY

R. McKenzie Daniel,
DVM, DABVP
(Canine and Feline)

IMAGING PERFORMED BY

Dr. Wasserman

HOSPITAL NAME

Highlands Animal
Hospital

REFERRING VET

Dr. Frankenberger

INVOICE

75553

DATE

6-17-26

Gastrointestinal

The stomach presented intact wall layering with a normal wall layer ratio. The lumen of the stomach was empty without evidence of retained ingesta, fluid, or foreign material.

The small intestine presented intact wall layering with 1:3 muscularis/mucosa ratio. The lumen of the small intestine was empty with no signs of ileus, obstruction, or foreign material.

Normal visible colon wall layers were present with formed feces in lumen.

Pancreas

The parenchyma of the left limb, body and right limb of the pancreas presented isoechoic to the adjacent omental fat. A normal curvilinear capsule contour of the pancreas was present. The visible pancreatic duct was normal. No signs of active inflammation or neoplastic disease were evident.

Free Abdomen

No overt lymphadenopathy or peritoneal effusion was present.

ULTRASONOGRAPHIC FINDINGS

- Hepatopathy – subjectively benign.
- Mild gallbladder debris (nonmucocele).
- Age related renal changes.
- Mild caudal left adrenomegaly.

INTERPRETATION OF THE FINDINGS & FURTHER RECOMMENDATIONS

Sonographically, the liver suggests benign criteria with vacuolar or cholestatic hepatopathy favored in conjunction with ALP elevation and presence of gallbladder debris. Inflammatory hepatopathy is thought less likely without sonographic evidence of hepatic neoplastic criteria. Given no reported clinical signs in this patient, the mild caudal left adrenomegaly is nonspecific with potential for patient variant. Adrenal workup with LDDST warranted if clinical signs consistent with Cushing's syndrome are nonreported or arise. Correlation with urinalysis recommended. If patient is nonclinical, hepatosupportive medications including Denamarin and Ursodiol, if tolerated, with monitoring would be reasonable. Recheck sonogram if clinical signs consistent with adrenal disease or hepatopathy arise or evidence of progressive hepatopathy. Screening hepatic FNA cytology could be considered primarily to assess for nonobvious inflammation.



PATIENT

Lexus Cullember

SPECIES

Canine

BREED

Shih Tzu

SEX

Female spayed

AGE

14Y

WEIGHT

14.4lbs

INTERPRETED BY

R. McKenzie Daniel,
DVM, DABVP
(Canine and Feline)

IMAGING PERFORMED BY

Dr. Wasserman

HOSPITAL NAME

Highlands Animal
Hospital

REFERRING VET

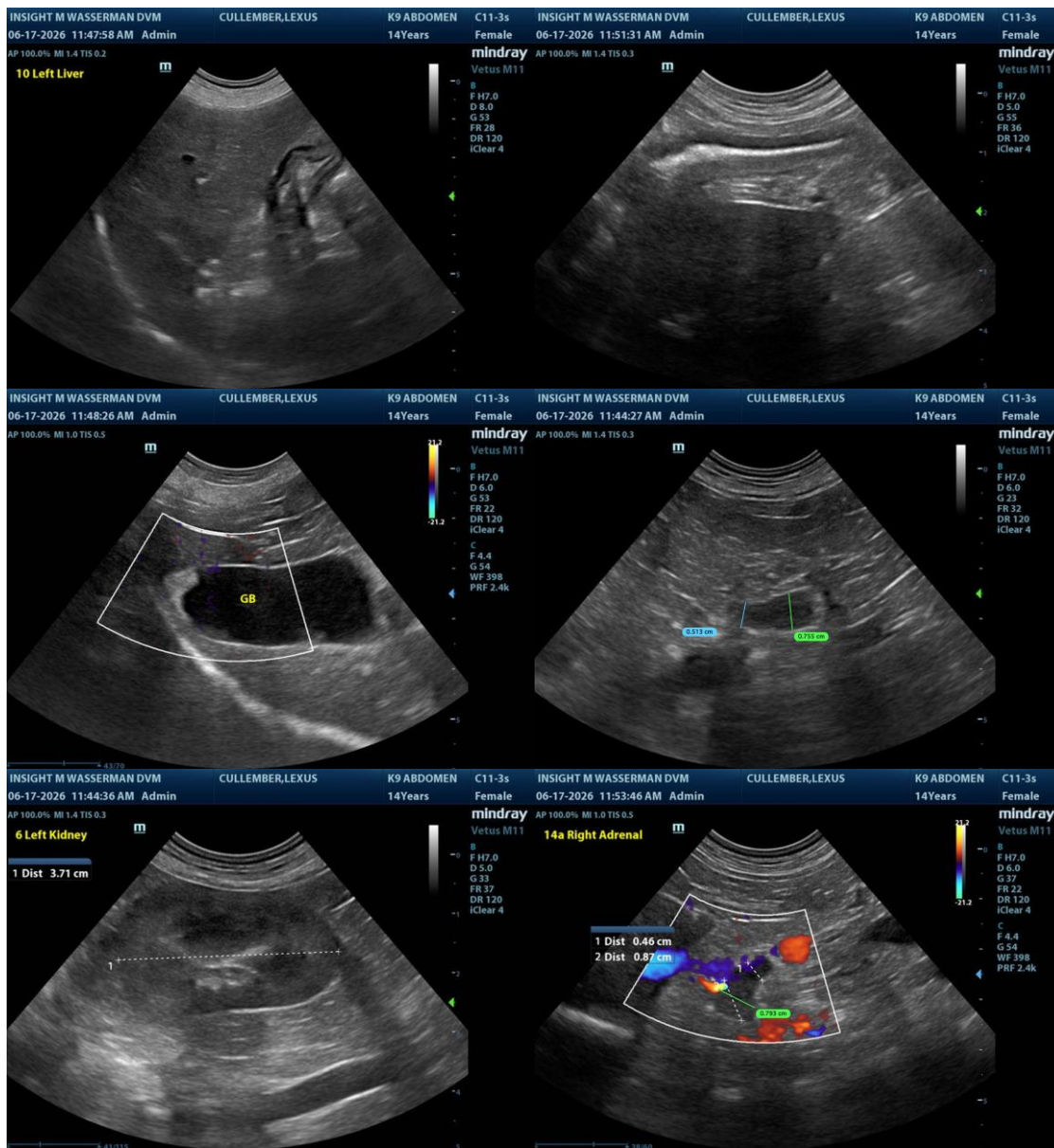
Dr. Frankenberger

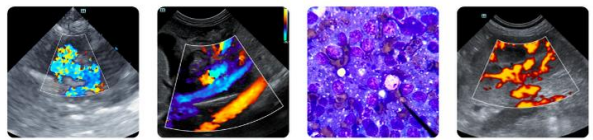
INVOICE

75553

DATE

6-17-26





PATIENT

Lexus CulleMBER

SPECIES

Canine

BREED

Shih Tzu

SEX

Female spayed

AGE

14Y

WEIGHT

14.4lbs

INTERPRETED BY

R. McKenzie Daniel,
DVM, DABVP
(Canine and Feline)

IMAGING PERFORMED BY

Dr. Wasserman

HOSPITAL NAME

Highlands Animal
Hospital

REFERRING VET

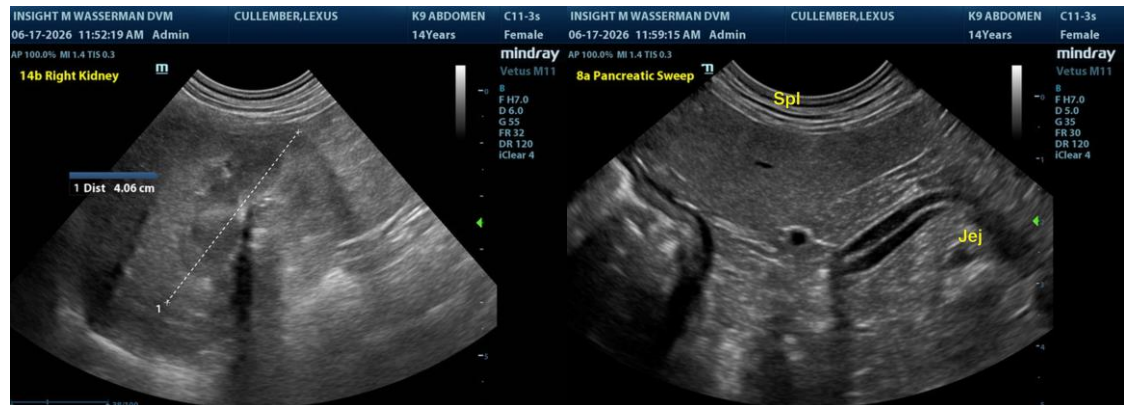Dr. Frankenberger

INVOICE

75553

DATE

6-17-26



The information and recommendations provided are based on the images presented by the referring veterinarian/sonographer. No evaluation can be communicated regarding pathology that was not visible in the image/video clips provided.

Thank you for this referral. If the clinical or image interpretation does not parallel your findings or if I can be of any further assistance, please contact me.

R. McKenzie Daniel, DVM, DABVP (Canine/Feline Practice)
info@sonopath.com