



**PATIENT PRESENTING CLINICAL SIGNS**

**The Captain Mullee**  
History: The Captain has been urinating inappropriately, the O feels with stress. He presented today with urinary obstruction. After receiving pain meds and mild sedation, he was able to pass a plug on his own, as well as a small white stone. Bladder was flushed. This study is conducted after the flushing of the bladder. Urine is yellow in color.

**SPECIES**

**Feline**  
Abnormal PE/Chem/CBC/UA Results: Pending.

**BREED**

**DSH**  
*Urinary System*

**SEX**

**MN**

**AGE**

**2 years**  
Normal size and margination were present in the kidneys. A normal 1:3 cortex / medulla ratio and normal corticomedullary definition were maintained. The echogenicity of the cortex was similar to or slightly less than normal liver parenchyma while the medulla echogenicity was hypoechoic to the cortex with no evidence of pelvic dilation. The left kidney measured 4.3 cm in length. The right kidney measured 4.3 cm in length.

**WEIGHT**

**15 lb**  
The area of the aortic trifurcation was free of pathology.

**INTERPRETED BY**

**R. McKenzie Daniel, DVM, DABVP**  
*Adrenal Glands*  
The area of the left and right adrenal glands were free of pathology.

(Canine and Feline)

**IMAGING PERFORMED BY**

**Dr. Valasco**  
*Spleen*

The spleen exhibited a finely textured and homogenous parenchyma which was hyperechoic to the liver and renal cortical parenchyma. The capsule was smooth and regular without apparent expansion. The splenic vasculature at the hilus was normal in volume with no evidence of congestion or thrombosis. Acute to chronic inflammatory, neoplastic, or benign parenchyma changes were not noted.

**HOSPITAL NAME**

**Bethany Family Pet Clinic**  
*Liver*

**REFERRING VET**

**Dr. Velasco**  
The liver was subjectively normal in size, structure, and contour. The liver parenchyma was uniform and hypoechoic to the spleen with a mild coarse echotexture. The hepatic and portal vasculature were normal in appearance without signs of congestion. The gallbladder was non-distended in size with thin walls and primarily anechoic luminal content. The cystic and common bile ducts were normal.

**INVOICE**

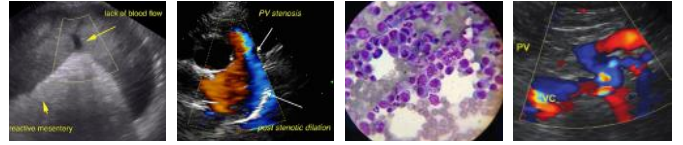
**10854ag**  
*Gastrointestinal*

The stomach presented intact wall layering with a normal wall layer ratio. The lumen of the stomach was empty with no signs of ileus, obstruction or foreign material.

**DATE**

**06/17/2022**  
The small intestine presented intact wall layering with 1:3 muscularis/mucosa ratio. The lumen of the small intestine was empty with no signs of ileus, obstruction or foreign material.

Normal visible colon wall layers were present with apparent formed feces in lumen.



**PATIENT** *Pancreas*

The Captain Mullee

The parenchyma of the left limb, body and right limb of the pancreas presented isoechoic to the adjacent omental fat. A normal curvilinear capsule contour of the pancreas was present. The visible pancreatic duct was normal. No signs of active inflammation or neoplastic disease was evident.

**SPECIES**

Feline

*Free Abdomen*

No overt lymphadenopathy or peritoneal effusion was present.

**BREED**

DSH

**ULTRASONOGRAPHIC FINDINGS**

**SEX**

MN

- Minor cystitis pattern with mild nondependent urinary bladder and nonobstructive proximal urethral mineralized sand
- Sonographically unremarkable bilateral kidneys

**AGE**

2 years

**INTERPRETATION OF THE FINDINGS & FURTHER RECOMMENDATIONS**

A urine C/S on sterile urine sample is suggested to rule out underlying UTI. If UTI is ruled out, the UB presentation is likely consistent with idiopathic or minor interstitial cystitis. Medical therapy for idiopathic cystitis including canned dissolution diet therapy would be reasonable. No other evidence of intra-abdominal visceral pathology on this scan.

**WEIGHT**

15 lb

**INTERPRETED BY**

R. McKenzie Daniel,  
DVM, DABVP  
(Canine and Feline)

**IMAGING PERFORMED BY**  
Dr. Valasco

**HOSPITAL NAME**

Bethany Family Pet  
Clinic

**REFERRING VET**

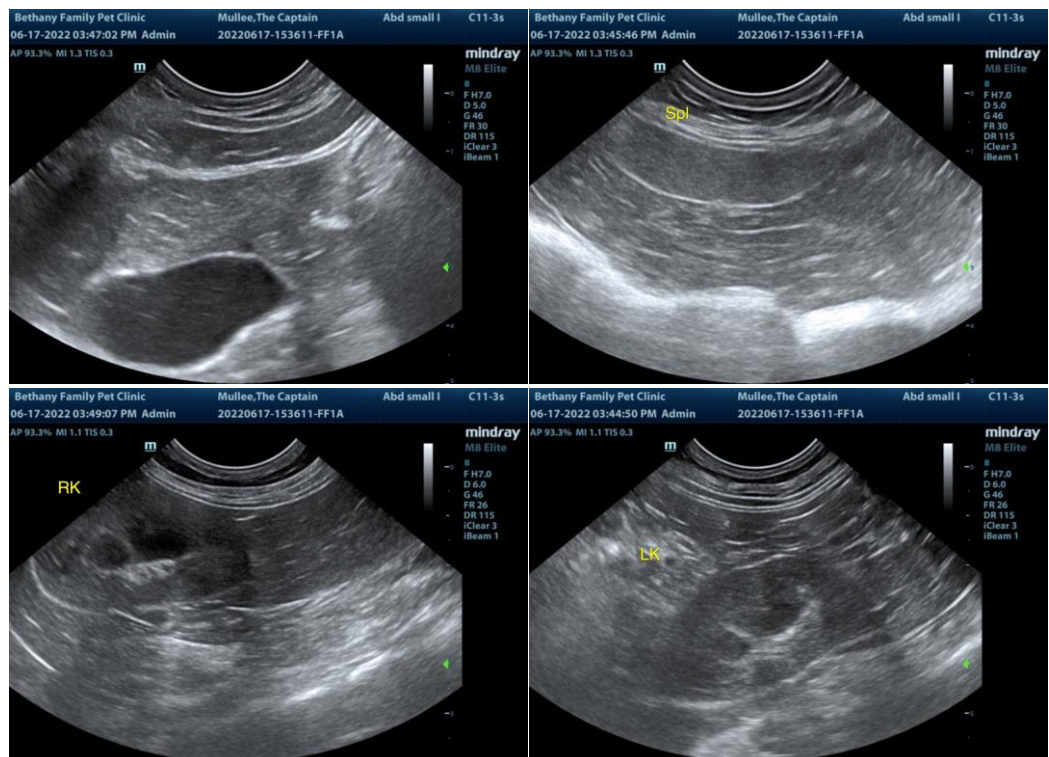
Dr. Velasco

**INVOICE**

10854ag

**DATE**

06/17/2022





**PATIENT**

The Captain Mullee

**SPECIES**

Feline

**BREED**

DSH

**SEX**

MN

**AGE**

2 years

**WEIGHT**

15 lb

**INTERPRETED BY**

R. McKenzie Daniel,  
DVM, DABVP  
(Canine and Feline)

**IMAGING PERFORMED BY**

Dr. Valasco

**HOSPITAL NAME**

Bethany Family Pet  
Clinic

**REFERRING VET**

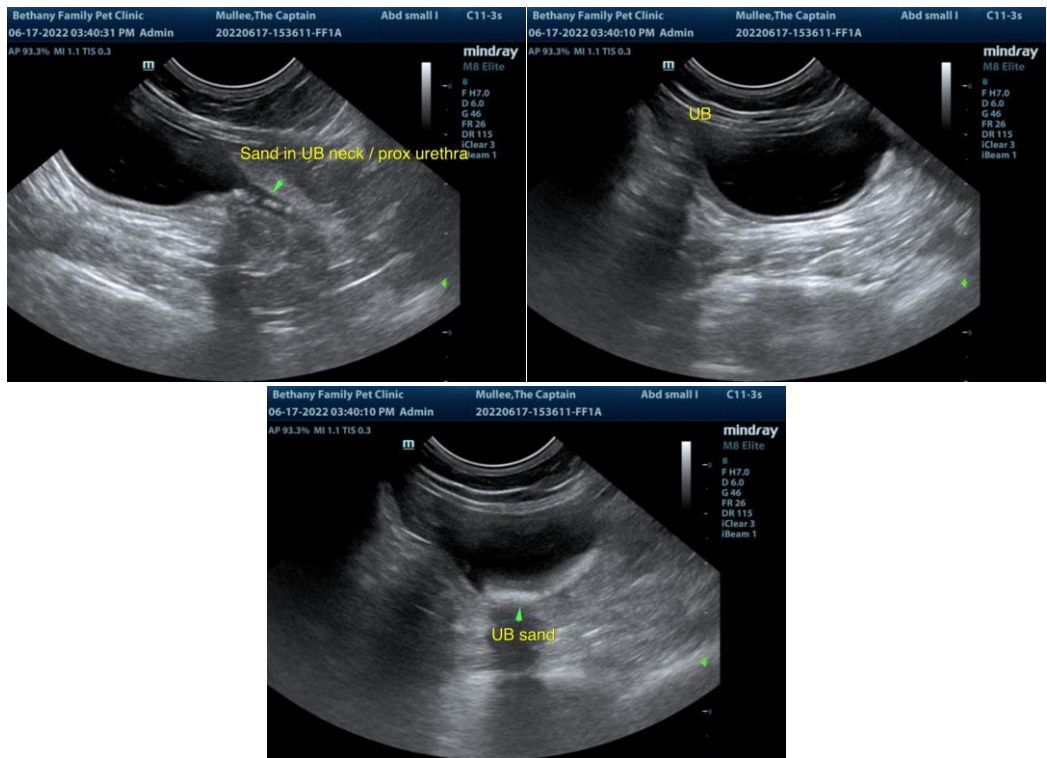
Dr. Velasco

**INVOICE**

10854ag

**DATE**

06/17/2022



The information and recommendations provided are based on the images presented by the referring veterinarian/sonographer. No evaluation can be communicated regarding pathology that was not visible in the image/video clips provided.

Thank you for this referral. If the clinical or image interpretation does not parallel your findings or if I can be of any further assistance please contact me.

R. McKenzie Daniel, DVM, DABVP (Canine / Feline Practice)

info@SonoPath.com