



PATIENT PRESENTING CLINICAL SIGNS

Athena Kazarian History: Persistent ALKP elevation for the past year, weight loss and lethargy. On Proin and apoquel
Abnormal PE/Chem/CBC/UA Results: ALKP 345 on 6/14

SPECIES ULTRASONOGRAPHIC EXAMINATION OF THE ABDOMEN

Canine

Urinary System

BREED

Rottweiler

The urinary bladder, trigone, cystourethral junction, and visible pelvic urethra to a depth of 2 cm exhibited normal thickness and tone. Intermittent micropolyploid luminal surface changes were present. Anechoic urine was present in the lumen with no uroliths or sediment. The ureteral papillae were normal. The ureters were not visible which is normal. No evidence of inflammatory or neoplastic changes were noted.

SEX

FS

Normal size and margination were present in the kidneys. A normal 1:3 cortex / medulla ratio and normal corticomedullary definition were maintained. The echogenicity of the cortex was similar to or slightly less than normal liver parenchyma while the medulla echogenicity was hypoechoic to the cortex with no evidence of pelvic dilation. The left kidney measured 7.0 cm in length. The right kidney measured 6.9 cm in length.

AGE

8 years

The area of the aortic trifurcation was free of pathology.

WEIGHT

93.2 lb

No overt pathology in the area of the uterine remnant.

Adrenal Glands

The left adrenal gland was uniform in size and contour with a uniformly hypoechoic parenchyma. The left adrenal gland measured 0.57 cm width at the caudal pole and 2.8 cm length. The right adrenal gland was uniform in size and contour with a uniformly hypoechoic parenchyma. The right adrenal gland measured 0.47 cm width at the caudal pole and 2.6 cm length.

INTERPRETED BY

R. McKenzie Daniel,
DVM, DABVP
(Canine and Feline)

Spleen

The spleen exhibited generalized enlargement primarily owing to a nonhomogeneous mixed echogenic nodular mass in the cranial spleen measuring approximately 6 cm in diameter. A concurrent mildly expansive nonhomogeneous mass in the mid spleen measuring 3.6 cm in diameter was present. The spleen was folded upon itself. No evidence of peri splenic free fluid. The peri splenic omentum exhibited normal echogenicity.

IMAGING

PERFORMED BY

Diane McFadden

HOSPITAL NAME

Mount Olive Veterinary
Hospital

Liver

The liver exhibited potential for mild enlargement. The parenchyma of the liver was subjectively normal in echogenicity compared to the spleen and renal cortices. The liver parenchyma was uniform with a mildly coarse echotexture. The capsule of the liver was symmetrically rounded to mildly swollen in margination. The hepatic and portal vasculature were normal in appearance without signs of congestion. The gallbladder was non-distended in size with primarily anechoic luminal content. The cystic and common bile ducts were normal.

REFERRING VET

Dr. Jones

INVOICE

10833ag

Gastrointestinal

The stomach presented intact wall layering with a normal wall layer ratio. The lumen of the stomach was empty with no signs of ileus, obstruction or foreign material. The gastric body wall measured 0.40 cm in width.

DATE

06/17/2022



PATIENT

Athena Kazarian

The small intestine presented intact yet prominent to mildly thickened segmental to generalized wall layering owing to propensity for mildly prominent muscularis layer. The lumen of the small intestine was empty with no signs of ileus, obstruction or foreign material. The small intestinal wall measured 0.64 cm in width.

SPECIES

Canine

Normal visible colon wall layers were present with apparent formed feces in lumen.

Pancreas

BREED

Rottweiler

The parenchyma of the left limb, body and right limb of the pancreas presented isoechoic to the adjacent omental fat. A normal curvilinear capsule contour of the pancreas was present. The visible pancreatic duct was normal. No signs of active inflammation or neoplastic disease was evident.

Free Abdomen

SEX

FS

No overt lymphadenopathy or peritoneal effusion was present.

Rapid view of the heart revealed no evidence of pericardial masses or effusion in the visible window.

AGE

8 years

ULTRASONOGRAPHIC FINDINGS

- Nonhomogeneous to nodular splenic mass/masses
- Vacuolar hepatopathy pattern-subjectively benign
- Overtly normal stomach
- Intact yet prominent to mildly thickened small bowel walls
- Subtle intermittent urinary bladder micropolyploid luminal changes
- Rapid view of the heart-normal

WEIGHT

93.2 lb

INTERPRETED BY

R. McKenzie Daniel,
DVM, DABVP
(Canine and Feline)

INTERPRETATION OF THE FINDINGS & FURTHER RECOMMENDATIONS

The splenic mass/masses are nonspecific with considerations including hyperplasia, hematopoiesis, granuloma, splenitis, or neoplasia (sarcoma, round cell neoplasia, other). Correlation with pending splenic FNA is recommended.

IMAGING PERFORMED BY

Diane McFadden

The thickened small intestinal wall may indicate normal patient variant yet is suggestive of possible underlying nonspecific enteropathy given the reported weight loss in this patient. A GI panel to include PLI/TLI/Cobalamin/Folate is recommended.

HOSPITAL NAME

Mount Olive Veterinary
Hospital

Three view chest radiographs are suggested to assess for evidence of thoracic pathology or metastatic disease.

REFERRING VET

Dr. Jones

Pending additional diagnostics, splenectomy with potential for hepatic and full thickness intestinal biopsies may be considered. Clotting profile recommended prior to surgical considerations.

INVOICE

10833ag

DATE

06/17/2022



PATIENT

Athena Kazarian

SPECIES

Canine

BREED

Rottweiler

SEX

FS

AGE

8 years

WEIGHT

93.2 lb

INTERPRETED BY

R. McKenzie Daniel,
DVM, DABVP
(Canine and Feline)

IMAGING PERFORMED BY

Diane McFadden

HOSPITAL NAME

Mount Olive Veterinary
Hospital

REFERRING VET

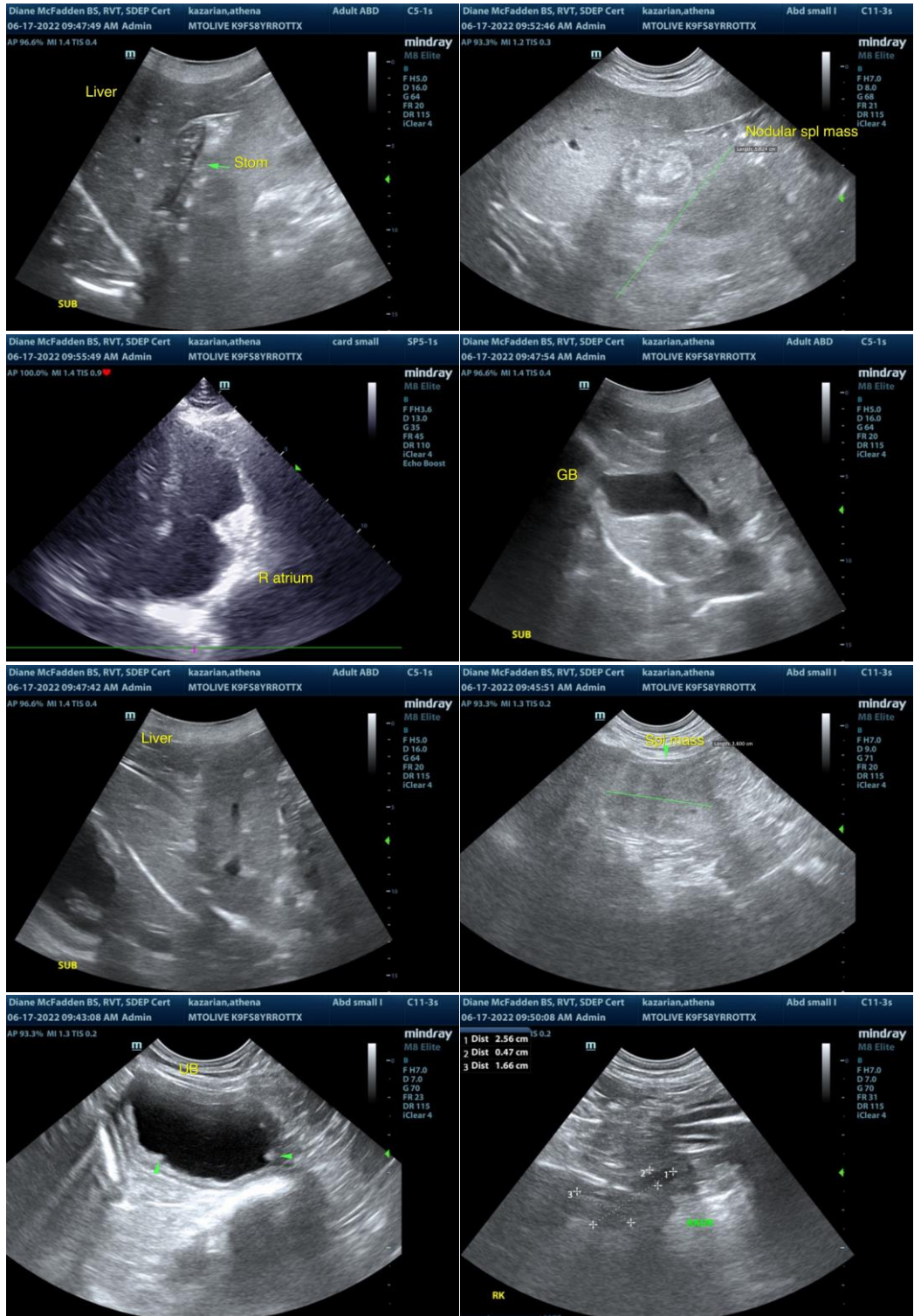
Dr. Jones

INVOICE

10833ag

DATE

06/17/2022





PATIENT

Athena Kazarian

SPECIES

Canine

BREED

Rottweiler

SEX

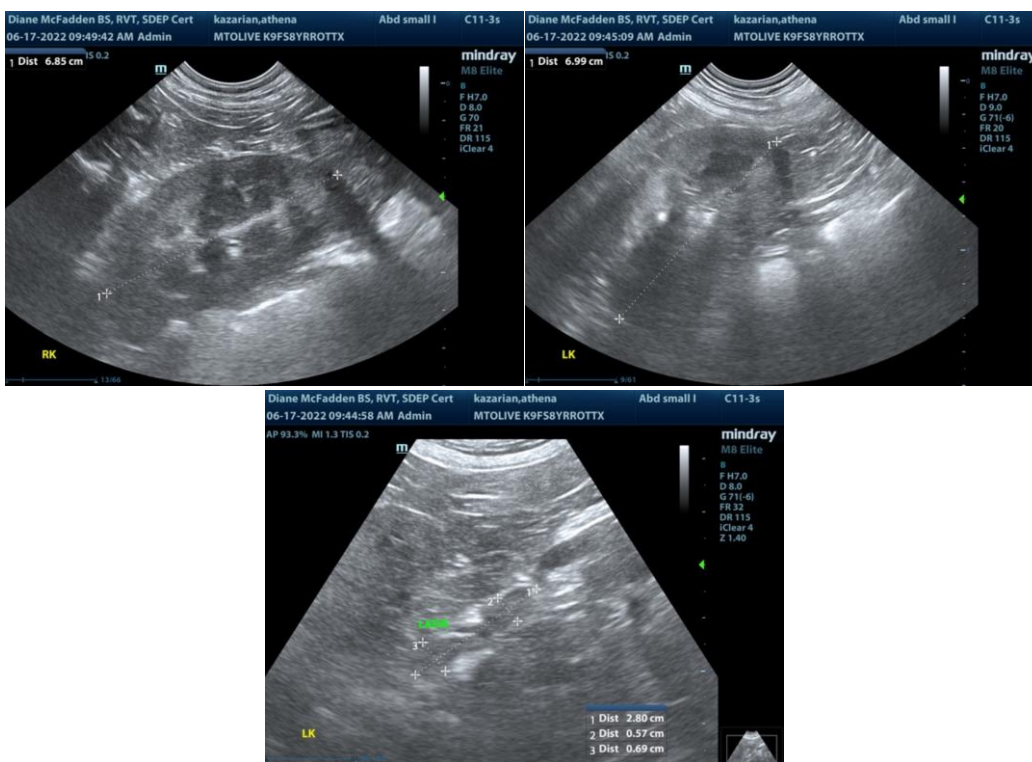
FS

AGE

8 years

WEIGHT

93.2 lb



INTERPRETED BY

R. McKenzie Daniel,
DVM, DABVP
(Canine and Feline)

IMAGING PERFORMED BY
Diane McFadden

HOSPITAL NAME

Mount Olive Veterinary
Hospital

REFERRING VET

Dr. Jones

INVOICE

10833ag

DATE

06/17/2022

The information and recommendations provided are based on the images presented by the referring veterinarian/sonographer. No evaluation can be communicated regarding pathology that was not visible in the image/video clips provided.

Thank you for this referral. If the clinical or image interpretation does not parallel your findings or if I can be of any further assistance please contact me.

R. McKenzie Daniel, DVM, DABVP (Canine / Feline Practice)

info@SonoPath.com