SonoPath
Clinical Sonography & Telecytology

EDUCATIONAL TELECONSULTATION SERVICES™

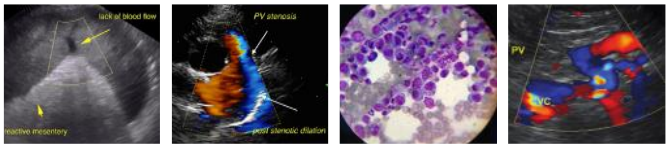

SonoPath.com™
1-800-838-4268 info@sonopath.com

PATIENT
Rebel O' Connor

SPECIES
Feline

BREED
DSH

SEX
MN

AGE
6 years

WEIGHT
9 lbs. 4 oz

INTERPRETED BY
R. McKenzie Daniel, DVM, DABVP (Canine and Feline)

IMAGING PERFORMED BY
Kelly Vazquez

HOSPITAL NAME
Marsh Hospital for Animals

REFERRING VET
Dr. Milwicki

INVOICE
14114

DATE
6/16/22

PRESENTING CLINICAL SIGNS

VPCs noted on pre-op ECG. No current meds. Finding from ECG report: Heart rate 186 bpm, rhythm with isolated VPCs.
Abnormal PE/Chem/CBC/UA Results: Bloods mostly WNL, T4 < 0.5 (low). UA: trace proteinuria, USG: 1.060.

ULTRASONOGRAPHIC EXAMINATION OF THE HEART & ABDOMEN

FELINE CARDIAC PARAMETERS	BODY WEIGHT (kg)	HR (BPM)	IVSd (cm)	LVIDd (cm)	LVWd (cm)	FS (%)	EF (%)
NORMAL PARAMETER	------	150-240	0.3-0.6	1.0-2.1	0.25-0.6	35-67	80-100
PATIENT		200	0.42	1.7	0.42	47.6	82.6
FELINE CARDIAC PARAMETERS	**LA/AO** (Boon)	**LA/AO HEART BASE** (Sisson)	**LA** 2D 4-chamber long axis AS to FW (Sisson) (cm)		**LVOT VEL.** (m/s)	**RVOT VEL.** (m/s)	**IVRT** (m/)
NORMAL PARAMETER	<1.5	0.88-1.79	0.7-1.7		<1.6	<1.3	40-60
PATIENT	1.38	1.27	1.2		1.1	1.1	NM

Adapted from June Boon,Veterinary Echocardiography,1998
Sisson D et al. JVIM 1991; 5: 232, Jacobs et al. Am J Vet Res 1985; 46:1705

Cardiac Presentation

The echocardiogram in this patient demonstrated normal **left atrial** size based on 3 separate LA measurements. The cranial and caudal **mitral** valve leaflets presented normal linear structure and kinetics. The **left ventricle** presented normal thicknesses with linear contour and was not dilated nor restricted. The **myocardium** presented normal echogenicity without subjective evidence of significant fibrotic or ischemic disease. **Contractility** of the ventricular walls was adequate and in normal range for this patient evidenced by the fractional shortening measurement and subjective evaluation of the different regions and angles of the myocardium. The **left ventricular outflow** tract demonstrated normal laminar flow and subjective structural integrity. The **right atrium** and auricle revealed normal size, structure and content. No evidence of masses was noted or chamber overload. **Tricuspid** valvular assessment demonstrated adequate linear morphology and kinetics. The **right ventricle** was of normal size (1/3 diameter of LV), chordae structure, myocardial echogenicity and thickness. **Pulmonic** tract assessment revealed normal valve structure, laminar flow, and diameter (approx.1:1 pa/ao ratio). No visible **pericardial** or free pleura fluid was noted or extra cardiac pathology in the visible planes. The cranial **mediastinum and pericardial regions** were free of masses in the visible window. Intermittent solitary arrhythmia suggestive of intermittent VPC, given the ECG, noted.

SonoPath
Clinical Sonography & Telecytology
EDUCATIONAL TELECONSULTATION SERVICES™

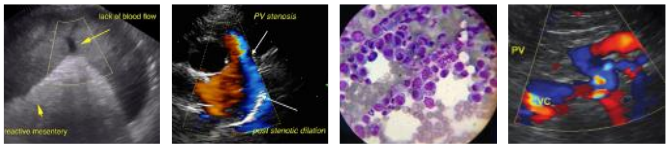

SonoPath.com™
1-800-838-4268 info@sonopath.com

PATIENT
Rebel O' Connor

SPECIES
Feline

BREED
DSH

SEX
MN

AGE
6 years

WEIGHT
9 lbs. 4 oz

INTERPRETED BY
R. McKenzie Daniel, DVM, DABVP (Canine and Feline)

IMAGING PERFORMED BY
Kelly Vazquez

HOSPITAL NAME
Marsh Hospital for Animals

REFERRING VET
Dr. Milwicki

INVOICE
14114

DATE
6/16/22

Urinary System

The urinary bladder, trigone, cystourethral junction, and visible pelvic urethra to a depth of 2.0 cm exhibited normal thickness and tone. Primarily anechoic urine was present in the lumen. Mild, nondependent, particulate to hyperechoic sediment was present without evidence of calculus formation. The ureteral papillae were normal. The ureters were not visible which is normal. No evidence of inflammatory or neoplastic mural changes were noted.

The area of the aortic trifurcation was free of pathology.

Normal size and margination were present in the kidneys. A normal 1:3 cortex / medulla ratio and normal corticomedullary definition were maintained. The echogenicity of the cortex was similar to or slightly less than normal liver parenchyma while the medulla echogenicity was hypoechoic to the cortex with no evidence of pelvic dilation. The left kidney measured 3.7 cm in length. The right kidney measured 3.7 cm in length.

Adrenal Glands

The left adrenal gland was uniform in size and contour with a uniformly hypoechoic parenchyma. The left adrenal gland measured 0.35 cm width. The right adrenal gland was uniform in size and contour with a uniformly hypoechoic parenchyma. The right adrenal gland measured 0.38 cm width.

Spleen

The spleen exhibited a finely textured and homogenous parenchyma which was hyperechoic to the liver and renal cortical parenchyma. The capsule was smooth and regular without apparent expansion. The splenic vasculature at the hilus was normal in volume with no evidence of congestion or thrombosis. Acute to chronic inflammatory, neoplastic, or benign parenchyma changes were not noted. The spleen measured 0.81 cm width.

Liver/ Gallbladder

The liver was subjectively normal in size, structure, and contour. The liver parenchyma was uniform and hypoechoic to the spleen with a mild coarse echotexture. The hepatic and portal vasculature were normal in appearance without signs of congestion. The gallbladder was non-distended in size with thin walls and primarily anechoic luminal content. The cystic and common bile ducts were normal.

Gastrointestinal

The stomach presented intact wall layering with a normal wall layer ratio. Mild retained nonshadowing Ingesta / chyme was present. The gastric body wall width measured 0.23 cm.

The small intestine presented intact wall layering with 1:3 muscularis/mucosa ratio. The lumen of the small intestine was empty with no signs of ileus, obstruction, or foreign material. The small intestinal wall width measured 0.22 cm.

Normal visible colon wall layers were present with apparent formed feces in lumen.

SonoPath
Clinical Sonography & Telecytology
EDUCATIONAL TELECONSULTATION SERVICES™

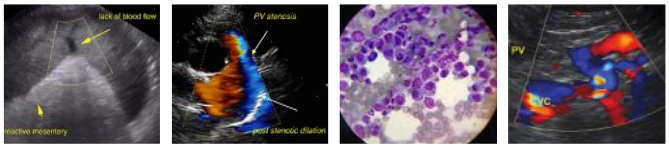

SonoPath.com™
1-800-838-4268 info@sonopath.com

PATIENT

Rebel O' Connor

SPECIES

Feline

BREED

DSH

SEX

MN

AGE

6 years

WEIGHT

9 lbs. 4 oz

INTERPRETED BY

R. McKenzie Daniel, DVM, DABVP (Canine and Feline)

IMAGING PERFORMED BY

Kelly Vazquez

HOSPITAL NAME

Marsh Hospital for Animals

REFERRING VET

Dr. Milwicki

INVOICE

14114

DATE

6/16/22

Pancreas

The parenchyma of the left limb, body, and right limb of the pancreas presented isoechoic to the adjacent omental fat. A normal curvilinear capsule contour of the pancreas was present. The visible pancreatic duct was normal. No signs of active inflammation or neoplastic disease were evident.

Free Abdomen

No omental masses, lymphadenopathy or peritoneal effusion were present.

ULTRASONOGRAPHIC FINDINGS

- Normal cardiac structure and function
- Intermittent solitary arrhythmia - suspect consistent with ventricular premature contraction
- Sonographically unremarkable abdomen with mild particulate to hyperechoic urinary bladder sediment

INTERPRETATION OF THE FINDINGS & FURTHER RECOMMENDATIONS

No evidence of structural / functional cardiomyopathy or overt Intraabdominal pathology as an obvious cause or contributing factor to the intermittent VPCs.

The urinary bladder sediment may indicate cellular debris / protein or crystalline debris. Given the trace proteinuria, baseline UPC level or urine culture and sensitivity (if evidence of inflammatory cells), could be considered.

Given the normal structural / functional presentation of the heart, no overt anesthetic contraindications, as well as no indication for cardiac medications. Unless clear episodes of syncope, weakness, etc., continued ECG monitoring for evidence of persistent / progressive VPCs would be reasonable. Consultation with a cardiologist prior to anesthesia is suggested.

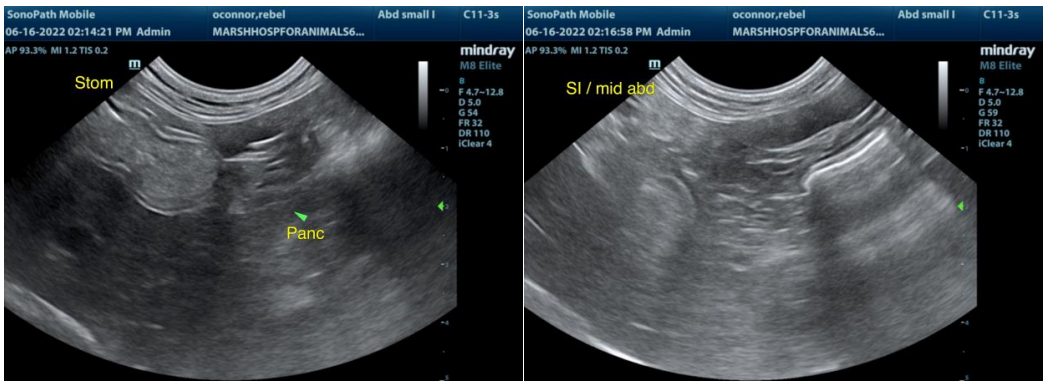

SonoPath

Clinical Sonography & Telecytology

EDUCATIONAL TELECONSULTATION SERVICES™

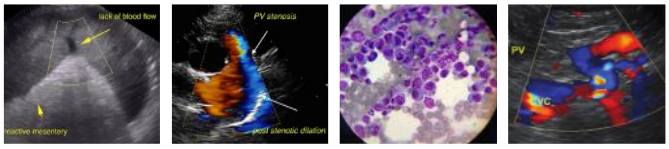

SonoPath.com™
1-800-838-4268 info@sonopath.com

PATIENT

Rebel O' Connor

SPECIES

Feline

BREED

DSH

SEX

MN

AGE

6 years

WEIGHT

9 lbs. 4 oz

INTERPRETED BY

R. McKenzie Daniel, DVM, DABVP (Canine and Feline)

IMAGING PERFORMED BY

Kelly Vazquez

HOSPITAL NAME

Marsh Hospital for Animals

REFERRING VET

Dr. Milwicki

INVOICE

14114

DATE

6/16/22

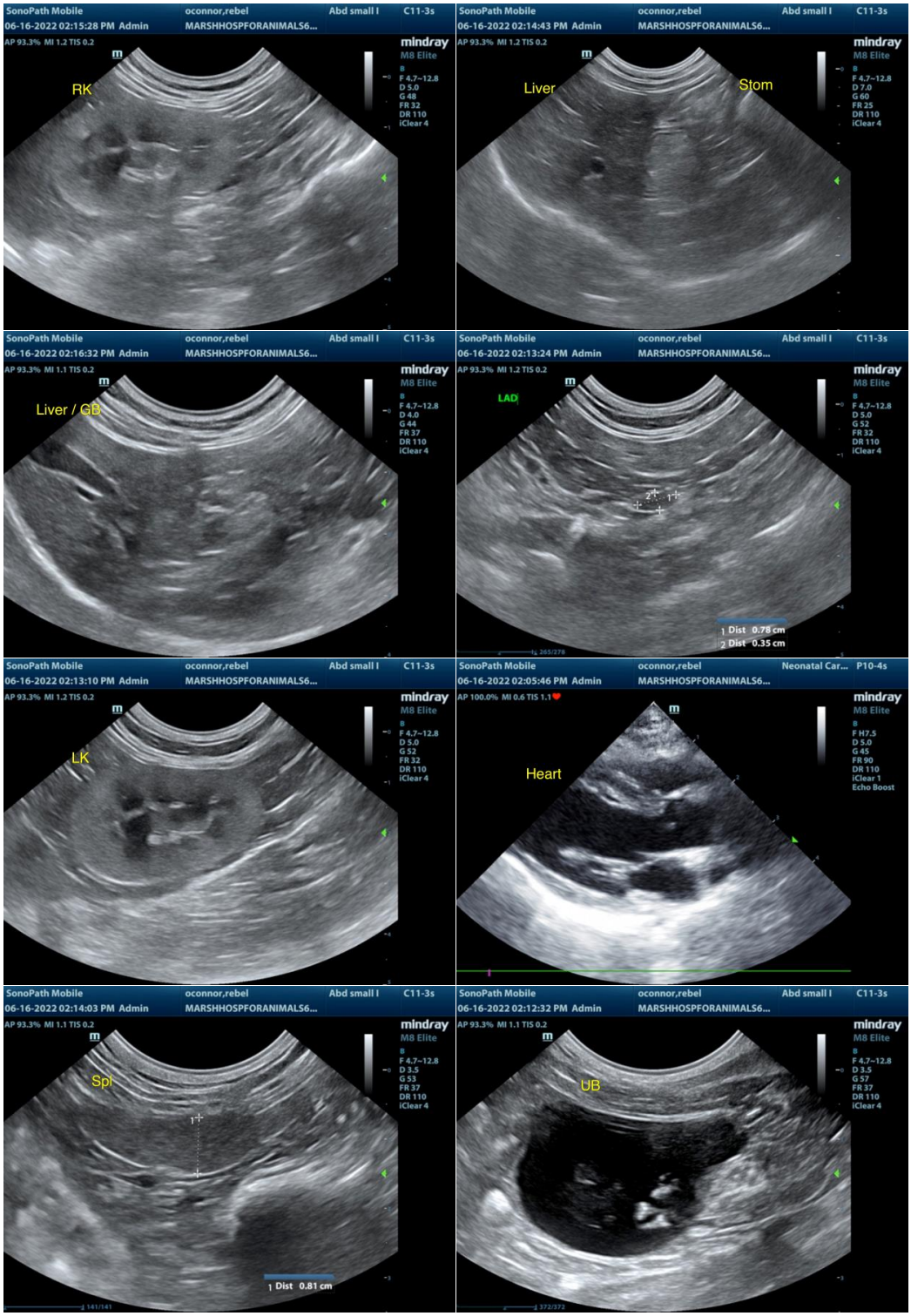

SonoPath
Clinical Sonography & Telecytology

EDUCATIONAL TELECONSULTATION SERVICES™

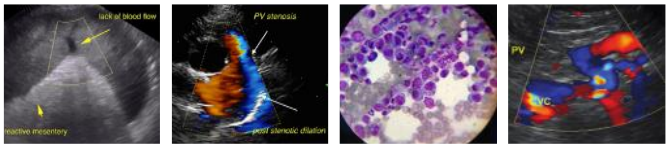

SonoPath.com™
1-800-838-4268 info@sonopath.com

PATIENT

Rebel O' Connor

SPECIES

Feline

BREED

DSH

SEX

MN

AGE

6 years

WEIGHT

9 lbs. 4 oz

INTERPRETED BY

R. McKenzie Daniel, DVM, DABVP (Canine and Feline)

IMAGING PERFORMED BY

Kelly Vazquez

HOSPITAL NAME

Marsh Hospital for Animals

REFERRING VET

Dr. Milwicki

INVOICE

14114

DATE

6/16/22

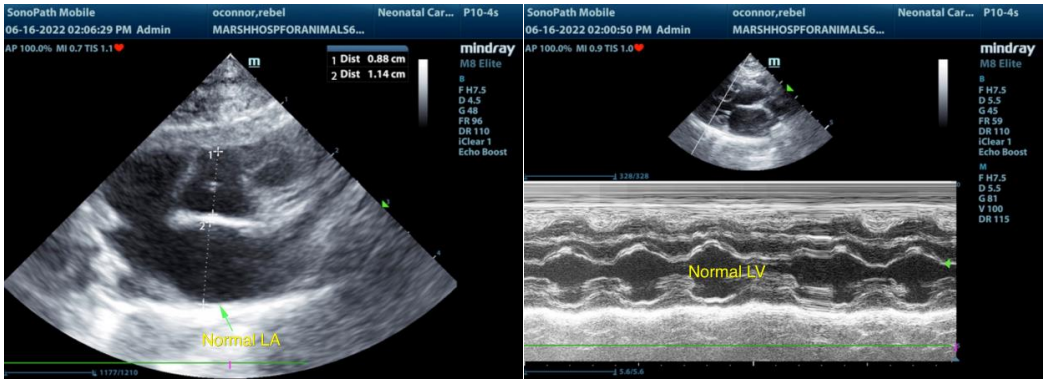

The information and recommendations provided are based on the images presented by the referring veterinarian/sonographer. No evaluation can be communicated regarding pathology that was not visible in the image/video clips provided.

Thank you for this referral. If the clinical or image interpretation does not parallel your findings or if I can be of any further assistance please contact me.

R. McKenzie Daniel, DVM, DABVP (Canine / Feline Practice)
info@SonoPath.com