SonoPath
Clinical Sonography & Telecytology

EDUCATIONAL TELECONSULTATION SERVICES™

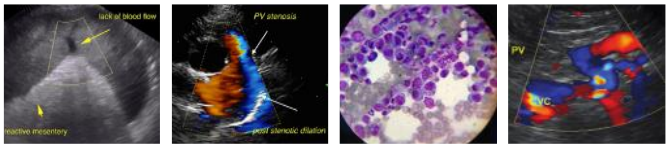

SonoPath.com™
1-800-838-4268 info@sonopath.com

PATIENT
Jersey Carroll

SPECIES
Canine

BREED
Border Collie

SEX
Male Neutered

AGE
12 years

WEIGHT
51.40 lbs.

INTERPRETED BY
R. McKenzie Daniel, DVM, DABVP (Canine and Feline)

IMAGING PERFORMED BY
Dr. Meridith Swart

HOSPITAL NAME
Swart Veterinary Imaging

REFERRING VET
Dr. Meridith Swart

INVOICE
14112

DATE
6/16/22

PRESENTING CLINICAL SIGNS

History of heart murmur. Serial echo performed every 6 months. Last one for comparison was sent to sonopath January 21. Patient is still non clinical for murmur. He is taking pimobendan 10 mg quadtabs 1/2 tab po bid.
Abnormal PE/Chem/CBC/UA Results: none reported

ULTRASONOGRAPHIC EXAMINATION OF THE HEART

CANINE CARDIAC PARAMETERS	MR VMAX (m/s)	TR VMAX (m/s)	LA/AO (Boon method)	LA/AO (Heart Base; Swe)	FS (%)	EF (%)	EPSS (cm)
NORMAL PARAMETER	4.5-5.5	<2.7	1.3	<1.3	28-40	40-100	<0.6
PATIENT			1.77	1.67	46.8	83	0.22
CANINE CARDIAC PARAMETERS	**HR** (BPM)	**AV VMAX** (m/s)	**PV MAX** (m/s)	**BODY WEIGHT** (kg)	**LA** 2D short axis Base view (cm)	**LVIDd** Avg; 2D and m-mode short axis (cm)	**LVIDs** Avg; 2D and m-mode short axis (cm)
NORMAL PARAMETER	50-100	0.7-1.7	0.7-1.6				
PATIENT	NM	1.0	1.0		4.3	3.7	

Cardiac Presentation

The echocardiogram in this patient demonstrated mildly enlarged **left atrial** size based on 3 different LA measurement methods. Chamber volumes and echogenicity were normal. The cranial and caudal **mitral** valve leaflets presented vegetative thickening consistent with endocardiosis. Doppler indicated eccentric insufficiency. The **left ventricle** presented thicknesses with linear contour and was not dilated nor restricted. The **myocardium** presented normal echogenicity without subjective evidence of significant fibrotic or ischemic disease. **Contractility** of the ventricular walls was adequate and in normal range for this patient evidenced by the fractional shortening measurement and subjective evaluation of the different regions of the myocardium. The **left ventricular outflow** tract demonstrated normal laminar flow and subjective structural integrity. The **right atrium** and auricle revealed normal size, structure and content. No evidence of masses was noted or chamber overload. **Tricuspid** valvular assessment demonstrated adequate linear morphology. The **right ventricle** was of normal size (1/3 diameter of LV), chordae structure, myocardial echogenicity and thickness. **Pulmonic** tract assessment revealed normal valve structure, laminar flow, and diameter (approx.1:1 pa/ao ratio). No visible **pericardial** or free pleura fluid was noted. No echographically detectable evidence of infiltrative disease was visible. The cranial **mediastinum and pericardial regions** were free of masses in the visible window.

SonoPath
Clinical Sonography & Telecytology
EDUCATIONAL TELECONSULTATION SERVICES™

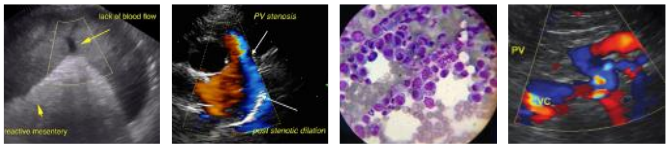

SonoPath.com™
1-800-838-4268 info@sonopath.com

PATIENT

Jersey Carroll

SPECIES

Canine

BREED

Border Collie

SEX

Male Neutered

AGE

12 years

WEIGHT

51.40 lbs.

INTERPRETED BY

R. McKenzie Daniel, DVM, DABVP (Canine and Feline)

IMAGING PERFORMED BY

Dr. Meridith Swart

HOSPITAL NAME

Swart Veterinary Imaging

REFERRING VET

Dr. Meridith Swart

INVOICE

14112

DATE

6/16/22

ULTRASONOGRAPHIC FINDINGS

- Chronic mitral valve disease (ACVIM mild B2)

INTERPRETATION OF THE FINDINGS & FURTHER RECOMMENDATIONS

Essentially static cardiac presentation compared to previous echo and consistent with chronic degenerative valvular changes with secondary eccentric mitral valve insufficiency as the cause of the murmur. The static mild LA enlargement indicates that the risk of current and future complication is somewhat elevated yet overall, the heart appears to be compensated in conjunction with lack of clinical signs. No other clinical issues such as LV systolic dysfunction or evidence of clinical pulmonary hypertension were noted.

Continued current Pimobendan is warranted. No other additional cardiac medications are indicated unless evidence of congestion i.e., increased resting respiration rate or evidence of pulmonary edema, which is considered unlikely. Serial sonographic monitoring is recommended for further prognosis. Recheck echocardiogram is suggested in 6 months, sooner if clinical signs arise.

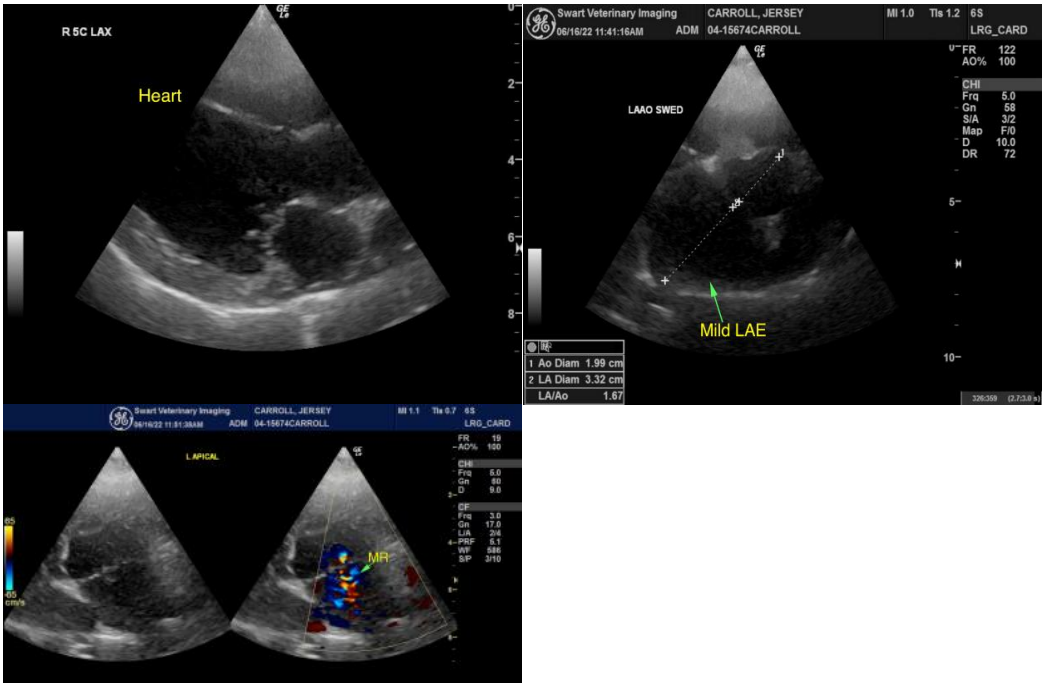

The information and recommendations provided are based on the images presented by the referring veterinarian/sonographer. No evaluation can be communicated regarding pathology that was not visible in the image/video clips provided.

Thank you for this referral. If the clinical or image interpretation does not parallel your findings or if I can be of any further assistance please contact me.

R. McKenzie Daniel, DVM, DABVP (Canine / Feline Practice)
info@SonoPath.com