



PATIENT

Eloise Sarfati

SPECIES

Canine

BREED

Golden Retriever

SEX

FS

AGE

6 years

WEIGHT

77 lbs.

INTERPRETED BY

R. McKenzie Daniel,
DVM, DABVP
(Canine and Feline)

IMAGING PERFORMED BY

Kelly Vazquez

HOSPITAL NAME

Marsh Hospital for
Animals

REFERRING VET

Dr. Milwicki

INVOICE

14113

DATE

6/16/22

PRESENTING CLINICAL SIGNS

Cardiac recheck. All bloods: WNL. No current meds.

ULTRASONOGRAPHIC EXAMINATION OF THE HEART & ABDOMEN

| CANINE | MR | TR | LA/AO | LA/AO | FS | EF | EPSS |
|---------------------------|----------------------|----------------------|---------------------|-------------------|------------------------------------|---------------------------------------|---------------------------------------|
| CARDIAC PARAMETERS | VMAX (m/s) | VMAX (m/s) | (Boon method) | (Heart Base; Swe) | (%) | (%) | (cm) |
| NORMAL PARAMETER | 4.5-5.5 | <2.7 | 1.3 | <1.3 | 28-40 | 40-100 | <0.6 |
| PATIENT | | | 1.1 | 1.4 | 50 | 85 | 0.2 |
| CANINE | HR | AV | PV | BODY WEIGHT | LA | LVIDd | LVIDs |
| CARDIAC PARAMETERS | (BPM) | VMAX (m/s) | MAX (m/s) | (kg) | 2D short axis Base view (cm) | Avg; 2D and m-mode short axis (cm) | Avg; 2D and m-mode short axis (cm) |
| NORMAL PARAMETER | 50-100 | 0.7-1.7 | 0.7-1.6 | | | | |
| PATIENT | 130 | 1.7 | 1.1 | | 3.4 | 3.8 | |

Cardiac Presentation

The echocardiogram in this patient demonstrated normal **left atrial** size based on 3 separate methods of LA evaluation. The cranial and caudal **mitral** valve leaflets presented normal linear structure, extension in systole, and union in diastole with normal kinesis. The **left ventricle** presented thicknesses with linear contour and was not dilated nor restricted. The **myocardium** presented normal echogenicity without subjective evidence of significant fibrotic or ischemic disease. **Contractility** of the ventricular walls was adequate and in normal range for this patient evidenced by the fractional shortening measurement and subjective evaluation of the different regions of the myocardium. The **left ventricular outflow** tract demonstrated normal laminar flow and subjective structural integrity. The **right atrium** and auricle revealed normal size, structure and content. No evidence of masses was noted. **Tricuspid** valvular assessment demonstrated adequate linear morphology and kinesis. The **right ventricle** was of normal size (1/3 diameter of LV), chordae structure, myocardial echogenicity and thickness. **Pulmonary outflow** tract assessment revealed normal valve structure, laminar flow, and diameter (approx. 1:1 pa/ao ratio). Trace pulmonic insufficiency was present on color doppler, not considered clinically significant. No visible **pericardial** or free pleura fluid was noted. The cranial **mediastinum and pericardial and extra-cardiac regions** were free of masses in the visible window.



PATIENT

Eloise Sarfati

SPECIES

Canine

BREED

Golden Retriever

SEX

FS

AGE

6 years

WEIGHT

77 lbs.

Urinary System

The urinary bladder, trigone, and cystourethral junction exhibited normal thickness and tone. Anechoic urine was present in the lumen with no uroliths or sediment. The ureteral papillae were normal. The ureters were not visible which is normal. No evidence of inflammatory or neoplastic changes was noted.

The area of the aortic trifurcation was free of pathology.

Normal size and margination were present in the kidneys. A normal 1:3 cortex / medulla ratio and normal corticomedullary definition were maintained. The echogenicity of the cortex was similar to or slightly less than normal liver parenchyma while the medulla echogenicity was hypoechoic to the cortex with no evidence of pelvic dilation. The left kidney measured 6.5cm in length. The right kidney measured 6.2 cm in length.

Adrenal Glands

The left adrenal gland was uniform in size and contour with a uniformly hypoechoic parenchyma. The left adrenal gland measured 2.4 cm length x 0.7 cm width at the caudal pole. The right adrenal gland was uniform in size and contour with a uniformly hypoechoic parenchyma. The right adrenal gland measured 2.3 cm length x 0.64 cm width at the caudal pole.

Spleen

The spleen exhibited a finely textured and homogenous parenchyma which was hyperechoic to the liver and renal cortical parenchyma. The capsule was smooth and regular without apparent expansion. The splenic vasculature at the hilus was normal in volume with no evidence of congestion or thrombosis. Acute to chronic inflammatory, neoplastic, or benign parenchyma changes were not noted.

Liver/ Gallbladder

The liver was subjectively normal in size, structure, and contour. The liver parenchyma was uniform and hypoechoic to the spleen with a mild coarse echotexture. The hepatic and portal vasculature were normal in appearance without signs of congestion. The gallbladder was non-distended in size with thin walls and primarily anechoic luminal content. The cystic and common bile ducts were normal.

Gastrointestinal

The stomach presented intact wall layering with a normal wall layer ratio. The lumen of the stomach was empty with no signs of ileus, obstruction, or foreign material.

The small intestine presented intact wall layering with 1:3 muscularis/mucosa ratio. The lumen of the small intestine was empty with no signs of ileus, obstruction, or foreign material.

Normal visible colon wall layers were present with apparent formed feces in lumen.

Pancreas

The parenchyma of the left limb, body, and right limb of the pancreas presented isoechoic to the adjacent omental fat. A normal curvilinear capsule contour of the pancreas was present. The visible pancreatic duct was normal. No signs of active inflammation or neoplastic disease were evident.

INTERPRETED BY

R. McKenzie Daniel,
DVM, DABVP
(Canine and Feline)

IMAGING PERFORMED BY

Kelly Vazquez

HOSPITAL NAME

Marsh Hospital for
Animals

REFERRING VET

Dr. Milwicki

INVOICE

14113

DATE

6/16/22



PATIENT

Free Abdomen

Eloise Sarfati

No overt lymphadenopathy or peritoneal effusion was present.

SPECIES

Canine

ULTRASONOGRAPHIC FINDINGS

- Normal echocardiogram
- Sonographically unremarkable abdomen

BREED

INTERPRETATION OF THE FINDINGS & FURTHER RECOMMENDATIONS

Golden Retriever

No evidence of cardiac or abdominal visceral pathology was present.

SEX

FS

AGE

6 years

WEIGHT

77 lbs.

INTERPRETED BY

R. McKenzie Daniel,
DVM, DABVP
(Canine and Feline)

IMAGING PERFORMED BY

Kelly Vazquez

HOSPITAL NAME

Marsh Hospital for
Animals

REFERRING VET

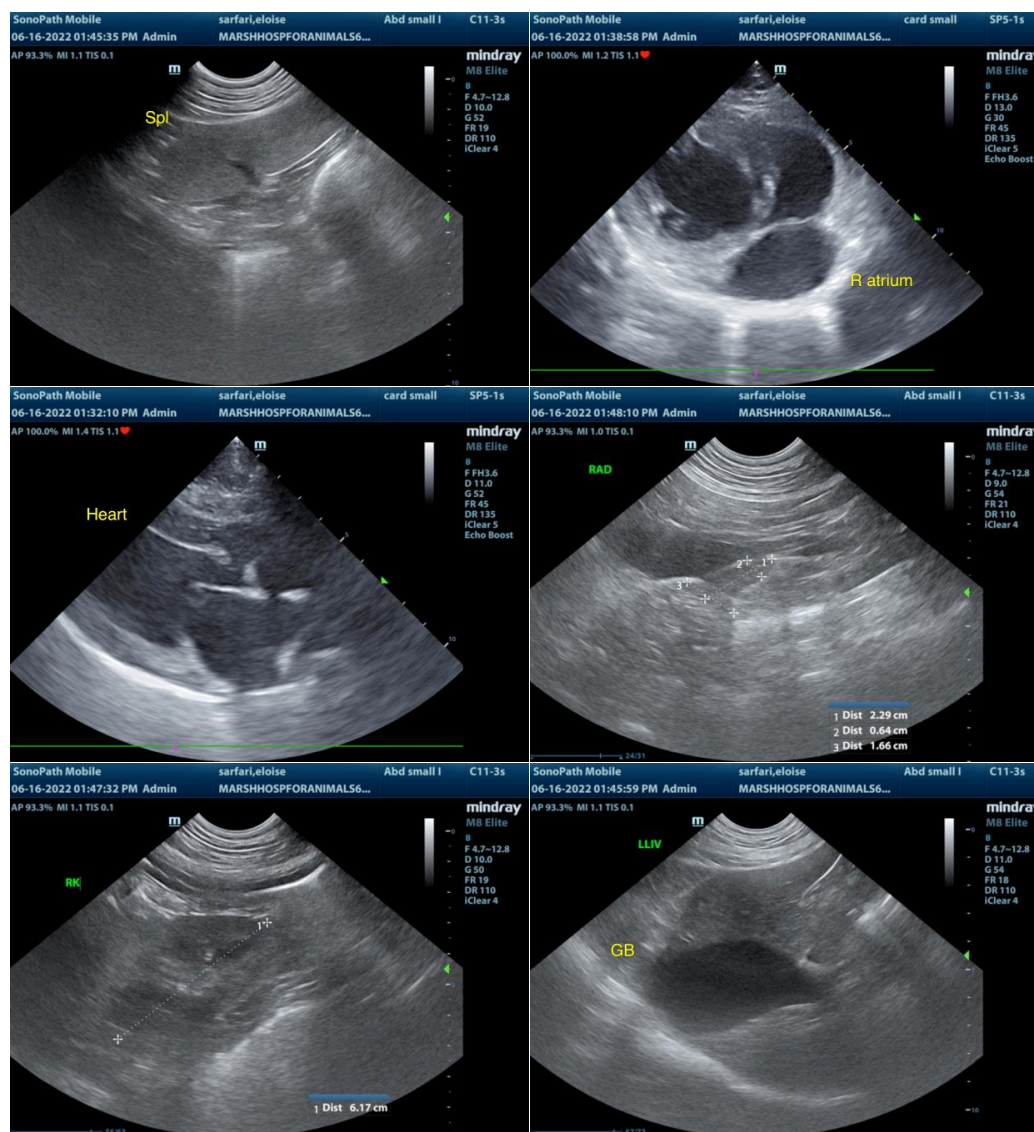
Dr. Milwicki

INVOICE

14113

DATE

6/16/22





PATIENT

Eloise Sarfati

SPECIES

Canine

BREED

Golden Retriever

SEX

FS

AGE

6 years

WEIGHT

77 lbs.

INTERPRETED BY

R. McKenzie Daniel, DVM, DABVP
(Canine and Feline)

IMAGING PERFORMED BY

Kelly Vazquez

HOSPITAL NAME

Marsh Hospital for Animals

REFERRING VET

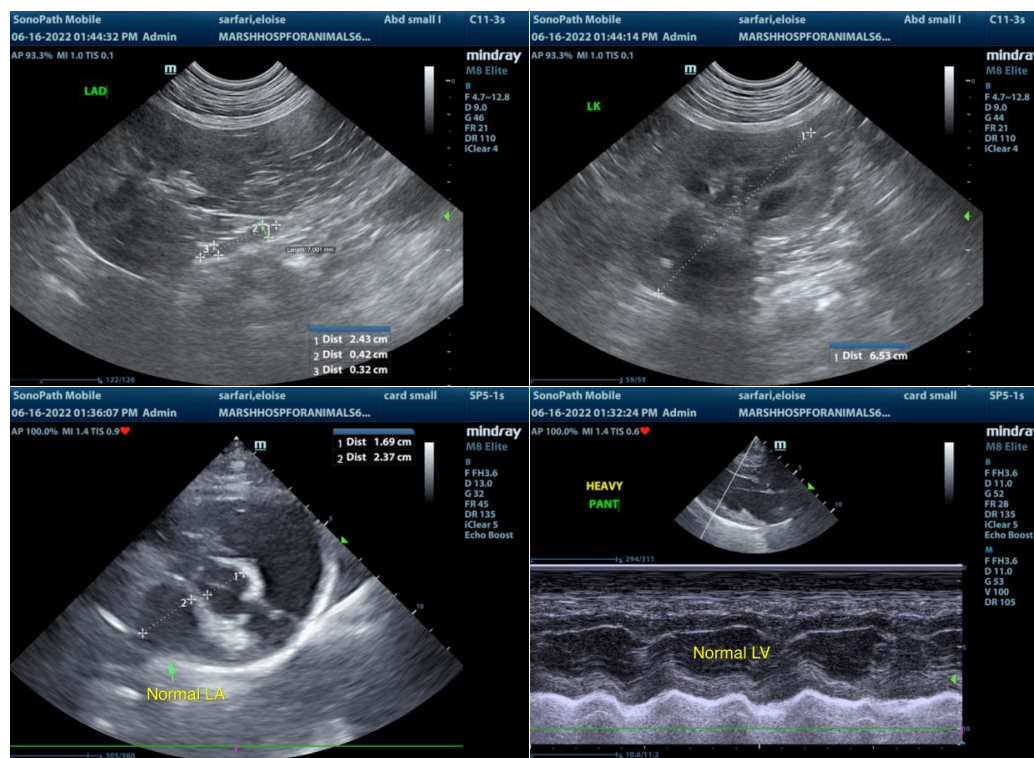
Dr. Milwicki

INVOICE

14113

DATE

6/16/22



The information and recommendations provided are based on the images presented by the referring veterinarian/sonographer. No evaluation can be communicated regarding pathology that was not visible in the image/video clips provided.

Thank you for this referral. If the clinical or image interpretation does not parallel your findings or if I can be of any further assistance please contact me.

R. McKenzie Daniel, DVM, DABVP (Canine / Feline Practice)
info@SonoPath.com