**PATIENT**

Mosley Greenhaw

SPECIES

Canine

BREED

Yorkie

SEX

MN

AGE

13 years

WEIGHT

11.2 lbs.

INTERPRETED BYR. McKenzie Daniel,
DVM, DABVP (Canine
and Feline)**IMAGING
PERFORMED BY**

Rachel Runnells, RVT

HOSPITAL NAME

SVS Imaging KC

REFERRING VET

Dr. Jennifer Simon

INVOICE

16102

DATE

6/15/22

PRESENTING CLINICAL SIGNS

Chronic elevated liver enzymes. Recent seizure like symptoms and had low RBC on recent bloodwork. Abnormal PE/Chem/CBC/UA Results: Anemia slight, high reticulocytes, monocytosis, high liver enzymes.

ULTRASONOGRAPHIC EXAMINATION OF THE ABDOMEN**Urinary System**

The urinary bladder was mildly subnormal in size owing to lack of urine distention, which prohibited full evaluation of the urinary bladder walls. Potential for minor age-related micropolypoid luminal changes with very minor nondependent particulate sediment noted. No overt evidence of neoplastic criteria.

The residual prostate was free of overt pathology.

No evidence of medial iliac or sublumbar lymphadenopathy in the area of the iliac trifurcation.

Normal size and margination were present in the kidneys. A normal 1:3 cortex / medulla ratio was maintained. The medulla and cortices were uniform in texture with some increased echogenicity and moderate loss of corticomedullary symmetry and definition expected for the age of the patient. Mild pyelectasia and multiple small cortical cysts were present in both kidneys. Pinpoint medullary mineral was present. The left kidney measured 4.4 cm in length. The right kidney measured 4.6 cm in length.

Adrenal Glands

The bilateral adrenal glands were normal in size. Mild parenchyma heterogeneity and mild capsule asymmetry was present without suspicion for overt neoplasia. The left adrenal gland measured 0.51 cm width in the cranial pole and 0.86 cm width in the caudal pole. The right adrenal gland measured 0.54 cm width in the cranial pole and 0.55 cm width in the caudal pole.

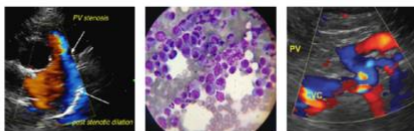
Spleen

A mildly expansive nonhomogeneous asymmetrical mass was noted in the caudal aspect of the spleen, measuring approximately 4.5 cm- 5.0 cm in diameter. The mass appeared to distort the splenic capsule contour. Subtle evidence of potential cavitation was associated with the mass. Mild perisplenic reactive mesentery was noted around the mass. The spleen, not associated with the mass, exhibited generalized parenchyma heterogeneity, including multiple pinpoint hyperechoic foci, which although nonspecific, may indicate pinpoint areas of splenic microinfarction, fibrosis or mineralization. Splenic vascularity was normal. Evidence of overt splenic mass rupture and secondary hemoabdomen not noted.

Liver/ Gallbladder

The liver exhibited moderate to marked generalized enlargement. Hepatic contour was rounded with areas of mild hepatic asymmetry. Generalized mildly hyperechoic to nonuniform hepatic parenchyma, exhibiting multiple thinly walled intraparenchymal cysts, containing anechoic fluid were present, along with multiple variable sized nonhomogeneous intraparenchymal macronodules to potential small masses. An example of liver macronodule to small mass measured 3.0 cm in diameter.

The gallbladder was non-distended in size with primarily anechoic content and mild mineralized luminal debris. The cystic and common bile ducts were normal.

**PATIENT**

Mosley Greenhaw

SPECIES

Canine

BREED

Yorkie

SEX

MN

AGE

13 years

WEIGHT

11.2 lbs.

INTERPRETED BYR. McKenzie Daniel,
DVM, DABVP (Canine
and Feline)**IMAGING
PERFORMED BY**

Rachel Runnells, RVT

HOSPITAL NAME

SVS Imaging KC

REFERRING VET

Dr. Jennifer Simon

INVOICE

16102

DATE

6/15/22

Gastrointestinal

The stomach presented intact wall layering with a normal wall layer ratio. The lumen of the stomach was empty with no signs of ileus, obstruction, or foreign material.

The small intestine presented intact wall layering with 1:3 muscularis/mucosa ratio. The lumen of the small intestine was empty with no signs of ileus, obstruction, or foreign material.

Normal visible colon wall layers were present with apparent formed feces in lumen.

Pancreas

The pancreas was normal in size and contour with isoechoic to heterogeneous parenchyma compared to adjacent omentum. No signs of active inflammation or neoplasia.

Free Abdomen

A focal small pocket of peritoneal free fluid was present in the mid to caudal abdomen.

ULTRASONOGRAPHIC FINDINGS

- Mixed echogenic caudal splenic mass
- Chronic hepatopathy, exhibiting nonuniform parenchymal remodeling, intermittent parenchymal cysts and nonspecific nonhomogeneous macronodules to potential small masses
- Mild mineralized gallbladder debris
- Bilateral chronic renal changes, exhibiting pinpoint medullary mineral and cortical cysts

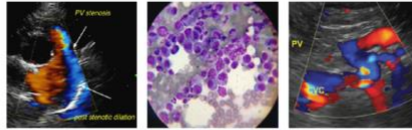
INTERPRETATION OF THE FINDINGS & FURTHER RECOMMENDATIONS

The splenic mass is nonspecific with considerations including hyperplasia, hematopoiesis, granuloma, splenitis, or neoplasia (sarcoma, round cell neoplasia, other). Neoplastic criteria is considered likely yet not definitive.

Considerations for the hepatic presentation may include chronic vacuolar hepatopathy, chronic inflammatory/immune mediated disease, areas of nodular hyperplasia, hematopoiesis, fibrosis, lipogranulomas in addition to the intraparenchymal cysts, primary versus metastatic hepatic neoplasia or other hepatopathy.

Sonographically, the nonhomogeneous hepatic macronodules to small masses are suspicious for neoplastic criteria, although given the chronic hepatopathy in this patient, previously mentioned benign etiologies are possible.

Assuming normal clotting status, splenic mass and hepatic parenchymal/nodule FNA could be considered for further screening cytology. Three-view chest radiographs are recommended to assess for evidence of thoracic pathology, as well as cardiopulmonary status. If splenectomy is elected in this case, hepatic biopsy would be strongly recommended. Overall, very guarded to potentially unfavorable long-term prognosis.



PATIENT

Mosley Greenhaw

SPECIES

Canine

BREED

Yorkie

SEX

MN

AGE

13 years

WEIGHT

11.2 lbs.

INTERPRETED BY

R. McKenzie Daniel, DVM, DABVP (Canine and Feline)

IMAGING PERFORMED BY

Rachel Runnells, RVT

HOSPITAL NAME

SVS Imaging KC

REFERRING VET

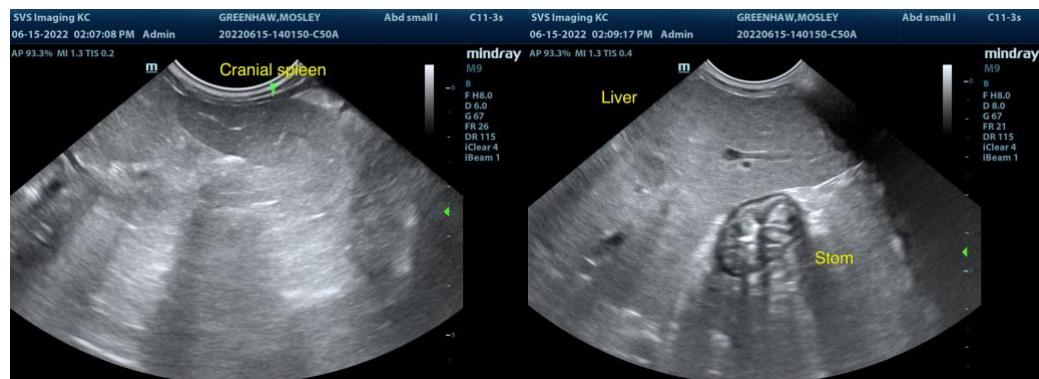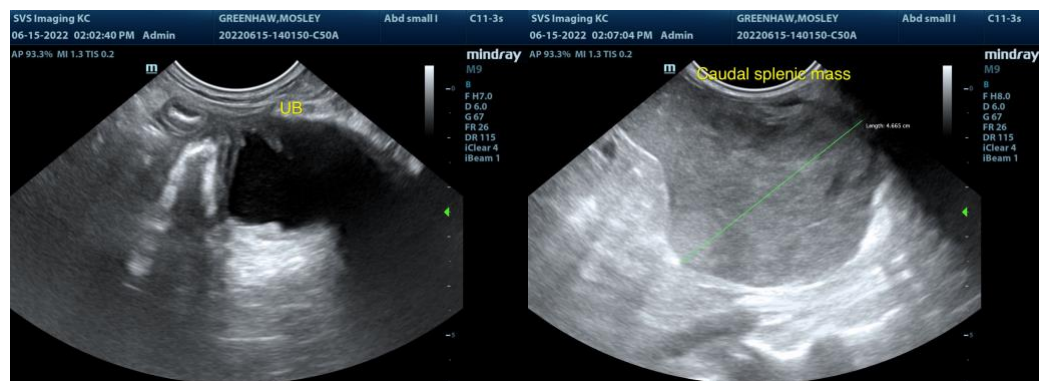
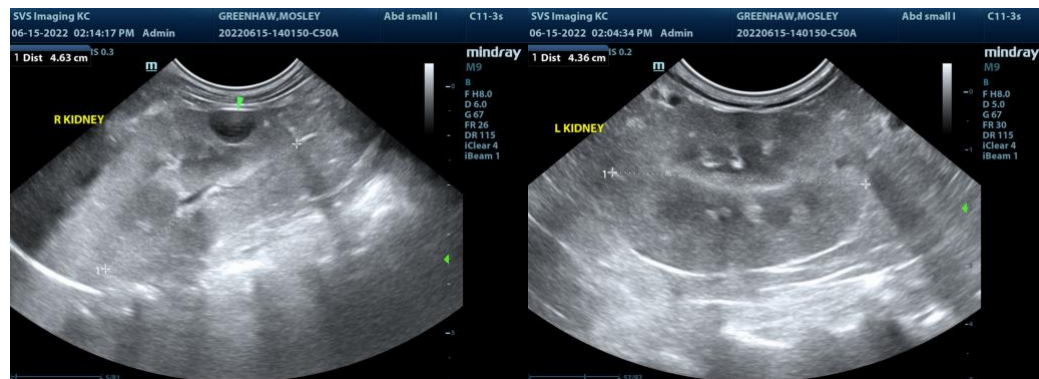
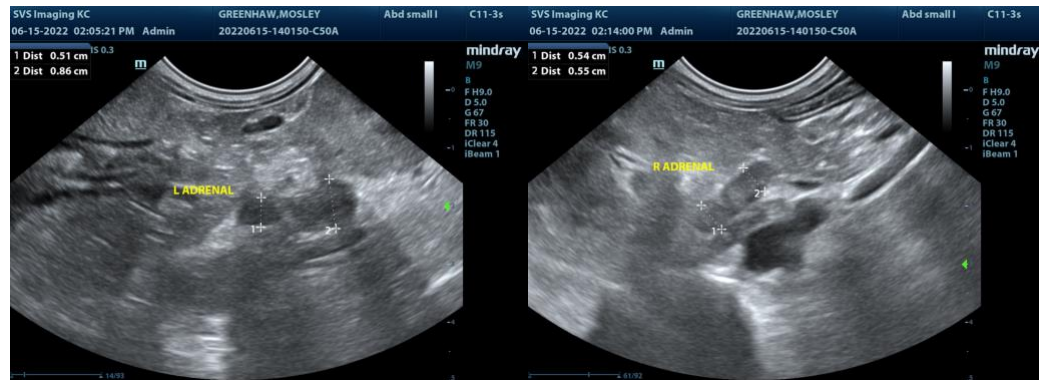
Dr. Jennifer Simon

INVOICE

16102

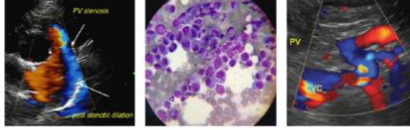
DATE

6/15/22



IMAGING PERFORMED BY

SVS Mobile Imaging KC 816-401-5010
svsimagingkc@gmail.com



Clinical Sonography & Telecytology

EDUCATIONAL TELECONSULTATION SERVICES™

1-800-838-4268 info@sonopath.com SonoPath.com

PATIENT

Mosley Greenhaw

SPECIES

Canine

BREED

Yorkie

SEX

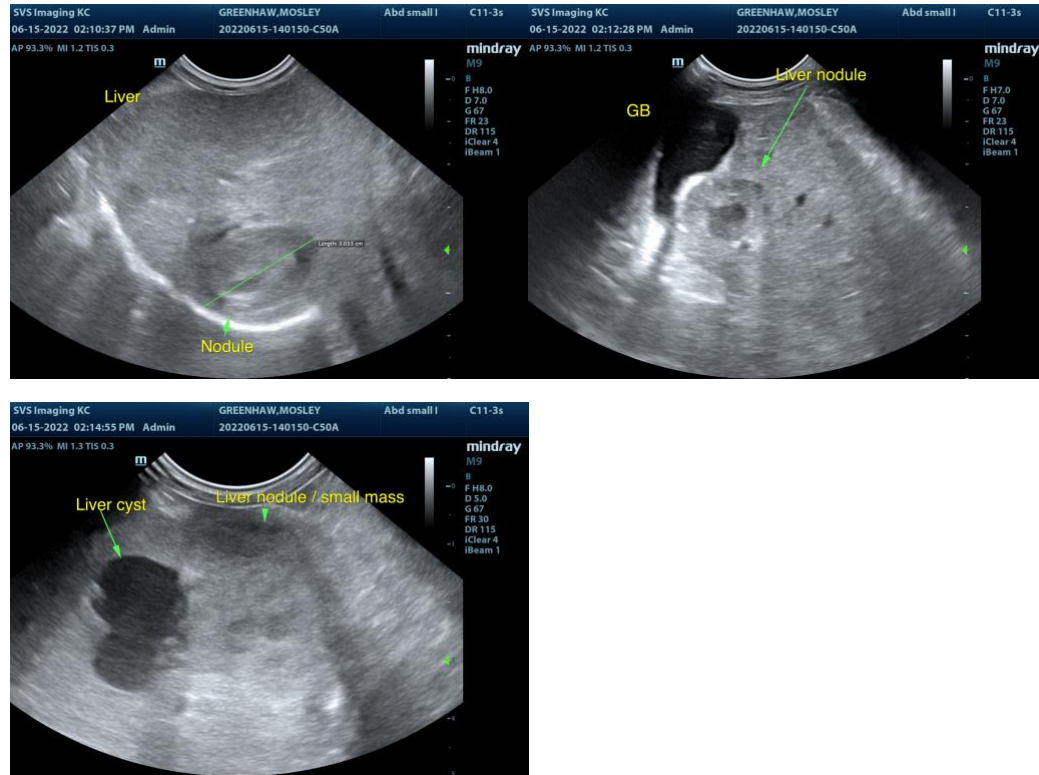
MN

AGE

13 years

WEIGHT

11.2 lbs.



INTERPRETED BY

R. McKenzie Daniel,
DVM, DABVP (Canine
and Feline)

The information and recommendations provided are based on the images presented by the referring veterinarian/sonographer. No evaluation can be communicated regarding pathology that was not visible in the image/video clips provided.

Thank you for this referral. If the clinical or image interpretation does not parallel your findings or if I can be of any further assistance please contact me.

IMAGING PERFORMED BY

Rachel Runnells, RVT

R. McKenzie Daniel, DVM, DABVP (Canine / Feline Practice)
info@SonoPath.com

HOSPITAL NAME

SVS Imaging KC

REFERRING VET

Dr. Jennifer Simon

INVOICE

16102

DATE

6/15/22