



PATIENT

Jimi Goodrich

SPECIES

Feline

BREED

DSH

SEX

MN

AGE

10 years

WEIGHT

11.8

INTERPRETED BY

R. McKenzie Daniel,
DVM, DABVP
(Canine and Feline)

IMAGING PERFORMED BY

Dr. Brita Kiffney

HOSPITAL NAME

Northshore VH

REFERRING VET

Dr. Brita Kiffney

INVOICE

13980

DATE

6/1/22

PRESENTING CLINICAL SIGNS

Jimi is a chronically shy guy, however O had recently observed more subdued behavior by px. ie. sleeping/hiding more, appetite/water consumption/litter box changes seemed consistent per O. Recurrent chin acne most recently potentially exacerbated by a diet change-O has since gone back to original diet.

Abnormal PE/Chem/CBC/UA Results: cbc, chemistry screen, lytes OK, u/a showed hematuria/cystitis/increased epithelial cells with no signs cancer on cytologic review via idexx

ULTRASONOGRAPHIC EXAMINATION OF THE ABDOMEN

Urinary System

The urinary bladder, trigone, cystourethral junction, and visible pelvic urethra to a depth of 2.0 cm exhibited normal thickness and tone. Anechoic urine was present in the lumen with no uroliths or sediment. The ureteral papillae were normal. The ureters were not visible which is normal. No evidence of inflammatory or neoplastic changes was noted.

The area of the aortic trifurcation was free of pathology.

Normal size and margination were present in the kidneys. A normal 1:3 cortex / medulla ratio and normal corticomedullary definition were maintained. The echogenicity of the cortex was similar to or slightly less than normal liver parenchyma while the medulla echogenicity was hypoechoic to the cortex with no evidence of pelvic dilation. A subtle to intermittent hyperechoic corticomedullary band, consistent with a subtle to intermittent medullary rim sign, was present. This is a nonspecific finding seen in both normal and abnormal kidneys. It may be associated interstitial renal disease, hypercalcemia, tubular necrosis, lymphoma, and FIP. However, it is a nonspecific finding. The left kidney measured 4.3 cm in length. The right kidney measured 4.0 cm in length.

Adrenal Glands

The left adrenal gland was uniform in size and contour with a uniformly hypoechoic parenchyma. The left adrenal gland measured 0.35 cm width. The right adrenal gland was uniform in size and contour with a uniformly hypoechoic parenchyma. The right adrenal gland measured 0.39 cm width.

Spleen

The spleen exhibited a finely textured and homogenous parenchyma which was hyperechoic to the liver and renal cortical parenchyma. The capsule was smooth and regular without apparent expansion. The splenic vasculature at the hilus was normal in volume with no evidence of congestion or thrombosis. Acute to chronic inflammatory, neoplastic, or benign parenchyma changes were not noted. The spleen measured 0.66 cm in width.

Liver/ Gallbladder

The liver was subjectively normal in size, structure, and contour. The liver parenchyma was uniform and hypoechoic to the spleen with a mild coarse echotexture. The hepatic and portal vasculature were normal in appearance without signs of congestion. The gallbladder was non-distended in size with thin walls and primarily anechoic luminal content. The cystic and common bile ducts were normal.



PATIENT

Jimi Goodrich

SPECIES

Feline

BREED

DSH

SEX

MN

AGE

10 years

WEIGHT

11.8

INTERPRETED BY

R. McKenzie Daniel,
DVM, DABVP
(Canine and Feline)

IMAGING PERFORMED BY

Dr. Brita Kiffney

HOSPITAL NAME

Northshore VH

REFERRING VET

Dr. Brita Kiffney

INVOICE

13980

DATE

6/1/22

Gastrointestinal

The stomach presented intact wall layering with a normal wall layer ratio. The lumen of the stomach was empty with no signs of ileus, obstruction, or foreign material. The gastric body wall width measured 0.24 cm.

The small intestine presented intact wall layering with 1:3 muscularis/mucosa ratio. The lumen of the small intestine was empty with no signs of ileus, obstruction, or foreign material. The jejunum wall width measured 0.22 cm. The ileocolic wall width measured 0.27 cm.

Normal visible colon wall layers were present with apparent formed feces in lumen.

Pancreas

The parenchyma of the left limb, body, and right limb of the pancreas presented isoechoic to the adjacent omental fat. A normal curvilinear capsule contour of the pancreas was present. The visible pancreatic duct was normal. No signs of active inflammation or neoplastic disease were evident.

Free Abdomen

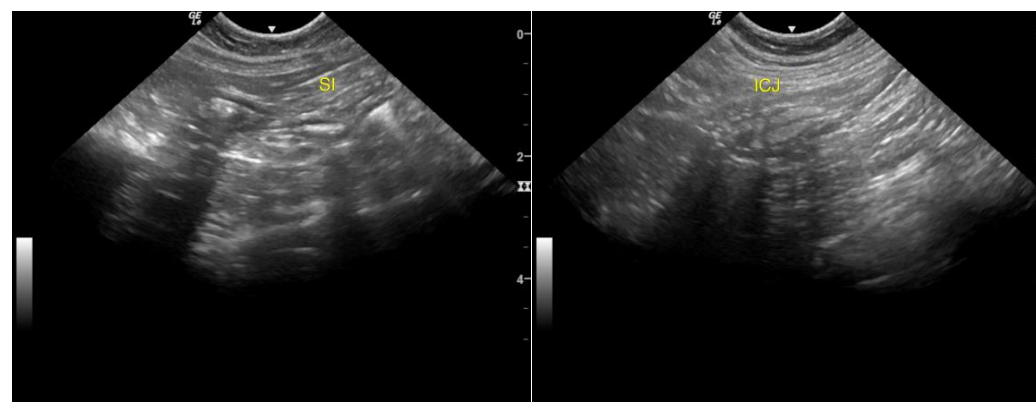
No overt lymphadenopathy or peritoneal effusion was present.

ULTRASONOGRAPHIC FINDINGS

- Bilateral nonspecific subtle renal medullary rim sign, otherwise sonographically unremarkable abdomen

INTERPRETATION OF THE FINDINGS & FURTHER RECOMMENDATIONS

Overall, largely mild geriatric abdomen without evidence of significant visceral pathology. Further renal staging to include urine C/S and protein: creatinine ratio on sterile urine sample may be considered.





PATIENT

Jimi Goodrich

SPECIES

Feline

BREED

DSH

SEX

MN

AGE

10 years

WEIGHT

11.8

INTERPRETED BY

R. McKenzie Daniel,
DVM, DABVP
(Canine and Feline)

IMAGING PERFORMED BY

Dr. Brita Kiffney

HOSPITAL NAME

Northshore VH

REFERRING VET

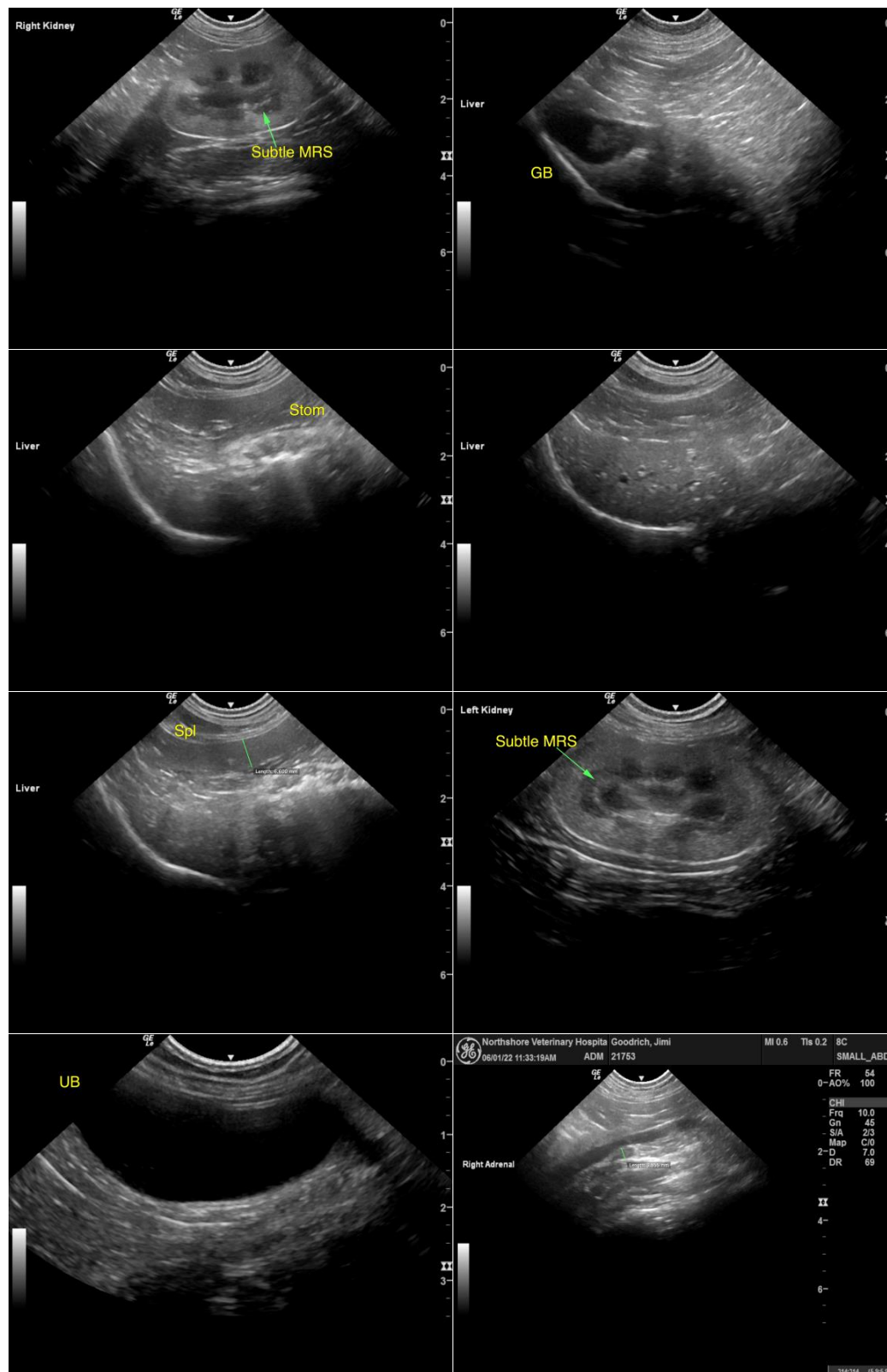
Dr. Brita Kiffney

INVOICE

13980

DATE

6/1/22





PATIENT

Jimi Goodrich

The information and recommendations provided are based on the images presented by the referring veterinarian/sonographer. No evaluation can be communicated regarding pathology that was not visible in the image/video clips provided.

SPECIES

Feline

Thank you for this referral. If the clinical or image interpretation does not parallel your findings or if I can be of any further assistance please contact me.

BREED

DSH

R. McKenzie Daniel, DVM, DABVP (Canine / Feline Practice)
info@SonoPath.com

SEX

MN

AGE

10 years

WEIGHT

11.8

INTERPRETED BY

R. McKenzie Daniel,
DVM, DABVP
(Canine and Feline)

**IMAGING
PERFORMED BY**

Dr. Brita Kiffney

HOSPITAL NAME

Northshore VH

REFERRING VET

Dr. Brita Kiffney

INVOICE

13980

DATE

6/1/22