



PATIENT	PRESENTING CLINICAL SIGNS
Jax Geremia	Non clinical but somewhat lethargic. Good appetite
SPECIES	Abnormal PE/Chem/CBC/UA Results: Mild elevation of renal enzymes and severe elevation of ALPK with mild low protein
Canine	ULTRASONOGRAPHIC EXAMINATION OF THE ABDOMEN
BREED	Urinary System
Rottweiler	The urinary bladder was subnormal in size owing to lack of urine distension which prohibited full evaluation of the urinary bladder walls. The urinary bladder, trigone, cystourethral junction, and visible pelvic urethra exhibited normal thickness and tone. The ventroapical urinary bladder wall measured 0.61 cm in width. Anechoic urine was present in the lumen with no uroliths or sediment. The ureteral papillae were normal. The ureters were not visible which is normal. No evidence of inflammatory or neoplastic changes were noted.
SEX	
MI	
AGE	Normal renal size with asymmetrical margination was present in both kidneys. The renal cortex presented uniformly increased in echogenicity with uniform echotexture. The renal cortex appeared to be hypertrophied resulting in an altered cortex: medulla ratio. Mild loss of corticomodullary distinction was also present. The renal medullary volume was subjectively reduced. The left kidney measured 6.7 cm in length. The right kidney measured 7.6 cm in length.
WEIGHT	The area of the aortic trifurcation was free of pathology.
52kg	The prostate was enlarged in size with intact, symmetrical capsule contour. The margins of the gland were intact and able to be differentiated from the surrounding tissue. The prostatic parenchyma was mildly echogenic to heteroechoic without parenchymal mineralization. The prostate measured 3.3 cm in diameter. Intermittent small anechoic, thinly walled parenchyma cysts were present.
INTERPRETED BY	Adrenal Glands
R. McKenzie Daniel, DVM, DABVP (Canine and Feline)	The left adrenal gland was uniform in size and contour with a uniformly hypoechoic parenchyma. The left adrenal gland measured 0.69 cm width at the caudal pole and 0.58 cm width at the cranial pole. The right adrenal gland was uniform in size and contour with a uniformly hypoechoic parenchyma. The right adrenal gland measured 0.58 cm width at the caudal pole and 0.71 cm width at the cranial pole.
IMAGING PERFORMED BY	Spleen
Dr. Belan	The spleen exhibited normal size and overall contour. Subtle medial folding of the caudal spleen was present. An intermittent discrete hypoechoic non-disruptive splenic nodule was present. No overt splenic masses. The splenic vasculature at the hilus was normal in volume with no evidence of congestion or thrombosis.
HOSPITAL NAME	Liver/Gallbladder
Calgary Holistic	The liver was subjectively normal in size, structure, and contour. The liver parenchyma was uniform and hypoechoic to the spleen with a mild coarse echotexture. The hepatic and portal vasculature were normal in appearance without signs of congestion. The gallbladder was non-distended in size with thin walls and primarily anechoic luminal content. The cystic and common bile ducts were normal.
REFERRING VET	Gastrointestinal
Dr. Qi	
INVOICE	
13764ag	
DATE	
05/09/2023	



PATIENT	The stomach presented intact wall layering with a normal wall layer ratio. The lumen of the stomach contained mild ingesta sonographically consistent with food with no signs of ileus, obstruction or foreign material.
Jax Geremia	
SPECIES	The small intestine presented intact wall layering with 1:3 muscularis/mucosa ratio. The lumen of the small intestine was empty with no signs of ileus, obstruction or foreign material.
Canine	
BREED	Pancreas Normal visible colon wall layers were present with apparent formed feces in lumen.
Rottweiler	
SEX	Free Abdomen
MI	No peritoneal effusion was present. No omental lymphadenopathy.
AGE	A moderately sized spherical non-homogenous cystic to cavitated mass containing anechoic fluid component was present in the mid abdomen measuring ~ 11 cm in diameter. No evidence of mass mineralization. No evidence of regional omentum inflammation.
9yr	
WEIGHT	ULTRASONOGRAPHIC FINDINGS
52kg	<ul style="list-style-type: none"> • Unspecified non-homogenous cavitated mass in the mid abdomen-consolidated abscess, necrosis or necrotic granuloma, marked cystic to potentially necrotic mesenteric lymphadenopathy, neoplasia or other. • Bilateral early to mild chronic renal changes. • Benign prostatic hyperplasia with small intraparenchymal cyst, possible prostatitis. • Subjective benign hepatopathy, sonographically unremarkable gallbladder.
INTERPRETED BY	INTERPRETATION OF THE FINDINGS & FURTHER RECOMMENDATIONS
R. McKenzie Daniel, DVM, DABVP (Canine and Feline)	Assuming normal clotting status and using a 25g needle, a mass parenchyma FNA and centesis of fluid component for screening cytology +/- C/S is warranted for further assessment. The mass did not overtly appear to involve or originate from the spleen, liver, bilateral kidneys or adrenal glands. Concurrent screening hepatic parenchyma FNA cytology would be suggested if sampling is elected.
IMAGING PERFORMED BY	Further renal staging to include urine C/S and protein: creatinine ratio on sterile urine sample may be considered.
Dr. Belan	
HOSPITAL NAME	Three view chest radiographs are recommended if not done to assess for occult thoracic pathology.
Calgary Holistic	
REFERRING VET	Alternative considerations could include exploratory laparotomy with gross inspection of the unspecified mass with potential for biopsy or resection as well as hepatic biopsies assuming normal clotting status and depending upon stabilization of mild azotemia with IVF.
Dr. Qi	
INVOICE	
13764ag	
DATE	
05/09/2023	



PATIENT

Jax Geremia

SPECIES

Canine

BREED

Rottweiler

SEX

MI

AGE

9yr

WEIGHT

52kg

INTERPRETED BY

R. McKenzie Daniel,
DVM, DABVP
(Canine and Feline)

IMAGING PERFORMED BY

Dr. Belan

HOSPITAL NAME

Calgary Holistic

REFERRING VET

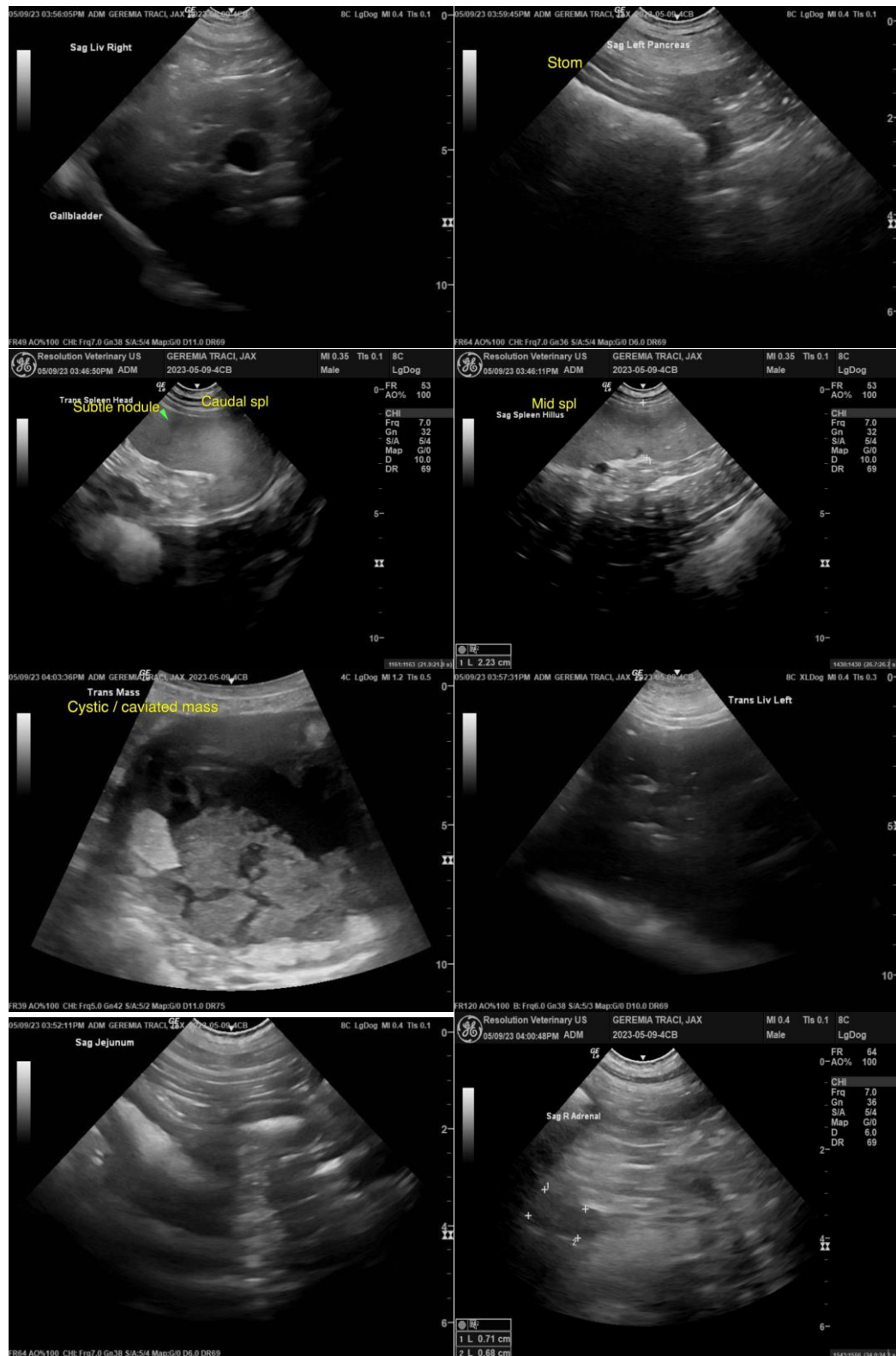
Dr. Qi

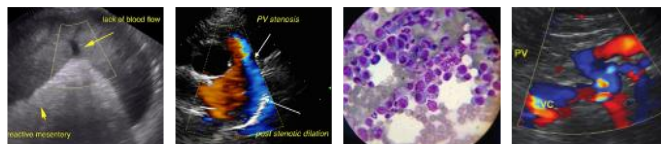
INVOICE

13764ag

DATE

05/09/2023





PATIENT

Jax Geremia

SPECIES

Canine

BREED

Rottweiler

SEX

MI

AGE

9yr

WEIGHT

52kg

INTERPRETED BY

R. McKenzie Daniel,
DVM, DABVP
(Canine and Feline)

IMAGING PERFORMED BY

Dr. Belan

HOSPITAL NAME

Calgary Holistic

REFERRING VET

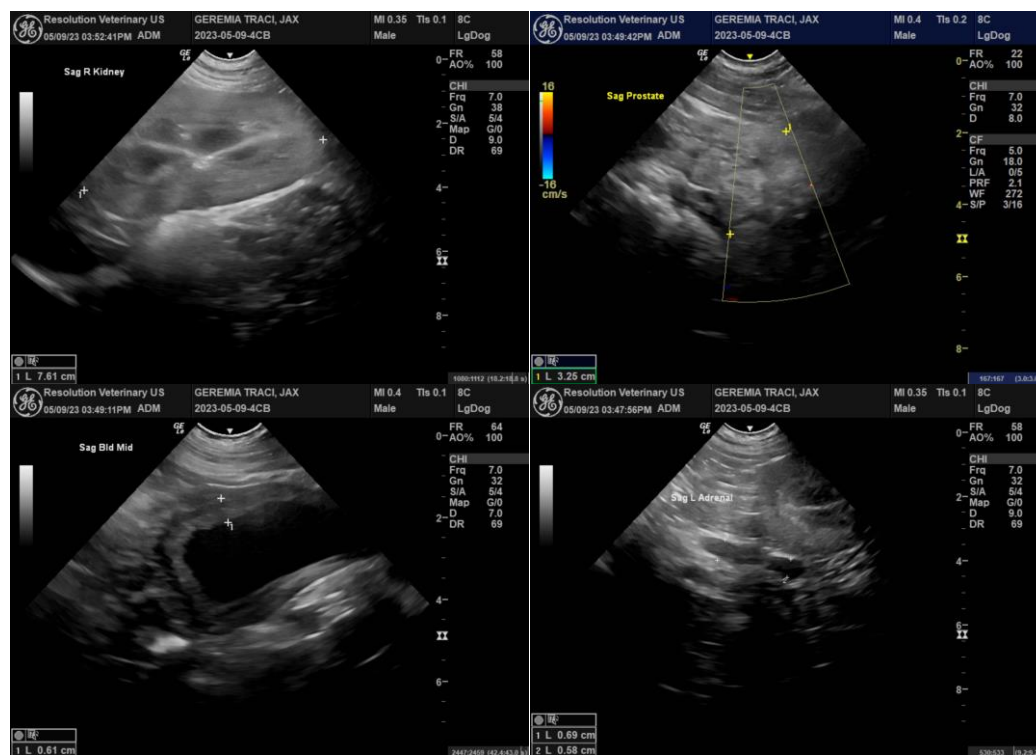
Dr. Qi

INVOICE

13764ag

DATE

05/09/2023



The information and recommendations provided are based on the images presented by the referring veterinarian/sonographer. No evaluation can be communicated regarding pathology that was not visible in the image/video clips provided.

Thank you for this referral. If the clinical or image interpretation does not parallel your findings or if I can be of any further assistance, please contact me.

R. McKenzie Daniel, DVM, DABVP (Canine/Feline Practice)
mac.daniel@sonopath.com