**PATIENT**

Milo Lynch

SPECIES

Canine

BREED

Shih Tzu/Yorkie

SEX

Neutered Male

AGE

9 Years

WEIGHT

13 Pounds

INTERPRETED BYR. McKenzie Daniel,
DVM, DABVP
(Canine and Feline)**IMAGING
PERFORMED BY**

Sarah Pender, CVT

HOSPITAL NAME

SVS Imaging QC

REFERRING VET

Dr. Mike White

INVOICE

37564

DATE

5/9/22

PRESENTING CLINICAL SIGNS

vomiting, not eating well, weight loss

Abnormal PE/Chem/CBC/UA Results: PLI Abnormal GLOB 4.8 rest of Chem 17 WNL, CBC RETIC 221.1, WBC 21.44, RETIC-HGB 21.4, NEU 16.43, MONO 2.01, PCT 0.54 rest of CBC WNL, Radiographs NSF

ULTRASONOGRAPHIC EXAMINATION OF THE ABDOMEN**Urinary System**

The urinary bladder, trigone, cystourethral junction, and visible pelvic urethra to a depth of – cm exhibited normal thickness and tone. Anechoic urine was present in the lumen with no uroliths or sediment. The ureteral papillae were normal. The ureters were not visible which is normal. No evidence of inflammatory or neoplastic changes were noted.

Normal size and margination were present in the kidneys. A normal 1:3 cortex / medulla ratio was maintained. The medulla and cortices were uniform in texture with some increased echogenicity and mild loss of corticomedullary symmetry and definition expected for the age of the patient. No evidence of pelvic dilation was present. The left kidney measured 4.2 cm. The right kidney measured 4.2 cm.

Adrenal Glands

The adrenal glands were uniform in size and contour with a uniformly hypoechoic parenchyma. The right adrenal gland measured 2.0 cm length x 0.63 cm at the caudal pole. The left adrenal gland measured 2.0 cm x 0.66 cm at the caudal pole.

Spleen

The spleen exhibited a finely textured and homogenous parenchyma which was hyperechoic to the liver and renal cortical parenchyma. The capsule was smooth and regular without apparent expansion. The splenic vasculature at the hilus was normal in volume with no evidence of congestion or thrombosis. Acute to chronic inflammatory, neoplastic, or benign parenchyma changes were not noted.

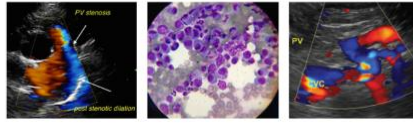
Liver

The liver was subjectively normal in size, structure, and contour. The liver parenchyma was uniform and hypoechoic to the spleen with a mild coarse echotexture. The hepatic and portal vasculature were normal in appearance without signs of congestion. The gallbladder was non-distended in size with thin walls and primarily anechoic luminal content. Mild inspissated yet non-organized gallbladder debris. The cystic and common bile ducts were normal.

Gastrointestinal

The stomach exhibited moderate distention with retained anechoic fluid, extending into the area of the pylorus and pyloric outflow.

An upper duodenal and gastroduodenal junction mural mass was present, exhibiting mild non-homogeneous echogenic mural echogenicity, extending caudally from the gastroduodenal junction to involve the initial 2.5-3.0 cm of the upper duodenum was present. The mass measured approximately 3.0-4.0 cm in length x 2.7 cm in diameter. The portion of the upper duodenum not involved with the mass as well as the mid and distal duodenum exhibited intact and sonographically unremarkable wall layering. Normal appearing duodenal wall measured 0.53 cm. The jejunum and ileum to the level of the colon were sonographically normal.

**PATIENT**

Normal visible colon wall layers were present with subjective semiformal feces in the descending colon.

Milo Lynch

Pancreas**SPECIES**

The left limb, right limb, and base of the pancreas presented hypoechoic to heterogeneous echogenicity compared to adjacent omental fat. Mild asymmetrical capsule margination was present with mild variable parenchymal swelling and mild peripancreatic to regional upper gastrointestinal reactive mesentery. No overt evidence of neoplasia.

Canine

BREED**Free Abdomen**

Shih Tzu/Yorkie

Intermittent, mildly prominent to enlarged gastric to pancreaticoduodenal lymph nodes were present. The lymph node was essentially isoechoic to adjacent omentum without evidence of peripheral inflammation and maintaining a normal width: length ratio (<0.5).

SEX

Neutered Male

ULTRASONOGRAPHIC FINDINGS**AGE**

9 Years

- Upper duodenal/gastroduodenal junction mural mass
- Moderate gastric distention with retained anechoic fluid
- Suspect mild concurrent pancreatitis
- Regional perigastric and peripancreatic reactive mesentery with intermittent, subjectively benign, mild gastric and pancreaticoduodenal lymphadenopathy
- Mild gallbladder debris (non-mucocele)

WEIGHT

13 Pounds

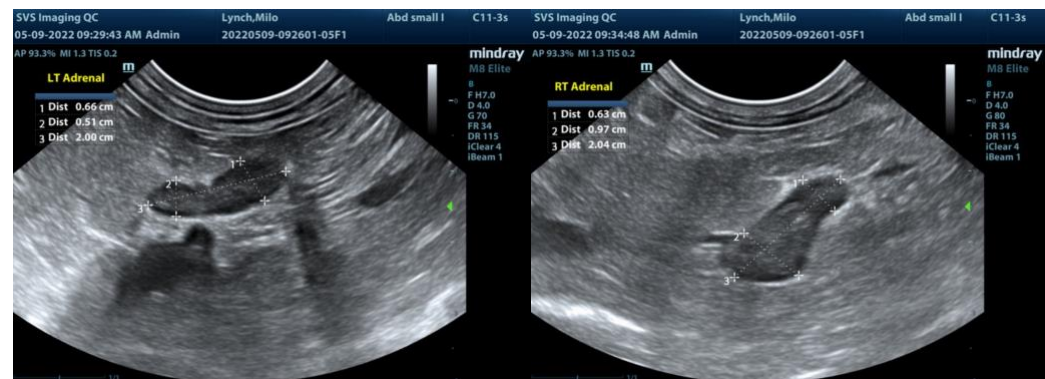
INTERPRETATION OF THE FINDINGS & FURTHER RECOMMENDATIONS**INTERPRETED BY**

R. McKenzie Daniel,
DVM, DABVP
(Canine and Feline)

Given the moderate retained gastric fluid, some degree of mechanical pyloric outflow obstruction secondary to the upper duodenal and gastroduodenal junction mural mass is likely. Biopsies of the upper duodenal to gastroduodenal junction mural mass is required for definitive diagnosis. Surgical consultation for biopsies +/- billroth procedure recommended. No overt evidence of regional metastasis. 3-view chest radiographs suggested. Empirically, as-needed gastrointestinal support, which may include canned hydrolyzed diet with smaller, more frequent feedings and as-needed gastroprotectants would be reasonable.

IMAGING PERFORMED BY

Sarah Pender, CVT

**HOSPITAL NAME**

SVS Imaging QC

REFERRING VET

Dr. Mike White

INVOICE

37564

DATE

5/9/22



PATIENT

Milo Lynch

SPECIES

Canine

BREED

Shih Tzu/Yorkie

SEX

Neutered Male

AGE

9 Years

WEIGHT

13 Pounds

INTERPRETED BY

R. McKenzie Daniel,
DVM, DABVP
(Canine and Feline)

IMAGING PERFORMED BY

Sarah Pender, CVT

HOSPITAL NAME

SVS Imaging QC

REFERRING VET

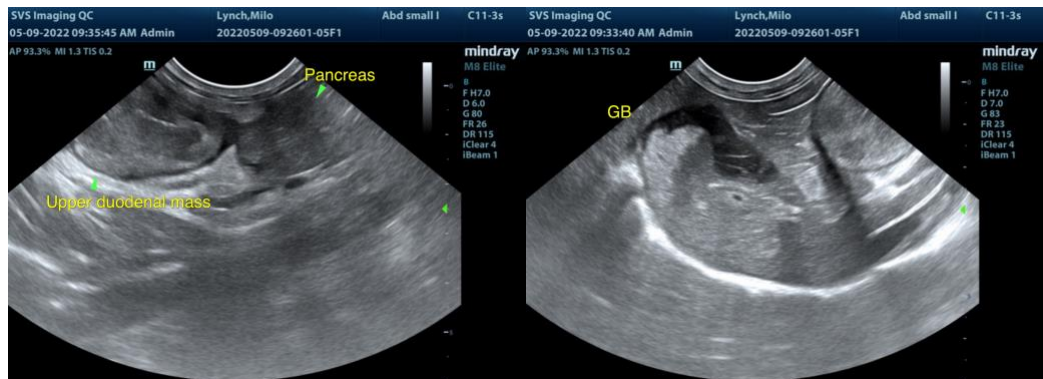
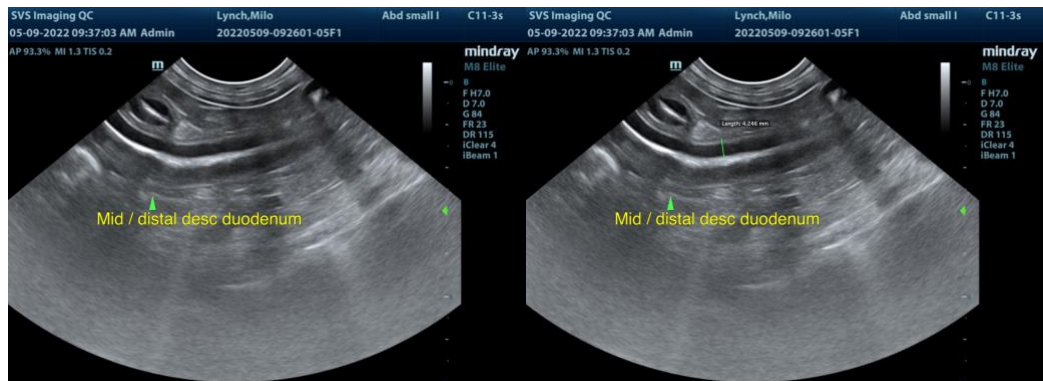
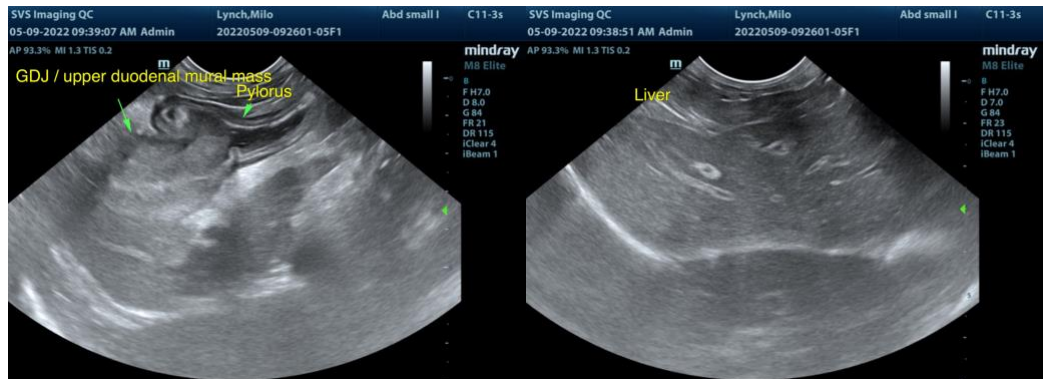
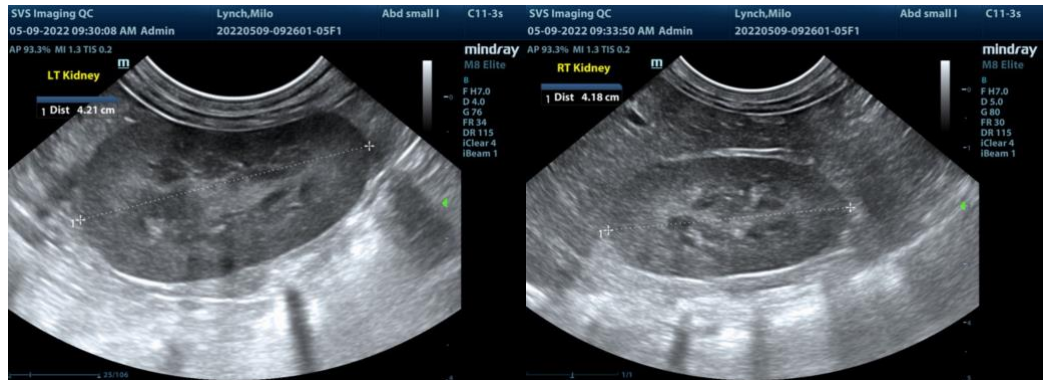
Dr. Mike White

INVOICE

37564

DATE

5/9/22



IMAGING PERFORMED BY

svsimaging.net 309-737-3070



Clinical Sonography & Telectology

EDUCATIONAL TELECONSULTATION SERVICES™

1-800-838-4268 info@sonopath.com SonoPath.com

PATIENT

Milo Lynch

SPECIES

Canine

BREED

Shih Tzu/Yorkie

SEX

Neutered Male

AGE

9 Years

WEIGHT

13 Pounds

INTERPRETED BY

R. McKenzie Daniel,
DVM, DABVP
(Canine and Feline)

**IMAGING
PERFORMED BY**

Sarah Pender, CVT

HOSPITAL NAME

SVS Imaging QC

REFERRING VET

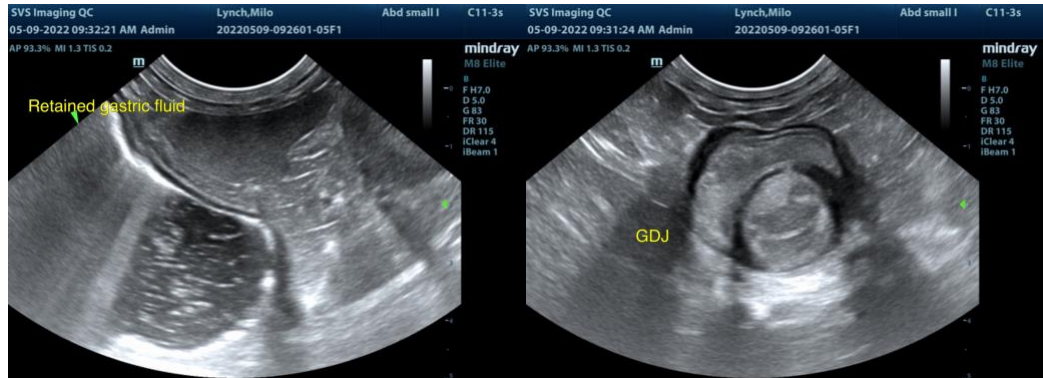
Dr. Mike White

INVOICE

37564

DATE

5/9/22



The information and recommendations provided are based on the images presented by the referring veterinarian/sonographer. No evaluation can be communicated regarding pathology that was not visible in the image/video clips provided.

Thank you for this referral. If the clinical or image interpretation does not parallel your findings or if I can be of any further assistance please contact me.

R. McKenzie Daniel, DVM, DABVP (Canine / Feline Practice)

info@SonoPath.com