PAUS
Pet Animal Ultrasound Service
4paus.com 781-635-5677

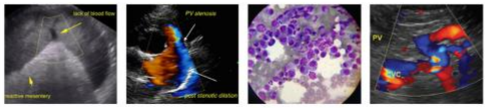

SonoPath
Clinical Sonography & Telecytology
EDUCATIONAL TELECONSULTATION SERVICES™
1-800-838-4268 info@sonopath.com SonoPath.com

PATIENT
Dexter Sullivan

SPECIES
Canine

BREED
Boston Terrier

SEX
Neutered Male

AGE
12 Years

WEIGHT
30 Pounds

INTERPRETED BY
R. McKenzie Daniel, DVM, DABVP (Canine and Feline)

IMAGING PERFORMED BY
Pamela Harrigan, RDCS

HOSPITAL NAME
Chase Vet Clinic

REFERRING VET
Dr. Halli Lipinski

INVOICE
37560

DATE
5/10/22

PRESENTING CLINICAL SIGNS

Preanesthetic labwork for mass removal in March showed elevated ALT (179), and ALP (1475). Recheck showed significant increase in values from prior: ALT (935) and ALT (1475). Dexter is doing well clinically. Also has a new grade II/VI systolic murmur and mildly elevated proBNP (995). Started on Denamarin 225 mg SID.

ULTRASONOGRAPHIC EXAMINATION OF THE ABDOMEN

Urinary System

The urinary bladder, trigone, cystourethral junction, and visible pelvic urethra to a depth of – cm exhibited normal thickness and tone. Anechoic urine was present in the lumen with no uroliths or sediment. The ureteral papillae were normal. The ureters were not visible which is normal. No evidence of inflammatory or neoplastic changes were noted.

The residual prostate was symmetrically normal in size (0.88 cm diameter) with uniform parenchyma and slight coarse echotexture.

Normal size and margination was present in the kidneys. A normal 1:3 cortex / medulla ratio was maintained. The medulla and cortices were uniform in texture with some increased echogenicity and loss of corticomedullary symmetry and definition expected for the age of the patient. Scant pyelectasia noted in both kidneys. The left kidney meaursed 5.3 cm. The right kidney measured 5.7 cm.

Adrenal Glands

The bilateral adrenal glands were mildly prominent in size. Non-homogeneous to mildly irregular non-mineralized parenchyma and mild capsule asymmetry was present without suspicion for overt neoplasia. The left adrenal gland measured 0.65 cm at the cranial pole and 0.82 cm at the caudal pole. The right adrenal gland measured 0.73 cm at the cranial pole and 0.67 cm at the caudal pole.

Spleen

The spleen was normal in size and overall contour. Primarily maintained finely textured homogeneous parenchyma. A solitary, well demarcated, hyperechoic nodule was noted in the caudal spleen, exhibiting subtle progressive distal acoustic shadowing, measuring 0.68 cm. Concurrent non-expansive, mildly hypoechoic nodule noted in the mid lateral spleen, measuring 1.1 cm diameter.

Liver

The liver was mildly enlarged with maintained symmetrical capsule contour. Generalized mild non-uniform parenchyma exhibiting moderate coarse echotexture and mild generalized mixed echogenicity. No masses or nodules noted. The gallbladder was non-distended in size with thin walls and primarily anechoic luminal content. Moderate non-dependent, mildly organized to congealed luminal debris present including hypoechoic areas noted between the non-dependent debris and inner luminal walls, suggestive of mucus. No evidence of inflammatory criteria. The cystic and common bile ducts were normal.

Gastrointestinal

The stomach presented intact wall layering with a normal wall layer ratio. The lumen of the stomach was empty with no signs of ileus, obstruction or foreign material.

The small intestine presented intact wall layering with 1:3 muscularis/mucosa ratio. The lumen of the small intestine was empty with no signs of ileus, obstruction or foreign material.

Normal visible colon wall layers were present with apparent formed feces in lumen.

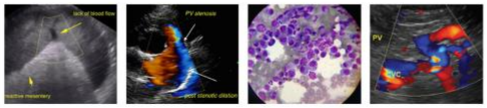

PATIENT

Dexter Sullivan

SPECIES

Canine

BREED

Boston Terrier

SEX

Neutered Male

AGE

12 Years

WEIGHT

30 Pounds

INTERPRETED BY

R. McKenzie Daniel, DVM, DABVP (Canine and Feline)

IMAGING PERFORMED BY

Pamela Harrigan, RDCS

HOSPITAL NAME

Chase Vet Clinic

REFERRING VET

Dr. Halli Lipinski

INVOICE

37560

DATE

5/10/22

Pancreas

The parenchyma of the left limb, body and right limb of the pancreas presented isoechoic to the adjacent omental fat. A normal curvilinear capsule contour of the pancreas was present. The visible pancreatic duct was normal. No signs of active inflammation or neoplastic disease was evident.

Free Abdomen

No overt lymphadenopathy or peritoneal effusion was present.

ULTRASONOGRAPHIC FINDINGS

- Hepatopathy exhibiting mild generalized non-uniform parenchyma
- Moderate congealed to non-dependent gallbladder debris and suspect mucus – possible early gallbladder mucocele.
- Mildly prominent to irregular bilateral adrenal glands
- Age related kidneys with scant pyelectasia
- Intermittent, variably echogenic splenic nodules – subjectively benign.

INTERPRETATION OF THE FINDINGS & FURTHER RECOMMENDATIONS

Overall, the appearance of the liver was non-specific, yet consistent with benign hepatopathy. Considerations may include metabolic, reactive or vacuolar hepatopathy, inflammatory/immune mediated disease, or other hepatopathy, with occult neoplasia considered less likely.

The bilateral adrenal glands were non-specific with considerations including adenomatous change, mild hyperplasia, with emerging neoplastic criteria thought less likely. Full adrenal workup could be considered if clinical signs suggestive of adrenal hyperfunctionality are present.

The splenic nodules, although non-specific, are likely consistent with hyperechoic benign myelolipomas, emerging splenic mineralization, fibrosis, previous infarct, while the hypoechoic nodule is suggestive of lymphoid hyperplasia, hematopoiesis, or potential focal splenitis. Sonographic monitoring of these nodules would be reasonable for evidence of progression.

Ultrasound guided FNA of the spleen, assuming normal clotting status and using 25-gauge needle, is warranted for screening cytology, primarily to assess for evidence of inflammatory cells, given the ALT elevation. Leptospirosis titers/PCR could be considered if clinically indicated. Hepatosupportive medications including Denamarin and Ursodiol may prove beneficial. Hepatic core surgical biopsy may be required for definitive diagnosis. Hepatic functionality is likely normal without overt anesthetic contraindications, assuming normal albumin, glucose, BUN, and cholesterol levels.

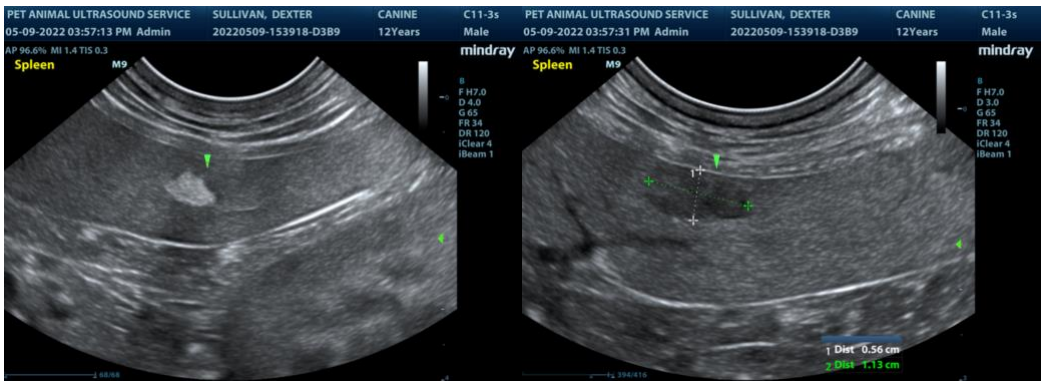

PAUS
Pet Animal Ultrasound Service
4paus.com 781-635-5677

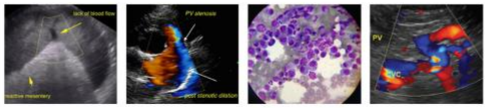

SonoPath
Clinical Sonography & Telecytology
EDUCATIONAL TELECONSULTATION SERVICES™
1-800-838-4268 info@sonopath.com SonoPath.com

PATIENT

Dexter Sullivan

SPECIES

Canine

BREED

Boston Terrier

SEX

Neutered Male

AGE

12 Years

WEIGHT

30 Pounds

INTERPRETED BY

R. McKenzie Daniel, DVM, DABVP (Canine and Feline)

IMAGING PERFORMED BY

Pamela Harrigan, RDCS

HOSPITAL NAME

Chase Vet Clinic

REFERRING VET

Dr. Halli Lipinski

INVOICE

37560

DATE

5/10/22

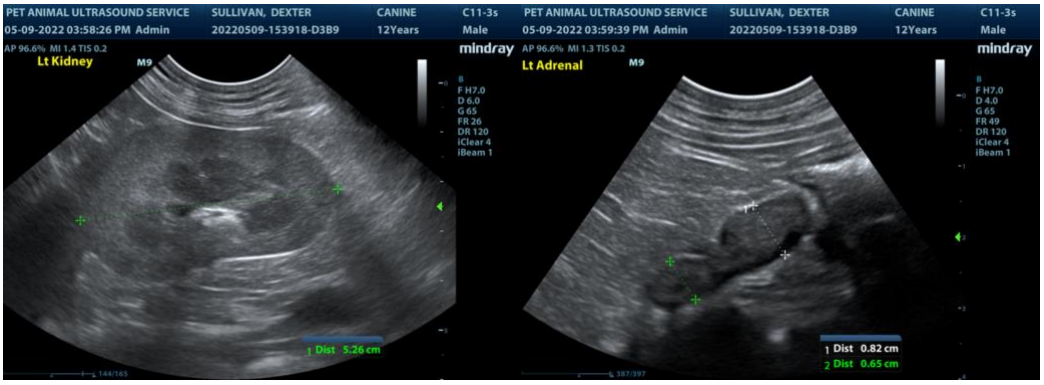

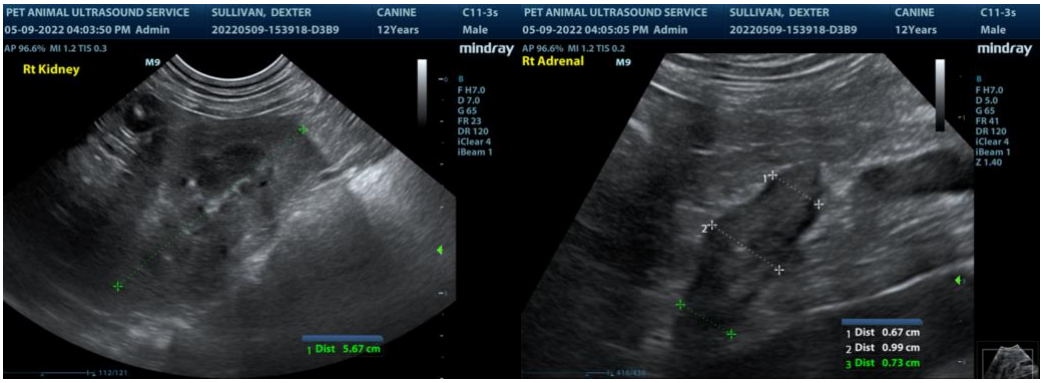

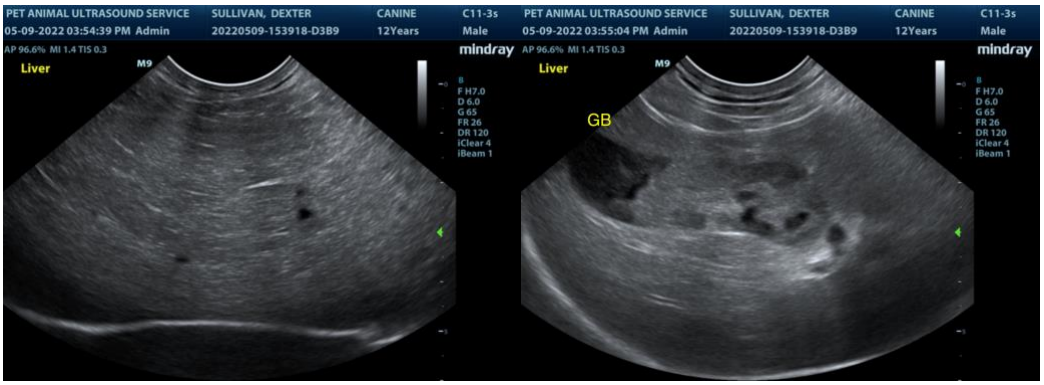

The information and recommendations provided are based on the images presented by the referring veterinarian. No evaluation can be communicated regarding pathology that was not visible in the image/video clips provided.

Thank you for this referral. If the clinical or image interpretation does not parallel your findings or if I can be of any further assistance please contact me.

R. McKenzie Daniel, DVM, DABVP (Canine / Feline Practice)
info@SonoPath.com