



PATIENT

Otter O'Brien

SPECIES

Canine

BREED

Dachshund

SEX

MN

AGE

8 yo

WEIGHT

15.5 lbs.

INTERPRETED BY

R. McKenzie Daniel,
DVM, DABVP
(Canine and Feline)

IMAGING PERFORMED BY

Shannon Matthies,
DVM

HOSPITAL NAME

Saugerties AH

REFERRING VET

Andrew Lang, DVM

INVOICE

10869

DATE

5/6/26

PRESENTING CLINICAL SIGNS

Intermittent bilious Vomiting

ULTRASONOGRAPHIC EXAMINATION OF THE ABDOMEN

Urinary System

The urinary bladder, trigone, and cystourethral junction exhibited normal thickness and tone. Anechoic urine was present in the lumen with no uroliths or sediment. The ureteral papillae were normal. The ureters were not visible which is normal. No evidence of inflammatory or neoplastic changes were noted.

The area of the residual prostate appeared normal and free of pathology

No evidence of pathology in the area of the aortic trifurcation.

Normal size and margination were present in the kidneys. A normal 1:3 cortex / medulla ratio and normal corticomedullary definition were maintained. The echogenicity of the cortex was similar to or slightly less than normal liver parenchyma while the medulla echogenicity was hypoechoic to the cortex with no evidence of pelvic dilation. The left kidney measured 3.8 cm in length. The right kidney measured 4.0 cm in length.

Adrenal Glands

The left adrenal gland was uniform in size and contour with a uniformly hypoechoic parenchyma. The left adrenal gland measured 0.53 cm width at the caudal pole. The right adrenal gland was uniform in size and contour with a uniformly hypoechoic parenchyma. The right adrenal gland subjectively measured 0.50 cm width at the caudal pole.

Spleen

The spleen exhibited a finely textured and homogenous parenchyma which was hyperechoic to the liver and renal cortical parenchyma. The capsule was smooth and regular without apparent expansion. The splenic vasculature at the hilus was normal in volume with no evidence of congestion or thrombosis. Acute to chronic inflammatory, neoplastic, or benign parenchyma changes were not noted.

Liver/ Gallbladder

The liver was subjectively normal in size, structure, and contour. Normal hepatic vascular volume was present. The liver parenchyma was uniform and hypoechoic to the spleen with a mild coarse echotexture. The hepatic and portal vasculature were normal in appearance without signs of congestion. The gallbladder was non-distended in size with thin walls and primarily anechoic luminal content. The cystic and common bile ducts were normal.

Gastrointestinal

The stomach presented intact wall layering with a normal wall layer ratio. The lumen of the stomach was empty without evidence of retained ingesta, fluid, or foreign material. The gastric body wall measured 0.28 cm width. The pylorus wall width measured 0.30 cm in width. There is no evidence of pathology in the area of the gastroesophageal junction.



PATIENT

Otter O'Brien

SPECIES

Canine

BREED

Dachshund

SEX

MN

AGE

8 yo

WEIGHT

15.5 lbs.

INTERPRETED BY

R. McKenzie Daniel,
DVM, DABVP
(Canine and Feline)

IMAGING PERFORMED BY

Shannon Matthies,
DVM

HOSPITAL NAME

Saugerties AH

REFERRING VET

Andrew Lang, DVM

INVOICE

10869

DATE

5/6/26

The small intestine presented intact wall layering with 1:3 muscularis/mucosa ratio. The lumen of the small intestine was empty with no signs of ileus, obstruction, or foreign material.

Normal visible colon wall layers were present with formed feces in lumen.

Pancreas

The parenchyma of the left limb, body and right limb of the pancreas presented isoechoic to the adjacent omental fat. A normal curvilinear capsule contour of the pancreas was present. The visible pancreatic duct was normal. No signs of active inflammation or neoplastic disease was evident.

Free Abdomen

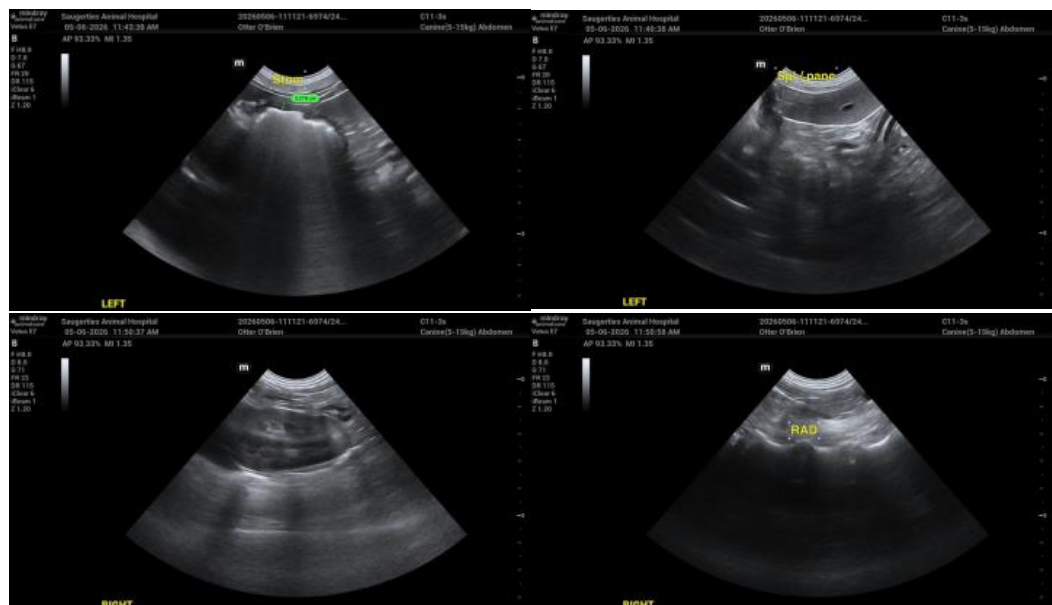
No overt lymphadenopathy or peritoneal effusion was present.

ULTRASONOGRAPHIC FINDINGS

- Sonographically normal gastrointestinal tract
- Normal area of pancreas

INTERPRETATION OF THE FINDINGS & FURTHER RECOMMENDATIONS

There is no evidence of visceral, specifically gastrointestinal or pancreatic, pathology. Smaller, more frequent feedings of a bland or potential novel protein diet with as-needed gastroprotectants and clinical monitoring is suggested. Although considered less likely, screening cortisol level to assess for or rule out occult Addison's Disease may be considered. Recheck sonogram if progressive gastrointestinal signs are noted.





PATIENT

Otter O'Brien

SPECIES

Canine

BREED

Dachshund

SEX

MN

AGE

8 yo

WEIGHT

15.5 lbs.

INTERPRETED BY

R. McKenzie Daniel,
DVM, DABVP
(Canine and Feline)

IMAGING PERFORMED BY

Shannon Matthies,
DVM

HOSPITAL NAME

Saugerties AH

REFERRING VET

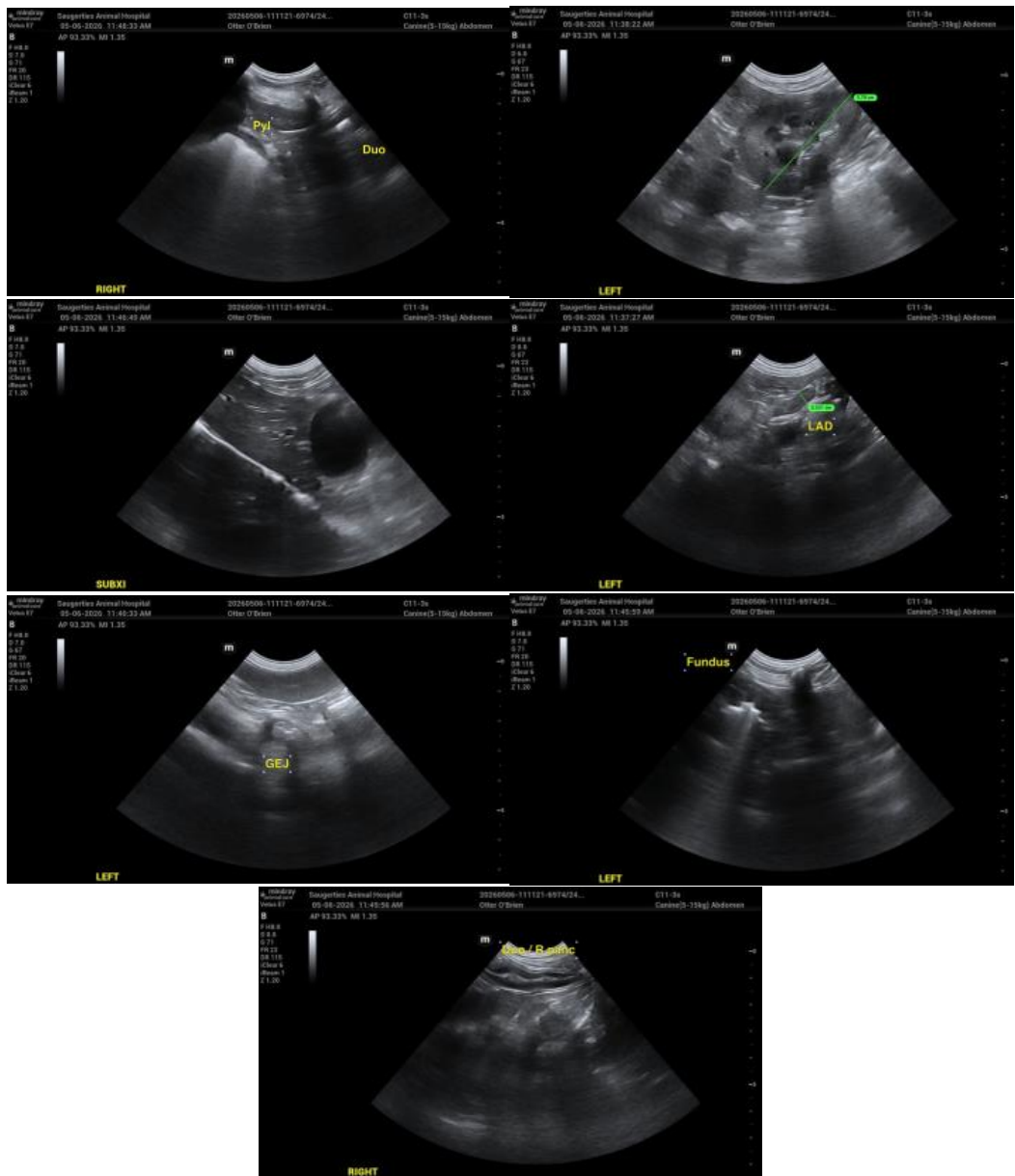
Andrew Lang, DVM

INVOICE

10869

DATE

5/6/26



The information and recommendations provided are based on the images presented by the referring veterinarian/sonographer. No evaluation can be communicated regarding pathology that was not visible in the image/video clips provided.

Thank you for this referral. If the clinical or image interpretation does not parallel your findings or if I can be of any further assistance, please contact me.

R. McKenzie Daniel, DVM, DABVP (Canine/Feline Practice)

info@sonopath.com